

## NEOSTIGMINE: AN UNUSUAL CAUSE OF POST-OPERATIVE NON-CARDIOGENIC PULMONARY OEDEMA

Lalit Gupta<sup>1,\*</sup>, Gaurav Dwivedi<sup>2</sup>, Poonam Bhadoria<sup>3</sup>

<sup>1</sup>Consultant, <sup>2</sup>Senior Consultant, Anaesthesia, HCG- SMH Cancer Curie Centre, New Delhi, India

<sup>3</sup>Director Professor, Anaesthesia, Maulana Azad Medical College & Associated hospitals, New Delhi, India

**\*Corresponding Author:**

Email: lalit.doc@gmail.com

### ABSTRACT

*Non cardiogenic pulmonary oedema (NCPE) continues to represent an important cause of morbidity and mortality with a large human and financial cost. Because of the resemblance of the clinical picture to that seen with respiratory distress of the neonate, NCPE has been referred to as the Adult Respiratory Distress Syndrome (ARDS). In spite of the great improvement in supportive therapy, mortality continues to exceed 50%. The diagnosis of drug-related NCPE relies upon documented exclusion of other causes of NCPE like gastric aspiration, sepsis, trauma, negative pressure pulmonary oedema, etc. We describe cases of 55-year old male who underwent an elective surgery under general anaesthesia and developed NCPE after administration of 'neostigmine-glycopyrrolate' used to reverse residual neuromuscular blockade. The patient was treated successfully with mechanical ventilatory support, and adjuvant therapy. This report emphasizes that this fatal complication may be seen with neostigmine, the pathogenic mechanism remains unknown, and it probably is a drug-related NCPE.*

### Keywords:

**Medical Terms:** Non-cardiogenic pulmonary oedema, Drug-related NCPE, Neostigmine, Reversal

### INTRODUCTION

Non-cardiogenic pulmonary oedema (NCPE) is a clinical syndrome characterized by simultaneous presence of severe hypoxemia, bilateral alveolar infiltrates on chest radiograph, and no evidence of left atrial hypertension/congestive heart failure/fluid overload. Pulmonary oedema after general anaesthesia, a rare complication has been earlier reported in literature that can be cardiogenic, non-cardiogenic (NCPE) [1,2] or negative pressure pulmonary oedema (NPPE) [3,4,5]. Gastric aspiration, sepsis and trauma are well recognized causes of NCPE [2]. Less appreciated is the fact that various drugs, either taken as standard therapy or as an overdose, may precipitate NCPE [6]. Little is known about the mechanisms involved in drug related NCPE. The incidence of NCPE has been reported to be 0.05%–0.1% of all anesthetic practices; however, it is suggested that it occurs more commonly than is generally documented [3].

In this report, we describe a case of NCPE after administration of neostigmine and glycopyrrolate combination used for reversing the residual neuromuscular blockade. Possible causes, therapeutic approach and a brief review of literature have been discussed.

### CASE REPORT

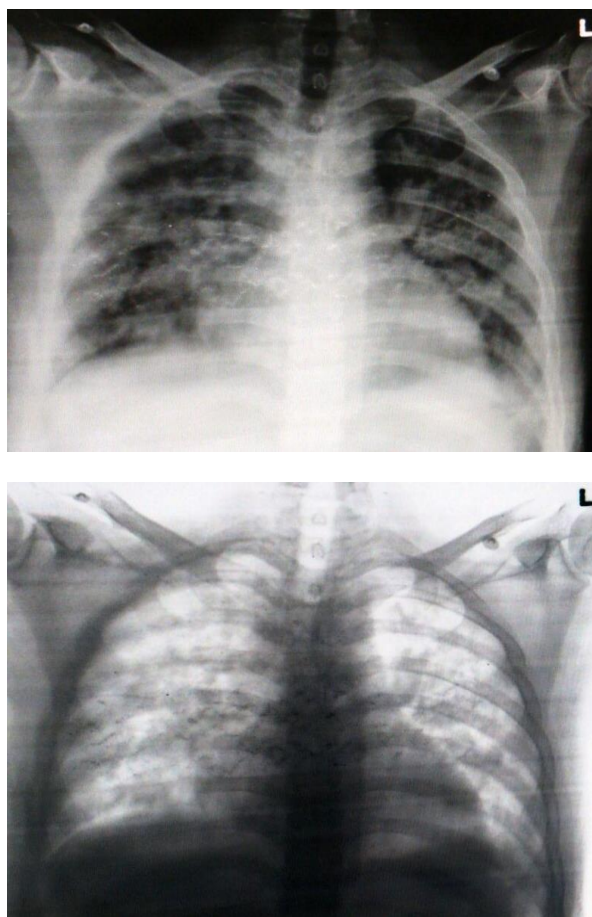
A 55-year old male with unremarkable preanaesthesia examination, was taken for laproscopic cholecystectomy electively after overnight fasting. He was premedicated with midazolam (2 mg), glycopyrrolate (0.2 mg), ondansetron (4 mg), fentanyl (100 µg), and

induced with propofol (100 mg), suxamethonium (100 mg) followed by intubation with 8.5 mm cuffed ETT and Maintenance of anaesthesia was on N<sub>2</sub>O:O<sub>2</sub> (50:50), isoflurane (≤ 1%) and atracurium. Intraoperative monitoring included NIBP, SpO<sub>2</sub>, ECG which remained in normal range during the surgery that lasted for 1 hour and 1,500 ml Ringer Lactate was given. At the end of the surgery, his neuromuscular block was reversed with neostigmine 2.5 mg and glycopyrrolate 0.4 mg IV. His trachea was extubated after complete recovery and he was shifted to recovery room for observation. In recovery room, we immediately noticed tachycardia (PR-116/min), tachypnoea (RR-34/min), mild to moderate cyanosis and air hunger in the patient. His BP was 76/40 mmHg and SpO<sub>2</sub> 84 %. Chest auscultation showed bilateral crepitation.

Immediate re-intubation with midazolam and suxamethonium and ventilation with 100 % oxygen supplementation was carried out. Inj deriphyllin (2 ml) IV given along with Inj dexamethasone (8mg) and hydrocortisone (100mg), Inj dopamine@ 5-10 µg/kg/min was started with aim to keep SBP above 100 mmHg and when BP became normal (102/66 mmHg), Inj lasix 20 mg given IV. In endotracheal suctioning copious pink frothy secretions were coming out continuously with SpO<sub>2</sub> decreasing to 50-60%. He was re-paralyzed with atracurium and shifted to surgical ICU for ventilatory support (on CMV mode with TV 400 ml, f 15/min and PEEP 7cm of H<sub>2</sub>O on 100% O<sub>2</sub>). In ICU, chest X-ray showed bilateral diffused infiltrate suggestive of pulmonary oedema [Figure 1, 2]. ABG showed pH 7.20, PO<sub>2</sub> 70 mmHg, PCO<sub>2</sub> 55 mmHg, HCO<sub>3</sub> 21, BE -

3, SpO<sub>2</sub>= 94%, suggestive of ARDS. All blood investigations came in normal range. ECG was recorded, cardiologist reference was done and it was diagnosed as non-cardiogenic ARDS. He was electively ventilated overnight with atracurim and midazolam.

Dopamine was weaned during night and next day morning atracurium and midazolam were stopped and he was taken on SIMV mode with TV 450, f 13, PEEP 5. Patient was weaned off from the ventilator gradually over 4 hours and extubated. Repeat ABG and CXR were normal. Patient was discharged after 2 days uneventfully.



**Figure 1, 2:** X-ray chest PA view showing pulmonary oedema

## DISCUSSION

Pulmonary oedema can reflect either an increase in the net hydrostatic pressure across the pulmonary capillaries called hydrostatic pulmonary oedema that can be cardiogenic or due to fluid overload or an increase in the permeability of the alveolar-capillary membrane called permeability pulmonary oedema (non-cardiogenic pulmonary oedema, NCPE/ARDS) [1,2].

Many conditions are associated with pulmonary edema that appears to be due to diffuse

damage and increased permeability of alveolar-capillary membrane. These conditions include infectious (bacterial, viral, parasitic) septicemia, trauma and disseminated intravascular coagulation. Drug induced pulmonary edema [6,7,8,9] has also been documented with several agents that have different pharmacological effects. To mention few are Salicylates, Naloxone, Tocolytics, Protamine, Amiodarone, Insulins, Streptokinase, Ondansetron, Hydrochlorothiazide etc. Burn, aspiration of gastric contents, inhalation of foreign body, acute radiation pneumonitis and drowning has been also implicated in the development of pulmonary edema.

In our case fluid overload was absent and cardiogenic pulmonary oedema has been ruled out because of absence of preexisting heart disease, absolutely normal ECG throughout that was supported by cardiologist's opinion as NCPE. NCPE is usually high flow state (warm periphery), with bounding pulses, no gallop, no jugular venous distention and with dry crackles.

In this case aspiration has been ruled out and there was no history of sepsis or any another type of infection before surgery. According to "two hit hypotheses" (*A severe insult in the form of infection or trauma primes the host immune system so that a subsequent, relatively trivial insult produces a markedly exaggerated host immune response*)[10] and further stated by Ohmi S et al.[11] in their case report, that the bacterial infection preceding the operation may prime the immune cells and the following surgical stress may then trigger sudden massive pulmonary capillary leak leading to ARDS during elective surgery even though the patient's condition is well controlled.

Negative pressure pulmonary oedema (NPPE) also a form of NCPE, an uncommon problem developed by the occurrence of persistent inspiratory efforts against an obstructed upper airway, creating a markedly negative intra-pleural pressure [12] was ruled out as patient became fully conscious after giving reversal and having good exhaled tidal volume.

According to literature, neostigmine overdose may cause acute cholinergic crisis characterized by increased salivation, bronchial secretions, bronchospasm, tachycardia or bradycardia and hypotension [13]. Extreme high doses may produce CNS symptoms of agitation, fear or restlessness and death may result from cardiac arrest or respiratory paralysis and pulmonary oedema [13]. In our cases dose used was 0.05 mg/kg ruling out above mechanism of lung injury.

The diagnosis of non-cardiogenic pulmonary edema is done by exclusion, as no specific test is available. In our patients the incidence occurred just after reversal of residual neuromuscular block with neostigmine and glycopyrrolate. Of these,

glycopyrrolate was used at induction hence the most probable agent should be neostigmine.

In a recent study on rats, it is reported that neostigmine given in the absence of neuromuscular (NM) block or when given after recovery from NM block, it evokes a partial upper airway obstruction by decreasing skeletal upper airway dilator muscle activity which may generate NPPE. However, human studies will be required to evaluate the clinical relevance of above findings [14].

Diagnosing drug induced NCPE is actually an exercise of exclusion, as there is no diagnostic test available. It is related to the time proximity of administration of drugs and pathogenesis involves both a direct cytotoxic insult to the lung epithelial cells and induction of cytokine triggered inflammatory response. NCPE can be reversed upon prompt recognition, following immediate discontinuation of the offensive drug and start of intensive supportive treatment although fatalities have been reported.

The important aims in the management of NCPE are to maintain oxygenation, ventilation and reducing preload. Initially 100 % oxygen can be given by a facemask. [15]. If the PO<sub>2</sub> cannot be maintained at 60 mmHg or if there is progressive hypercapnia the patient should be intubated and mechanically ventilated. Application of PEEP of 5-20 cm of H<sub>2</sub>O is beneficial in these patients as it can decrease the preload and after load thereby improving cardiac function. This also results in redistribution of the fluid in the lungs from the intra alveolar to the extra spaces where it does not interfere significantly in gas exchange and also prevents atelectasis [15]. Reduction of preload can also be done by the loop diuretic frusemide as it is venodilator and can reduce the preload rapidly.

## CONCLUSION

We witnessed an unprecedented post anesthetic pulmonary oedema after neostigmine administration at the end of general anaesthesia which was successfully treated with mechanical ventilation, diuretics, inotropes and steroids. Monitor all the patients in the recovery room at least for 45-60 min after reversal. Do not hesitate to re-intubate and paralyze the patient if there is respiratory inadequacy. The aim of this case report is to alert anesthesiologists, that besides known factors for the development of cardiogenic pulmonary edema, there are other significant mechanisms that cause NCPE.

**Consent:** Written informed consent was obtained from the patient for publication of this case report and accompanying images.

**Conflict of Interests:** The authors declare that they have no conflict of interests related to this manuscript.

**Authors' Contributions:** Dr. Lalit Gupta was the main anaesthetist on the case and took the X-ray pictures. Dr. Gaurav Dwivedi and Dr. Lalit Gupta reviewed the literature and wrote the manuscript. Dr. Poonam Bhadoria guided at every step and helped in final compilation of case report.

## References

1. Roland H, Ingram J, Braunwald E: Pulmonary edema: Cardiogenic and noncardiogenic. Pp.551-566, Volume 1. In Heart Diseases by Braunwald, W.B. Saunders Co, Philadelphia,1992.
2. Khan A, Irior KL, Ramsunder K. Chest and TB non-cardiogenic pulmonary edema, E-medicine specialties. Radiology. Available from: <http://www.emedicine.medscape.com/article/360932> [last updated on 2008 May 7].
3. McConkey PP. Postobstructive pulmonary oedema: A case series and review. *Anaesthesia Intensive care*. 2000 Feb; 28(1):72-6.
4. Timby J, Reed C, Zeilender S, Glauser FL. "Mechanical" causes of pulmonary edema. *Chest Care* 1990;98:973-9.
5. Goli AK, Goli SA, Byrd, Roy TM. Spontaneous negative pressured changes: An unusual cause of non-cardiogenic pulmonary edema. *J Ky Med Assoc*. 2003;101:317-20. [PubMed: 14502951].
6. Reed CR, Glauser FL. Drug-induced non-cardiogenic pulmonary edema. *Chest*. 1991;100:1120-4.
7. Gamboa PM, Achotegui V, Irigoyen J, Perez-Asenjo J, Merino J, Sanz ML. Hydrochlorothiazide-induced acute non-cardiogenic pulmonary edema. *J Investig Allergol Clin Immunol*. 2005;15:299-301.
8. Gupta A, Verma K. Ondansetron: An acute fulminant pulmonary edema. *Ind J Anaesthesiology*. 2009;53:240-1.
9. Briasoulis E, Pavlidis N. Non-cardiogenic pulmonary edema: An unusual and serious complication of anti-cancer therapy. *Oncologist*. 2001;6:153-61.
10. Butt I Shrestha BM. Two-hit hypothesis and multiple organ dysfunction syndrome. *JNMA J Nepal Med Assoc*. 2008 Apr-Jun;47(170):82-5.
11. Ohmi S, Takei T, Habuka K, Watanabe Y. Acute pulmonary capillary leak syndrome during elective surgery under general anesthesia. *J Anesth*. 2008;22:77-80.
12. Sharma S, Samplay M, Varshnay S. Pulmonary edema after thyroidectomy. Case report and review. *Internet J Anesthesiol*. 2008;18:ISSN:1092-406X.
13. <http://www.drugs.com/sfx/neostigmine-side-effects.html>
14. Eikermann M, Zarembo S, Malhotra A, Jordan AS, Rosow C, Chamberlin NL. Neostigmine but not sugamadex impairs upper airway dilator muscle activity and breathing. *Br J Anaesth*. 2008;101:344-9.
15. Hochman JS, Ingbar D. Cardiogenic shock and pulmonary oedema. In: Dan L Longo, Anthony S Fauci, Dennis L kasper, Stephen L Hauser, J Larry Jameson, Joseph Loscalzo, editors. *Harrison's Principles of Internal Medicine*. 18th ed. USA: McGrawHill; 2012.p.2232-2236.