

Role of nitroglycerine as tocolytic agent during double valve replacement surgery in pregnant patient with successful fetal outcome

Hariom Khandelwal¹, Kunal Singh^{2,*}, Shikha Agarwal³, Ashutosh Singh⁴

¹Senior Resident, ^{2,4}Assistant Professor, Dept. of Anaesthesiology & Intensive Care, ³Senior Resident, Dept. of Obstetrics & Gynecology, Shri Guru Ram Rai Institute of Medical & Health Sciences,

***Corresponding Author:**

Email: drkunalsingh@outlook.com

Abstract

Cardiovascular disease is an important non-obstetric cause of maternal and fetal morbidity and mortality during pregnancy. Cardiac surgery during pregnancy is usually well tolerated by mother but the fetal outcome is variable. Here we have described the use of nitroglycerine as a tocolytic in a patient who underwent double valve replacement in the second trimester of pregnancy with successful fetal outcome.

Keywords: Nitroglycerine, Tocolytic agent, Double valve replacement surgery, Pregnancy.

Received: 27th October, 2016

Accepted: 14th February, 2017

Introduction

The incidence of heart disease in pregnant women varies from 1 to 4% and the most common cause is rheumatic mitral disease.⁽¹⁾ Open-heart surgery during pregnancy is usually well tolerated by the mother but the fetal outcome is variable and fetal mortality is high.⁽²⁾ Different tocolytic agents have been described to avert premature threatened abortion. Each tocolytic has a unique mechanism of action, side effects and degree of complexity to administer.⁽³⁾ We wish to share our experience of use of nitroglycerine as a tocolytic in a patient who underwent successful open-heart surgery for double valve replacement in the second trimester of pregnancy.

Case Report

A 25-year-old woman gravida III para II had history of dyspnea on exertion & palpitation from 1 year. She also complained orthopnea from 3 months with New York Heart Association (NYHA) functional class III. On her complete medical evaluation, she was found to have a 16 weeks pregnancy which she was unaware of due to irregular menstruation cycle from last few months. Obstetrical examination revealed positive foetal viability. Echocardiography findings revealed severe mitral stenosis with mitral valve area-0.9 cm², severe aortic regurgitation grade-3+, large left atrium 56 mm, moderate tricuspid regurgitation and ejection fraction 65%. Electrocardiogram (ECG) showed sinus rhythm with a heart rate of 86 beats/min. The patient was advised oral digoxin 0.25 mg/day, enalapril 2.5 mg twice a day, furosemide 40 mg/day. After proper counselling to patient about the risk cardiac failure to mother and high changes of premature labour a written informed consent was taken for combined aortic and mitral valve replacement surgery.

Night before surgery patient received oral medication with tablet lorazepam 2 mg and ranitidine 150 mg. Patient shifted to operation room with oxygen inhalation by facemask. We started monitoring by two lead ECG II, V and pulse oximetry. We did percutaneous puncture and cannulations of the left radial artery and right jugular vein under local anaesthesia to start arterial blood pressure monitoring and continuous cardiac output monitoring. Base line hemodynamic parameters were recorded as heart rate 88/min, intra-artery pressure 122/38 mmHg, pulmonary artery pressure 82/32 mmHg, pulmonary artery wedge pressure 32 mmHg, cardiac output 1.8 l/min, pulmonary vascular resistance 533 dynes/s.cm⁵/m² and systemic vascular resistance 2400 dynes/s.cm⁵/m² (Fig. 1). Rapid sequence induction was done with fentanyl 10 µg/kg, etomidate 0.2 mg/kg, rocuronium 1.2 mg/kg and intubated her trachea using 7.5 mm endotracheal tube to facilitate positive pressure ventilation. Additionally FHR was also recorded with the cardiocardiograph (CTG). Nitroglycerin (NTG) infusion 0.5 mcg/kg/min was started immediately after induction to prevent early premature uterine contractions. Anaesthesia was maintained with isoflurane, propofol infusion and intermittent doses of fentanyl and vecuronium. Mean arterial pressure (MAP) was maintained between 60-70mmHg during cardio-pulmonary bypass (CPB) with a pump flow of 2.5 liters/min. Aortic and mitral valve replacement was done using CPB with non pulsatile blood flow using membrane oxygenator and blood cardioplegia. The total CPB time and aortic cross clamp time was 104 min and 52 min respectively. After completion of surgery patient was weaned off the CPB with the help of titrated doses of adrenaline 0.03 to 0.05 µg/kg/min and nor-adrenaline 0.05 to 0.08 µg/kg/min infusions to keep MAP between 60-70 mmHg. After surgery the obstetrician performed the foetal

examination for viability, there was obvious fetal heart sound which was confirmed by CTG. The patient was shifted to cardiac intensive care unit and NTG infusion was replaced by NTG patch above umbilicus at the level of fundus. Extubation was done on the next day of surgery. Patient was shifted to the ward on the 3rd

postoperative day after evaluation of fetal well being and discharged after 7 days with intact pregnancy. Patient underwent caesarian section under general anaesthesia at 35th week of her pregnancy gave birth to a healthy child.

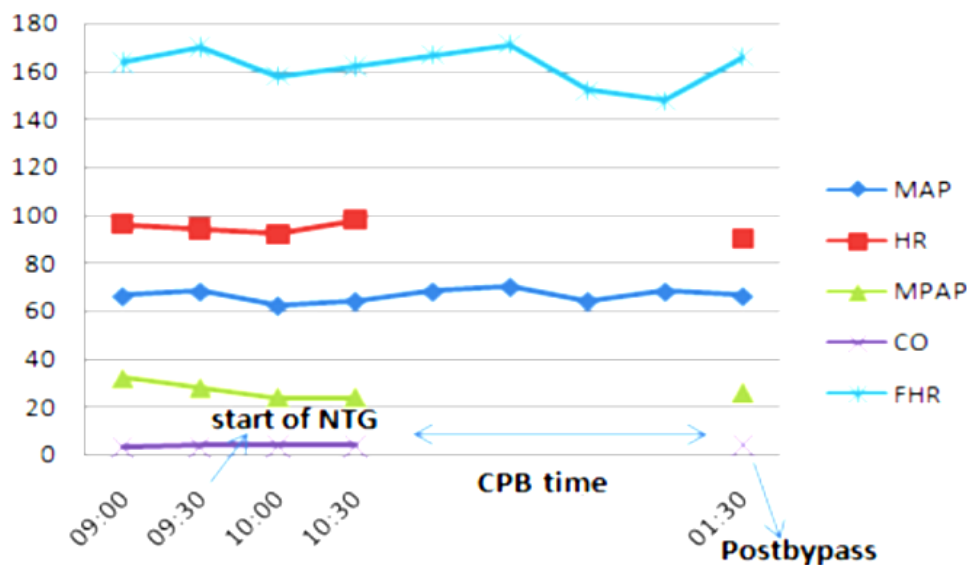


Fig. 1: Hemodynamic parameters during surgery

Discussion

In this case report, double valve replacement was electively performed in second trimester of the pregnancy because of high-risk pregnancy to carry till full-term and the patient was in the New York Heart Association (NYHA) functional class III with severe mitral stenosis and Aortic regurgitation (grade- 3+). It was a constant threat to increase of risk for maternal mortality as gestation progressed. Factors like relative hypervolemia, anaemia, increased heart rate maternal and cardiac output can cause cardiocirculatory imbalance and precipitate decompensation in the pregnant women with valvular heart disease.⁽⁴⁾ The second and third trimesters are considered safe for surgery in terms of foetal survival till term.⁽⁵⁾ Several Cochrane reviews have compared individual tocolytic drugs. In the absence of a single high quality, randomized controlled trial comparing all tocolytic therapies, uncertainty remains in selecting correct choice in perioperative period.⁽⁶⁾ Beta-agonists are associated with tachycardia and palpitations, undesirable in patients with cardiac lesions.⁽⁷⁾ There is no intravenous preparation of nifedipine and risk of adverse effects on foetal or placental circulation following nifedipine exposure has also been suggested.⁽⁸⁾ Low dose intravenous infusion of nitroglycerine is reported to show tocolytic effects during intrapartum external cephalic version in obstetrics.⁽⁹⁾ Nitroglycerin infusion is also routinely used during valve surgery for its effects to get uniform

rewarming after CPB, decreased lactic-acidosis, corrected systemic ischemic stress and to facilitate heparin neutralization. It is also shown to improve cerebral oxygen saturation, reduced pulmonary artery pressure and the improved stroke volume and cardiac output during valve surgery.⁽¹⁰⁾ Thus making it a first choice for use in a pregnant patient. Transdermal NTG patches well known and used for the treatment of angina are now found to be safe and effective for the preterm labour.⁽¹¹⁾ We too found the use of NTG patches applied over the abdomen above the level of fundus helped to continue pregnancy in our patient after double valve replacement surgery.

Thus we conclude that the uterine and fetal monitoring during cardiac surgery in pregnant women helps regulating CPB and hemodynamic targets during and after CPB. NTG infusion followed by its patch applied over umbilicus was also found to have good tocolytic effect in our patient and prevented premature abortion and warrants a large trial to confirm.

References

1. Arnoni RT, Arnoni AS, Bonini RC, Almeida AF, Neto CA, Dinkhuysen JJ, et al. Risk factors associated with cardiac surgery during pregnancy. *Ann Thorac Surg* 2003;76:1605-8.
2. Mahli A, Izdes S, Coskun D. Cardiac operations during pregnancy: review of factors influencing fetal outcome. *Ann Thorac Surg* 2000;69:1622-26.
3. Hannah ME. Search for best tocolytic for preterm labour. *Lancet* 2000;356:699-700.

4. Duvekot JJ, Peeters LH. Maternal cardiovascular hemodynamic adaptation to pregnancy. *Obstet Gynecol Surv* 1994;49:S1–S14.
5. Bernal JM, Miralles PJ. Cardiac surgery with cardiopulmonary bypass during pregnancy. *Obstet Gynecol Surg* 1986;41:1-6.
6. Caritis SN. Meta analysis and labor inhibition therapy. *Am J Obstet Gynecol* 2011;204:95-6.
7. Worldwide Atosiban versus Beta-agonists Study Group. Effectiveness and safety of the oxytocin antagonist atosiban versus beta-adrenergic agonists in the treatment of preterm labour. *BJOG* 2001;108:133–42.
8. Harake B, Gilbert RD, Ashwal S, Power GG. Nifedipine: effects on fetal and maternal haemodynamics. *Am J Obstet Gynecol* 1987;157:1003–8.
9. Belfort MA. Intravenous nitroglycerin as a tocolytic agent for intrapartum external cephalic version. *S Afr Med J* 1993;83:656.
10. Ziskind Z, Pohoryles L, Mohr R, Smolinsky A, Quang HT, Ruvolo G, Goor DA. The effect of low-dose intravenous nitroglycerin on pulmonary hypertension immediately after replacement of a stenotic mitral valve. *Circulation* 1985;72:II164-9.
11. Smith GN, Walker MC, Ohlsson A, O'Brien K, Windrim R. Randomized double-blind placebo-controlled trial of transdermal nitroglycerine for preterm labour. *AJOG* 2007;196:37.e1-37e8.