

## Pediatric septic arthritis with pericardial and pleural effusions for emergency drainage - Case Report

Bhavna Kakkar<sup>1,\*</sup>, Nishtha Kachru<sup>2</sup>, Mallika Boishya<sup>3</sup>, Lalit Gupta<sup>4</sup>

<sup>1,3</sup>Senior Resident, <sup>2</sup>Specialist, <sup>4</sup>Assistant Professor, Dept. of Anaesthesia and ICU, MAMC, Lok Nayak Hospital

**\*Corresponding Author:**

Email: bhavna.kakkar@gmail.com

### Abstract

Sepsis is a major cause of morbidity and mortality in pediatric age group, mainly because of hemodynamic compromise and multi-organ dysfunction. Septic patients have impaired tissue perfusion, threatening functions of vital organs and situation becomes more challenging if the child has concomitant pericardial and pleural effusions. Anesthesiologists are involved in preoperative resuscitation with judicious use of fluids, vasopressors and inotropes and timely administration of appropriate intravenous antibiotics. Perioperative management requires careful selection of induction and maintenance anesthesia agents, optimizing intravascular volume status, avoiding any lung injury during mechanical ventilation, monitoring investigations and post-operative management of patients in post-anesthesia care unit (PACU) or intensive care unit (ICU). We report successful management of a five year old boy with sepsis with moderate pericardial and pleural effusions for emergency hip joint aspiration and drainage, to the best of our knowledge there is no previously reported case in literature.

**Keywords:** Sepsis, Pericardial effusion, Anesthesia

**Received:** 30<sup>th</sup> January, 2017

**Accepted:** 17<sup>th</sup> March, 2017

### Case Report

A five year old boy, weighing 23 kg came to orthopedic emergency with severe pain in right hip, high grade fever, cough, and shortness of breath, with history of trauma to hip 14 days back and posted to us for aspiration of septic right hip. On examination he had heart rate of 150/minute, BP 70/34 mmHg, high grade fever 104°F, CVP 8 mmHg, moderate pallor, bilateral reduced air entry overall both lungs, muffled heart sounds, hepatomegaly, although no pedal edema, with localized red tender right hip and normal airway examination. Investigations revealed hemoglobin 8.2 g% TLC 33,000; platelet count 80,000/microliter; urea 46 mg/dl, creatinine 3.1 mg/dl, bilirubin 2.5mg/dl, PT 16.8 seconds INR 1.6. Chest X ray revealed bilateral pleural effusion and cardiomegaly (Fig. 1). ECG suggested sinus tachycardia and non-specific ST-T changes (Fig. 2). Arterial blood gas analysis suggested pH 7.3, pO<sub>2</sub> 71, pCO<sub>2</sub> 28, HCO<sub>3</sub> 18, SO<sub>2</sub> 97%. Echocardiography (done 2 days prior to surgery) was suggestive of moderate pericardial effusion, no valvular lesion, normal LV function and IVC collapsing >50% with respiration. Patient was put on intravenous antibiotics including intravenous (iv) vancomycin, iv ceftriaxone owing to blood culture sensitivity report (methicilin resistant staph aureus). Child came to us to be posted for emergency drainage of hip to remove septic focus.

Case was planned to be done under general anesthesia after taking written high risk consent from parents, with blood arranged, back up of ventilator bed in pediatric ICU in view of child's clinical condition (sepsis, pericardial and pleural effusions). We could not get a fresh echocardiography owing to emergent nature

of surgery, although CVP was 8-10mmHg (central line was already in situ in right internal jugular vein). Spinal anesthesia was relatively contraindicated in view of child's anxiety, sepsis, coagulopathy and thrombocytopenia. Pre-anesthetic medication was started with injection parafalgan (paracetamol) 150 mg in the pre-operative room as child had high grade fever of 102°F. Monitoring included heart rate, electrocardiogram, non-invasive blood pressure, peripheral saturation, end tidal carbon dioxide (EtCO<sub>2</sub>), temperature, central venous pressure and urine output. Child was pre-oxygenated with 100% oxygen (5 L/min) for 3 minutes, induction was done with intravenous (iv) fentanyl 30 microgram and iv propofol was administered in titrated doses (total of 20 mg) and anesthesia was then gradually deepened with sevoflurane (2 to 4% in 50% O<sub>2</sub>). After ensuring adequate depth of anesthesia (loss of eyelash reflex and relaxed jaw), supraglottic proseal LMA size 2.5 was placed. The child developed harsh conducted sounds in bilateral chest soon after induction, along with rise in EtCO<sub>2</sub> (rose till 48 mmHg), although there was no fall in saturation, or change in hemodynamics, seeing the condition, he was relaxed with inj vecuronium bromide 2 mg with low tidal volume (150ml) and RR 28/min (to maintain normocarbia). Intravenous antibiotics and 50 mg hydrocortisone were administered after induction in view of sepsis, pericardial effusion and chest condition. Harsh sounds settled with time, with EtCO<sub>2</sub> in normal range (36-38 mmHg) and child had normal vesicular breath sounds with reduced air entry at bases same as that of pre-operative condition. Caudal epidural block was not given owing to sepsis, thrombocytopenia and coagulopathy.

Arterial line could have been placed to monitor beat to beat monitoring but same was not done owing to non-availability of transducer. Blood loss was around 50 ml and same was replaced with crystalloids, total intravenous fluid ringer lactate given intraoperatively was 300 ml maintaining CVP between 10-12 mmHg and urine output was 75 ml. The child maintained normal vital signs with heart rate between 120-40 beats per

minute, systolic blood pressure 70-75 mm Hg, SpO<sub>2</sub> 100% and EtCO<sub>2</sub> 35– 38 mm Hg and surgery lasted for 45 minutes. Residual effects of neuromuscular blocking agent were antagonized with neostigmine and glycopyrrolate. Child was extubated uneventfully and shifted to pediatric ICU for further management of pericardial and pleural effusion and continued with antibiotic coverage.

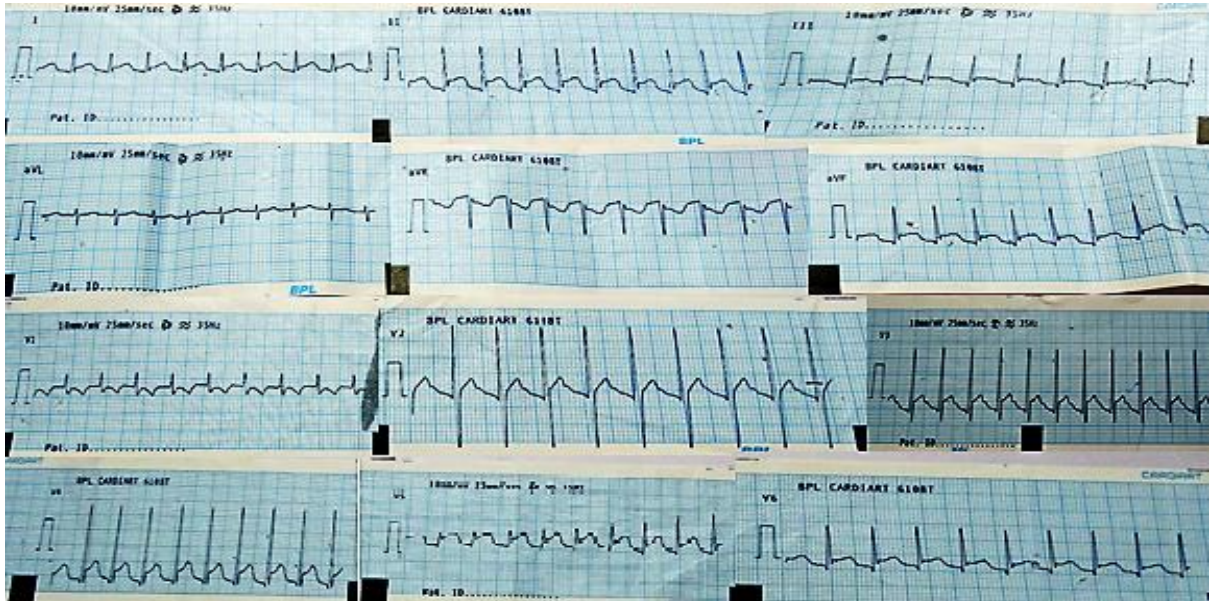


Fig. 1: 12 Lead ECG

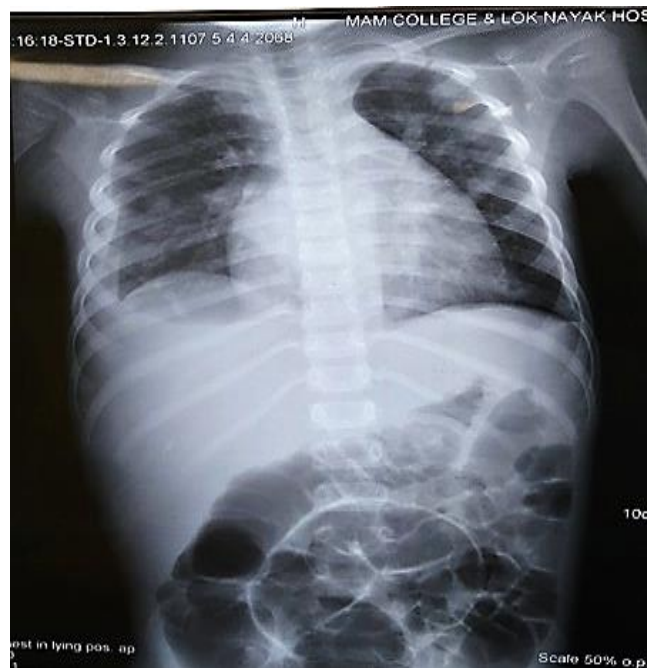

Fig. 2: Chest X ray

### Discussion

Sepsis is life-threatening organ dysfunction caused by a dysregulated host response to infection.<sup>(1)</sup> However, definitions of sepsis, severe sepsis, septic shock and

multiple organ dysfunction/ failure syndromes in children are slightly different when compared to those used for adults. In particular, septic shock in children is defined as presence of sepsis plus signs of cardiovascular

organ dysfunction, not necessarily including hypotension, whilst in adult septic shock hypotension must be present.<sup>(2)</sup> Unlike previous editions, the 2016 iteration of the SSC guidelines does not include recommendations for the care of pediatric patients with sepsis.<sup>(1)</sup> The anesthetic plan in a patient with sepsis, pericardial and pleural effusions require careful considerations, ideally, a thorough and complete preoperative evaluation should be undertaken, although there is limited time for an extensive evaluation as the urgency of the situation often dictates rapid intervention. Symptoms to identify and explore include tachycardia, capillary refill time, central and peripheral pulse, tachypnea, dyspnea, orthopnea, lightheadedness, chest pain, altered mental state and reduced urine output. The extent of preoperative investigations is dependent on the stability of the patient and the urgency of surgery.<sup>(3)</sup> Echocardiogram is essential in making the correct diagnosis of pericardial effusion with or without tamponade, size of effusion can be graded by echocardiography: 1) small (echo-free space in diastole < 10 mm), 2) moderate (10-20 mm), 3) large (>20 mm), or 4) very large (>20 mm and compression of the heart).<sup>(4)</sup> In addition to the use of routine monitors, perioperative invasive arterial blood pressure monitoring is essential. Preparation for anesthetic induction should include the availability of adequate resuscitation fluids (including cross-matched blood) as well as the ready access to vasopressors (e.g., phenylephrine or norepinephrine) and inotropic agents (epinephrine).<sup>(5)</sup> Sedative premedication with any agent can depress respiration should be avoided. The hemodynamic goals for patients requiring general anesthesia are maintenance of preload, afterload, contractility, and heart rate (optimally in sinus rhythm to facilitate ventricular filling).<sup>(6)</sup> Anesthetic drugs generally decrease myocardium contractility, and act directly on the heart and vasculature inducing vasodilation. We used sevoflurane in our case which offers many advantages, particularly as it is less pungent than isoflurane/desflurane and also provides titratable control over hemodynamics which was quite appropriate in our case. All induction agents have a dose-dependent depression of cardiac work and may worsen the condition of such patients, thus, maintaining hemodynamic stability during anesthetic induction is important, as well as choosing an ideal anesthetic.<sup>(5-6)</sup> We used opioid fentanyl based induction with titrated dosage of propofol in our case because opioids provide a good cardiovascular stability and also provides adequate analgesia and least myocardial depressant effect. Ketamine has been recommended for anesthesia and sedation of septic or severely ill patients because of its cardiovascular stimulation properties, but we did not use it in our case owing to his already increased heart rate.<sup>(5)</sup> Etomidate is a rapid intravenous induction agent and carries a predictable onset and recovery, is hemodynamically stable, contains a favorable safety profile but the

potential for adrenocortical suppression is an important consideration, 60% patients in septic patients had adrenocortical suppression even in a single bolus dose as confirmed by CORTICUS study.<sup>(5,6)</sup> We chose supraglottic Proseal laryngeal mask airway (PLMA) to prevent hemodynamic response to intubation.<sup>(7)</sup> Our patient was anemic and it is important to ensure adequate oxygen delivery to the tissues and vital organs and we had asked our surgeons to arrange adequate blood products for the same and for the same reason we kept O<sub>2</sub>: N<sub>2</sub>O ratio to be 50:50. Positive pressure ventilation should be avoided as much as possible in pericardial effusion, and if and when required, should be instituted cautiously with the minimal inspiration pressure required to provide adequate minute ventilation.<sup>(5-6)</sup> In our patient we therefore initially had kept the child on spontaneous mode of ventilation but same was changed to lung protective ventilation (keeping low inspiratory pressure and low tidal volume breaths) owing to development of harsh sounds immediately post placement of LMA, the combination of positive pressure ventilation also decreases venous return as well as vasodilation and direct myocardial depression from the anesthetic agents themselves can result in significant hemodynamic deterioration. Volume infusion, however, is useful for patients with hypovolemia.<sup>(8)</sup> A single fluid challenge is likely to be beneficial especially in the setting of hypotension and moreover our patient was in sepsis and had high grade fever. Decisions regarding extubation at the conclusion of the procedure should depend on the patient's cardiovascular and respiratory status. Similarly, the need for continued intensive postoperative monitoring is dependent on the overall status of the patient. Patients may require a variable period of continuous monitoring in a post-anesthesia care unit or an intensive care unit setting.

## Conclusion

Sepsis is a major healthcare burden, with a persistently high morbidity and mortality especially in pediatric age group. Patients with sepsis often require emergent surgery for elimination of source of infection. Preoperative resuscitation in a child with sepsis and pericardial and pleural effusion is based on hemodynamic monitoring, judicious use of fluids, vasopressors, inotropes and early administration of effective antimicrobial therapy. Intraoperative management requires careful induction using lowest effective doses of a range of induction agents to maintain hemodynamic stability, maintenance by providing optimal volume status, avoiding lung injury during mechanical ventilation, monitoring arterial blood gases, electrolyte levels, and urine output. Postoperative care overlaps with ongoing management of the sepsis syndrome patient in the ICU or PACU.

**References**

1. Rhodes A, Evans L, Alhazzani W, et al. Surviving Sepsis Campaign: international guidelines for the management of sepsis and septic shock, 2016. *Intensive Care Med.* 2017;43(3):304-377.
2. Dellinger RP, Levy MM, Rhodes A, et al. Surviving Sepsis Campaign: International Guidelines for Management of Severe Sepsis and Septic Shock, 2012. *Intensive Care Med* 2013;39:165-228.
3. Yoon SH. Concerns of the anesthesiologist: anesthetic induction in severe sepsis or septic shock patients. *Korean Journal of Anesthesiology.* 2012;63(1):3-10.
4. Risti AD, Seferovi PM, Maisch B. Management of pericardial effusion: the role of echocardiography in establishing the indications and the selection of the approach for drainage. *Herz.* 2005;30(2):144-50.
5. Maisch B, Seferovi PM, Risti AD, et al. Guidelines on the diagnosis and management of pericardial diseases. Executive summary. *Eur Heart J.* 2004;25:587-610.
6. Modak RK. Pericardial diseases and cardiac trauma. In: Hines RL, Marschall KE, eds. *Stoelting's anesthesia and co-existing disease.* Saunders/ Elsevier, Philadelphia, PA, 2008:125-133.
7. Jarineshin H, Kashani S, Vatankhah M, Abdulhazade Baghaee A, Sattari S, Fekrat F. Better hemodynamic profile of laryngeal mask airway insertion compared to laryngoscopy and tracheal intubation. *Iran Red Crescent Med J.* 2015;17:28615.
8. Gascho JA, Martins JB, Marcus ML, Kerber RE. Effects of volume expansion and vasodilators in acute pericardial tamponade. *Am J Physiol.* 1981;240:49-53.