

## Excision of right nasolabial cyst under intra oral infra orbital nerve block – a case report and a short review

S. Parthasarathy<sup>1,\*</sup>, K. Indu<sup>2</sup>

<sup>1</sup>Associate Professor, <sup>2</sup>PG Student, Mahatma Gandhi Medical College & Research Institute, Puducherry

**\*Corresponding Author:**

Email: painfreepartha@gmail.com

### Abstract

Nasolabial cyst is quite a rare non-odontogenic, soft-tissue cyst forming in the sublabial area and the anterior maxillary region. The patients present to us with a slowly enlarging swelling, usually without any symptoms. They are commonly diagnosed earlier because of cosmetic concerns. Many a time, they are excised either under general or local anesthesia. Surgery is also feasible with nerve blocks. Infra orbital nerve is the terminal branch of the maxillary division of trigeminal nerve. Usually the block of this nerve is not commonly used as a sole anesthetic technique even in specific facial surgeries. We report a successful management of a case of excision of nasolabial cyst in an adult male under intra oral approach of infra orbital nerve block alone.

**Keywords:** Infra orbital nerve, Nasolabial cyst, Nerve block, Regional anesthesia

### Introduction

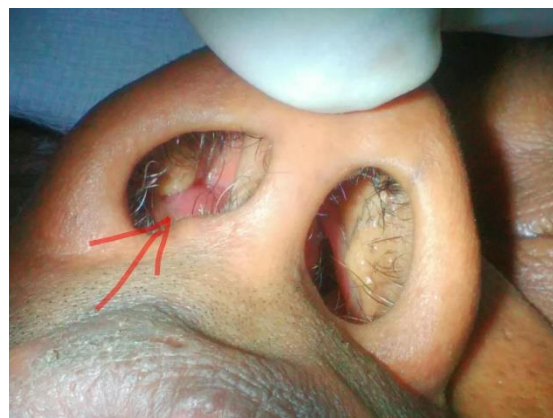
Nasolabial cysts are relatively rare non odontogenic soft-tissue swellings of nasal vestibule, canine fossa, and the sub labial region. The swelling in sublabial fold, lips, face are usually painless but can cause nasal obstruction. Pain occurs if the cyst gets infected.<sup>(1)</sup> The excisions of these cysts are usually done under general anesthesia or local anesthesia. If there is any anticipated difficulty in establishing local anesthesia because of the fear of altered delineation of cyst borders, the alternate anesthetic techniques can be thought of. The infraorbital nerve, the terminal branch of the maxillary nerve, emerges about one cm below the middle of the lower orbital margin through the infraorbital foramen. The blockade of this nerve is commonly used for postoperative analgesia of cleft lip repair in infants.<sup>(2)</sup> We attempted an intraoral approach to block the infraorbital nerve. We used it as a sole anesthetic technique and successfully managed the case.

### Case Capsule

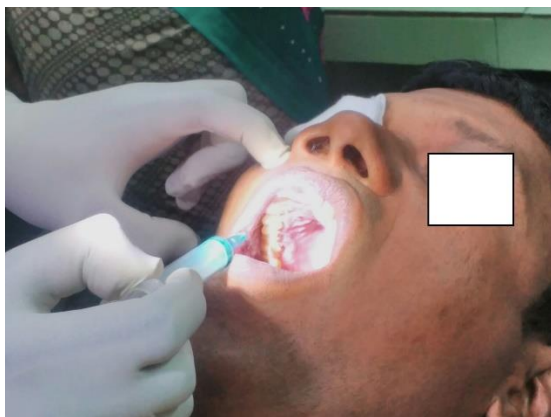A 42 year old male presented with nasal obstruction with a swelling right nose for two months. There were no other complaints. Clinical examination revealed a swelling in the edge of the right nasal cavity whose inner border can't be clinically clearly defined. (Fig. 1). The surgeon sensed the difficulty of administering local anesthesia and opted for general anesthesia. He was a healthy adult male with normal routine investigations and taken up as American society of anesthesiologists (ASA) classification of physical status I. The plan was to administer intra oral infra orbital nerve block. The technique was as follows:

After 1 mg. of intravenous midazolam, the palpating finger of the left hand was placed over the inferior border on the infra orbital rim. The cheek was

retracted and needle was introduced in the mucosa just opposite the upper second premolar approximately 0.5 cm away from the buccal surface. The needle was further introduced towards the palpating finger of the left hand and 3 ml of 0.5% bupivacaine was injected after aspiration. The approximate depth was 2 .5 cm. (Fig. 2) The establishment of complete analgesia was around ten minutes and the surgery was completed by a sublabial intra oral incision in another twenty minutes. The size of the cyst was around 3×3 cm. There was neither bleeding nor swelling in the infra orbital region. The patient was discharged on the same day. The histopathological report was a benign non odontogenic nasolabial cyst. The postoperative period of four months so far has been uneventful.



**Fig. 1**



**Fig. 2**

### Discussion

Nasolabial cysts represent only about 0.7% of all the cysts in the maxillofacial region, and 2.5% of non-odontogenic cysts. The pathogenesis of formation of nasolabial cysts is not yet fully understood. Two hypotheses are being currently proposed; they originate either from the facial fissure cysts or from the remnants of the nasolacrimal ducts. The former hypothesis proposes that these cysts come from sequestering of embryological epithelial tissue in facial fissures which result from fusion of the nasal and maxillary processes. The latter proposes that persistence of nasolacrimal duct epithelial remnants present between the maxillary and nasal processes forms such nasolabial cysts. These cysts are most often found in females in the fourth to fifth decades of their life. They usually present to us as a painless localized swelling in the nasogenian sulcus and the nasal alar base. The diagnosis of such cysts is essentially clinical.<sup>(3,4)</sup> Bi digital palpation usually reveals a fluctuating swelling between gingivolabial sulcus and the floor of the nasal vestibule, which helps to confirm the diagnosis as it happened in our case. Diagnostic techniques include flexible nasal fibrescopy, computed tomography (CT) and magnetic resonance imaging<sup>(5)</sup> (MRI). In our case, a CT scan was done for confirmation. Treatment is definitely surgical, usually marsupialization or enucleation of the cyst. Early excision under anesthesia forms the treatment of choice. Other methods of treatment include: cauterization, needle aspiration, injecting sclerosants and incision for drainage.<sup>(6)</sup> These alternative methods, have in fact high recurrence rates. The options in anesthetic techniques vary with general, local or nerve blocks. The infra orbital nerve block is used to accomplish regional anesthesia of the face. This procedure offers a few advantages over local tissue infiltration. A nerve block can achieve anesthesia with a smaller amount of the local anesthetic drug than is required for local infiltration or field blocks. In addition, unlike local infiltration, nerve blocks can provide the needed anesthesia without any tissue distortion. Hence the infra orbital nerve block is a convenient alternative for

situations especially facial lacerations in which tissue distortion would be unacceptable.<sup>(7)</sup> But in our case, even though a CT scan delineated the swelling, clinically it was difficult to establish local infiltration. The infra orbital nerve supplies sensory branches to the lower eyelid, the side of the nose, and the upper lip which was acceptable in our patient: Bleeding/hematoma, infection, inadvertent intravascular injection, swelling of face/ eyelid, allergic reaction to anesthetic, damage to nerves/ vessels are some of the complications of infra orbital nerve block.<sup>(8)</sup> None happened in our case. Our case was a male even though it is common in females. There was no specific contra indication for an extra oral approach in our case but in a few instances, there may be other abrasions which preclude the use of an extra oral approach. During the extra oral technique,<sup>(9)</sup> the needle is in very close proximity to the facial artery. Because of this closeness, it's better to avoid the addition of vasoconstrictors to the local anesthetic agent. The infra orbital foramen is located with the palpating finger as described earlier. The skin overlying the infraorbital foramen is cleaned with povidone iodine. Using sterile technique, the needle is inserted through the skin, the subcutaneous tissue later and finally the quadratus labii superioris muscle. Careful aspiration before any injection is a must. As the facial vein and the artery are very close to the needle in this position, intravascular injection is a definite possibility. After injection of local anesthetic (3-5 ml), the infiltrated tissue may appear swollen. The area is massaged for ten to fifteen seconds. If the nerve block is not successful, or if the exact anatomy of the infra orbital foramen is not very clear, a field block is a useful alternative. To administer the field block, 5 mL of local anesthetic solution is injected into the upper buccal fold in an arc-shaped distribution. The area is massaged for 10-15 seconds to hasten the onset of anesthesia. Even though this technique is not as precise as the previously described nerve block, it may often accomplish the same anesthetic effect. Local tissue distortion may render surgical excision or marsupialization difficult. Regional nerve blocks of the face as a sole anesthetic technique even though reported in literature, are rare.<sup>(10,11)</sup> As the mean size of nasolabial cysts in many studies was around 2.18 cm,<sup>(12)</sup> ours was a little bigger which favored the use of nerve block. Hence we decided to report this case of excision of nasolabial cyst under sole infra orbital nerve block to popularize such simple affordable techniques. This perhaps may be first reported case of sublabial excision of nasolabial cyst under intra oral approach of blocking the infra orbital nerve.

### Conclusion

To conclude, successful excision of unilateral nasolabial cyst can be done with carefully administered infraorbital nerve block especially with an intra-oral approach without any significant side effects. This case

is reported presumably as the first such case of excision of nasolabial cyst with the above described technique.

### References

1. K. El-Din and A. A. el-Hamd, "Nasolabial cyst: a report of eight cases and a review of the literature," *Journal of Laryngology and Otology*, 1999;113(8):747-749.
2. A.T Senberg, F.W. Kimble. Infraorbital nerve block in neonates for cleft lip repair: anatomical study and clinical application. *British Journal of Anaesthesia* 1995;74:506-508.
3. Yuen HW, Julian CY, Samuel CL. Nasolabial cysts: clinical features, diagnosis, and treatment. *Br J Oral Maxillofac Surg.* 2007;45(4):293-7.
4. Schuman DM. Nasolabial cysts: mechanisms of development. *Ear Nose Throat J* 1981;60:389-94.
5. Curé JK, Osguthorpe JD, van Tassel P. MR of nasolabial cysts. *Am J Neuroradiol* 1996;17:585-8.
6. Golpes CC, Junior ABD, Vidolin C, Silveira FCA. Cisto nasolabial bilateral. *Rev Bras Otorrinolaringol* 1995;61:30-3.
7. Aggarwal A, Kaur H, Gupta T, Tubbs RS, Sahni D, Batra YK, et al. Anatomical study of the infraorbital foramen: A basis for successful infraorbital nerve block. *Clin Anat.* 2015;28(6):753-60.
8. Rishi Kumar Bali, Vijay P Nautiyal, Praveen Sharma and Rohit Sharma. Infra-orbital nerve block anesthesia—extended coverage using intra-oral 'molar approach' *Journal of Oral Biology and Craniofacial Research.* 2011;1(1):53-54.
9. Kleier DJ, Deeg DK, Averbach RE. The extraoral approach to the infraorbital nerve block. *J Am Dent Assoc.* 1983 Nov;107(5):758-60.
10. S. Parthasarathy. Anaesthetic management of bilateral nasal polypectomy in a patient with Kartagener syndrome. *Sri Lankan Journal of Anaesthesiology.* 2012;20(1):56-57
11. S. Parthasarathy, R. Sripriya. Fixation of bilateral condylar fractures with maxillary and mandibular nerve blocks. *Anesthesia: Essays and Researches;* 2015.9(2);281-3.
12. Romualdo Suzano, Louzeiro Tiago, Mayko Soares Maia, Gustavo Motta Simplicio do, Nascimento Juliano, Piotto Correa, Daniel, Cauduro Salgado. Nasolabial cyst: diagnostic and therapeutical aspects. *Rev. Bras. Otorrinolaringol.* 2008;(74).1; 39-43.