

Content available at: <https://www.ipinnovative.com/open-access-journals>

Indian Journal of Clinical Anaesthesia

Journal homepage: [www.ijca.in](http://www.ijca.in)

## Case Report

# Anaesthetic management in neonate with rare finding of absent ribs as a part of Jarcho Levin syndrome posted for thoracolumbar meningomyelocele repair: A case report

Madhu Ahlawat<sup>1\*</sup>, Navdeep Kaur<sup>1</sup>, Arti<sup>1</sup>, S Gowrishankar<sup>1</sup>, Priyanka Rani<sup>1</sup>

<sup>1</sup>Dept. of Anaesthesiology and Critical Care, Pandit Bhagwat Dayal Sharma PGIMS, Rohtak, Haryana, India



### ARTICLE INFO

#### Article history:

Received 07-06-2024

Accepted 28-06-2024

Available online 30-08-2024

#### Keywords:

Difficult airway

Neural tube defect

Respiratory distress

### ABSTRACT

The congenital absence of ribs is a very rare finding. It can manifest as a standalone anomaly or as part of the syndrome. We came across a case in which the absence of ribs was associated with a neural tube defect. These findings were in favor of Jarcho Levin syndrome. Jarcho Levin syndrome, also known as spondylocostal dysostosis, is an uncommon genetic disorder with a global incidence of 1/40000 births. Very few case reports of it are in the Indian literature. It is characterized by vertebral malformations and the congenital absence of ribs, resulting in a crab-like appearance in the chest. It is linked to a wide range of non-skeletal abnormalities, including hydrocephalus, neural tube defects, tracheal anomalies, and abnormalities in the cardiac, renal, gastrointestinal, and urinary systems. The preoperative evaluation should be thoroughly done with a detailed systemic examination for the multisystem affliction of this syndrome. The anesthetic challenges in neonates with Jarcho Levin syndrome includes challenging airways due to defects in skeletal growth and hydrocephalus, proper positioning to avoid sac rupture, prone position ventilation, temperature control and fluid management. The prone position ventilation can be complicated by the absence of ribs and decreased respiratory reserve due to associated scoliosis and kyphosis. This case report highlights the anesthetic management of a three-day-old neonate with Jarcho Levin syndrome posted for thoracolumbar meningomyelocele repair.

This is an Open Access (OA) journal, and articles are distributed under the terms of the [Creative Commons Attribution-NonCommercial-ShareAlike 4.0 License](https://creativecommons.org/licenses/by-nc-sa/4.0/), which allows others to remix, tweak, and build upon the work non-commercially, as long as appropriate credit is given and the new creations are licensed under the identical terms.

For reprints contact: [reprint@ipinnovative.com](mailto:reprint@ipinnovative.com)

## 1. Introduction

We present the anesthetic management of a three-day-old neonate with Jarcho Levin syndrome posted for thoracolumbar meningomyelocele repair. The congenital absence of ribs is a very rare finding that can be an isolated anomaly or be part of the syndrome. Jarcho-Levin syndrome is a rare disorder with global incidence of 1/40000 births. Jarcho-Levin syndrome is a diverse group of inherited skeletal diseases marked by short trunk dwarfism and associated rib and vertebral anomalies. It exhibits variable inheritance patterns and prognosis.<sup>1</sup> Children with JLS

have a difficult airway due to defects in skeletal growth, a large head size because of hydrocephalus, and cranio-facial abnormalities.<sup>2</sup> In Jarcho-levin syndrome, there are vertebral segmentation and formation defects throughout the spine, as well as fusion of ribs at the costovertebral joint bilaterally and intrinsic rib anomalies with the consequences of global foreshortening of the thorax as well as restrictive lung expansion, which can present as thoracic insufficiency syndrome.<sup>3</sup>

## 2. Case Report

A 3-day-old baby with a weight of 2.5kg presented with cystic swelling in the thoracolumbar region and was

\* Corresponding author.

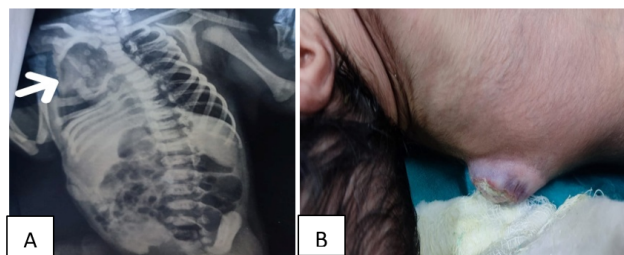
E-mail address: [madhuahlawat27@gmail.com](mailto:madhuahlawat27@gmail.com) (M. Ahlawat).

diagnosed with meningocele and posted for surgical excision and repair of the defect. The baby was delivered by normal vaginal delivery at full term at a private hospital and was weighed to be 2.7 kg. The baby did not cry immediately after birth and required oxygen support. The systemic examination of the child was normal except for the small cystic swelling in the thoracolumbar region, which measured 7\*5 cm. The child had no history of seizures, but bilateral lower limb weakness (1/5) was present when the baby was lifted in both arms. On examination, the baby was afebrile with a heart rate of 125 bpm, a respiratory rate of 45/min, and a SpO<sub>2</sub> of 97% on the nasal prongs with oxygen flow of 2L/min. There was no palor, icterus, or cyanosis. On CVS examination, S1 and S2 heard with no murmur. On respiratory system examination, normal vesicular breath sounds were heard in all the lung fields. On spine examination, there was a soft, cystic swelling measuring 7\*5cm in the thoracolumbar region with intact skin over it.

Neonate was kept nil per orally for 4 hours in the morning and the patient was brought to a prewarmed operating room. To prevent any injuries to the meningocele, a sac was placed on donut padding. An ECG and pulse oximeter were applied, and baseline vital parameters were a heart rate of 135bpm and a SpO<sub>2</sub> of 97% on nasal prongs with oxygen flow at 2 L/min. Neonate was already cannulated with a 24G cannula. The neonate was preoxygenated with oxygen for 3 minutes. Induction was done using inj atropine 30 mcg i.v., inj fentanyl 3mcg i.v., and propofol 5mg i.v. Check ventilation was done and was given inj atracurium 0.75 mg and was intubated using 3mm uncuffed ETT. After confirming the auscultation on the bilateral side, the ETT was fixed at 8cm on the right side of the mouth. Neonate was prone-positioned with rolls under the chest, pelvis, and eye padding applied. Air entry was again checked after prone positioning. All exposed parts were wrapped with cotton for body heat conservation. Maintenance of anesthesia was done with oxygen, air, sevoflurane and inj atracurium 0.15 mg as and when required. After completion of surgery, the patient was reversed with injection neostigmine and glycopyrrolate and extubated after the return of airway reflexes and adequate muscle power. There was a complete recovery and the baby was shifted back to pediatric surgery NICU on nasal prongs. Gradually, the oxygen support was weaned off, and the baby was discharged on the 4th postoperative day.

### 3. Discussion

Deformities of the ribs are the rare entities which can be detected at birth by the neonatologist or can be an incidental finding. It can be superior, midthoracic or inferior absence of ribs. Inferior ribs deformities are difficult to detect and are associated with grave complications such as poor cardiac reserve, lung herniation and carries the poor prognosis.



**Figure 1:** A): Chest X-ray showing absence of superior ribs on right side; B): Picture showing thoracolumbar meningocele

Rib deformities can also present as extra ribs, abnormally short ribs and abnormally shaped ribs and can result from genetic mutations. They may be inherited or may occur as spontaneously as denovo gene mutations. It can also be the result of an insignificant blood supply during the embryonic period. Rib deformities can range from minor variations to life-threatening conditions. Rib defects typically do not occur in isolation, they are often accompanied by developmental failures of the vertebral column and the thoracic wall muscles, with frequent involvement of the pleura as well. As in our case, the absence of ribs was associated with thoracic meningocele and was diagnosed as a part of Jarcholevin syndrome.<sup>4-6</sup>

Jarcho-Levin syndrome comprises a varied group of inherited skeletal disorders characterized by short trunk dwarfism and anomalies in the ribs and vertebrae, with variable inheritance patterns and prognosis. In spondylothoracic dysostosis, throughout the spine patients exhibit defects in the segmentation and formation of the vertebrae, such as hemivertebrae, block vertebrae, and unsegmented bars. These defects are accompanied by bilateral posterior rib fusion at the costovertebral joints, but intrinsic rib anomalies are not present. Radiologically, this results in a fan-like configuration of the thorax. The combination of vertebral defects and rib fusion contributes to compromised ventilatory function, increasing the susceptibility of patients to recurrent pneumonia and subsequently, congestive heart failure. In spondylocostal dysostosis, patients typically exhibit a milder phenotype. Vertebral segmentation and formation defects vary, and there is no symmetric posterior rib fusion. Instead, intrinsic and asymmetric rib anomalies, such as broadening, bifurcation, and fusion, are present. Due to the asymmetry of thoracic anomalies, patients often have a less restrictive thorax, leading to a better prognosis. Both phenotypes typically feature individuals with normal intelligence. Associated anomalies are common in both, including undescended testes, hydronephrosis, various types of hernias (inguinal, umbilical, and diaphragmatic), patent foramen ovale, renal anomalies, imperforate anus, high-arched palate, cleft palate, and neural tube defects.<sup>7</sup> Ashgar et al., on evaluation of 321 cases worldwide

shows the association of multiple anomalies with Jarcho Levin syndrome, of which neural tube defects were most common.<sup>8</sup> Suryaningtyas et al. also reported a rare case of Jarcho-Levin syndrome in association with neural tube defects and other congenital malformations.<sup>7</sup>

Neonates with JLS require thorough pre-operative evaluation to identify the extent of multi-system involvement. Standard pre-anesthetic investigations should be supplemented with a detailed neurological workup, including MRI of brain and spine, to assess structural anomalies and potential complications such as hydrocephalus or Arnold Chiari malformation. Cardiac and abdominal evaluations are essential to rule out congenital heart defects and abdominal organ anomalies. Children with JLS have challenging airway due to defects in skeletal growth, an enlarged head because of hydrocephalus, and cranio-facial abnormalities. Furthermore, severe scoliosis and kyphosis result in reduced respiratory reserves and a heightened risk of hypoxia during apneic episodes, so adequate preoxygenation should be done. Additionally, accessing the airway can be challenging due to thoracic lordosis and compensatory cervical kyphosis, potentially making intubation very difficult even with proper positioning. A difficult airway cart needs to be prepared beforehand.<sup>2</sup> The distorted airway anatomy and frequent respiratory infections increase the likelihood of post operative laryngospasm, bronchospasm and hypoxia. Schulman et al reported 2 cases of airway abnormalities in patients with JLS requiring flexible fiberoptic bronchoscopy.<sup>9</sup> Prior to induction on the operating table, a silicon or cotton donut with padding needs to be used for positioning the patient supine and accommodating the meningocele sac.

In Jarcho-Levin syndrome, throughout the spine, there are defects in vertebral segmentation and formation, as well as fusion of ribs at the costovertebral joint bilaterally and intrinsic rib anomalies with the consequences of global foreshortening of the thorax as well as restrictive lung expansion, which can present as thoracic insufficiency syndrome.<sup>3</sup> Cyanosis during crying, not linked to cyanotic heart disease, can occur due to tracheal collapse from missing cartilaginous rings in the trachea.<sup>9</sup> Additionally, there may be need for mechanical ventilation in the postoperative period due to kyphoscoliosis and reduced compliance of the chest wall. The main factors contributing to perioperative morbidity and mortality in these patients are the pulmonary outcomes stemming from dysplasia of thoracic skeleton and related anomalies.<sup>2</sup> Thus, comprehensive care during the pre-operative, anaesthetic, and post-operative phases is crucial for successful outcomes in patients with Jarcho-Levin syndrome.

#### 4. Conclusion

A working knowledge of JLS is needed for successful anesthetic management and optimization of postoperative

outcomes. Detailed preoperative evaluation and preparation with specialty consultations, an appropriate anesthetic approach, and good postoperative care will decrease perioperative morbidity and mortality in JLS patients. Awareness of this syndrome should be heightened during the evaluation of patients presenting with neural tube defects and respiratory distress.

#### 5. Sources of Funding

None.

#### 6. Conflict of Interest

None.

#### References

1. Chen H. Jarcho-Levin Syndrome. In: Atlas of Genetic Diagnosis and Counseling. United States: Humana Press; 2006. p. 553–7.
2. Hayek S, Burke SW, Boachie-Adjei O, Bisson LJ. Jarcho-Levin syndrome: report on a long-term follow-up of an untreated patient. *J Pediatr Orthop B*. 1999;8(2):150–3.
3. Campbell RM, Smith MD, Mayes TC, Mangos JA, Willey-Courand DB, Kose N, et al. The characteristics of thoracic insufficiency syndrome associated with fused ribs and congenital scoliosis. *J Bone Joint Surg Am*. 2003;85(3):399–408.
4. Chen HJ. Congenital absence of multiple ribs. *World J Pediatr*. 2007;3:71–3.
5. Mehta MH, Dekiwadia DB, Hathila VP, Patel RV. Congenital thoracic wall deformities. *Indian Pediatr*. 1991;28(2):178–80.
6. Hannam S, Greenough A, Karani JB. Rib abnormalities arising before and after birth. *Eur J Pediatr*. 2000;159(4):264–7.
7. Kulkarni ML, Sn R, Vani HN, Manjunath KS, Matani D. Jarcho-Levin syndrome. *Indian J Pediatr*. 2006;73(3):245–7.
8. Asghar I, Zameer S, Khan TA, Zahid MA, Khan M, Zameer NUA. Jarcho-Levin syndrome in Pakistan: a case report and review of 321 cases on the principles of diagnosis and management. *Cardiothorac Surg*. 2022;30:13.
9. Schulman M, Gonzalez MT, Bye MR. Airway abnormalities in Jarcho-Levin syndrome: A report of two cases. *J Med Genet*. 1993;30(10):875–6.

#### Author biography

**Madhu Ahlawat**, Senior Resident  <https://orcid.org/0009-0004-7883-5515>

**Navdeep Kaur**, Assistant Professor

**Arti**, PG Student

**S Gowrishankar**, PG Student

**Priyanka Rani**, PG Student

**Cite this article:** Ahlawat M, Kaur N, Arti, Gowrishankar S, Rani P. Anaesthetic management in neonate with rare finding of absent ribs as a part of Jarcho Levin syndrome posted for thoracolumbar meningocele repair: A case report. *Indian J Clin Anaesth* 2024;11(3):431-433.