



## Letter to Editor

## Anaesthetic considerations in dextrocardia with situs inversus totalis: A reversed cardiopulmonary-abdominal landscape

Ridhi Roy<sup>1\*</sup>, Kapil Chaudhary<sup>1</sup>, Munisha Agarwal<sup>1</sup>, Nimith Prabhakar<sup>1</sup>,  
Gunjan Manchanda<sup>1</sup>, Wajaha Karim<sup>1</sup>

<sup>1</sup>Dept. of Anaesthesia, Maulana Azad Medical College, New Delhi, India



## ARTICLE INFO

## Article history:

Received 09-11-2023

Accepted 21-11-2023

Available online 28-11-2023

This is an Open Access (OA) journal, and articles are distributed under the terms of the [Creative Commons Attribution-NonCommercial-ShareAlike 4.0 License](https://creativecommons.org/licenses/by-nc-sa/4.0/), which allows others to remix, tweak, and build upon the work non-commercially, as long as appropriate credit is given and the new creations are licensed under the identical terms.

For reprints contact: [reprint@ipinnovative.com](mailto:reprint@ipinnovative.com)

Situs inversus totalis, an uncommon condition occurring in approximately 1 in 10,000 individuals, is characterized by a complete reversal of the abdominal and thoracic viscera.<sup>1</sup> This anomaly arises from a deviation in embryological development, involving a 270-degree clockwise rotation, contrary to the typical 270-degree anti-clockwise rotation of the thoraco-abdominal organs. Consequently, this leads to a mirrored positioning of the abdominal and thoracic viscera.<sup>2</sup> The anaesthetic management is highly challenging owing to inherent physiological and anatomical concerns. We are reporting a patient with situs inversus totalis who underwent open mesh hernioplasty under general anaesthesia. This communication underscores the notable difficulties encountered in anesthetic management and its diverse implications.

A 66-year-old female presented with an eight-month history of abdominal swelling. Subsequent investigations revealed a diagnosis of incisional hernia (~2x14 cm) with an intestinal component. Notably, the patient had a history of open cholecystectomy one year prior, during which perioperative evaluation revealed situs inversus totalis. The patient's medical history was otherwise unremarkable.

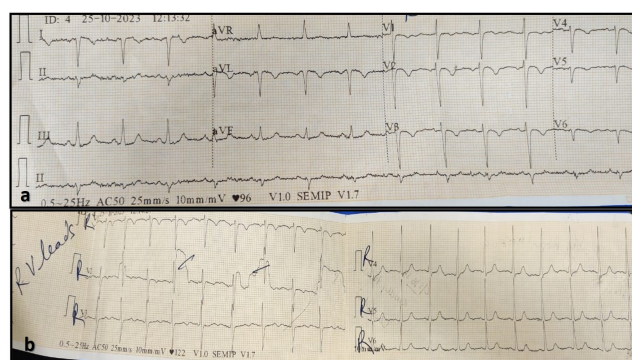
General physical examination revealed cardiac apex displacement to the right side in the 5th intercostal space. Auscultation indicated reduced air entry in the

right upper zone with crepitations. The heart sounds could be auscultated in right precordium. Breath holding time was 18 seconds, and preop-saturation was 96% on room air. Airway examination and spine assessment were unremarkable. Electrocardiogram (ECG) findings displayed right axis deviation (RAD) and T-wave inversion in leads V1-V5 (Figure 1 a). Chest X-ray revealed cardiac shadow and gastric bubble on right side with cystic bronchiectatic changes (Figure 2). CECT chest and abdomen confirmed situs inversus totalis. A repeat ECG with right leads placement demonstrated normal sinus rhythm (Figure 1b). Pulmonary function tests (PFT) indicated a moderate obstruction with a mild restrictive pattern.

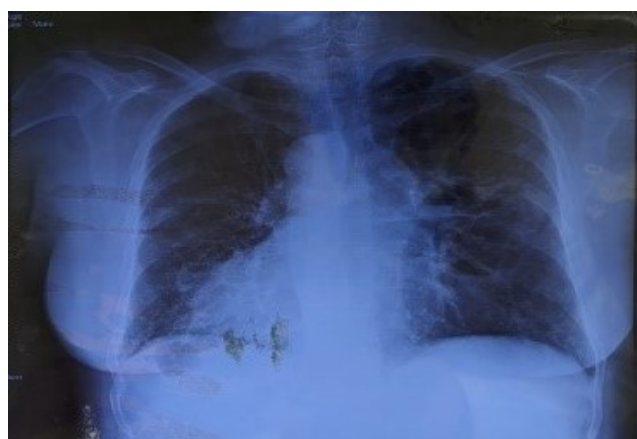Preoperative respiratory optimization measures were performed including nebulization with Levosalbutamol, ipratropium bromide and budesonide eight hourly, steam inhalation, postural chest physiotherapy, and incentive spirometry. Tablet Ranitidine 150 mg and tablet Alprazolam 0.25 mg were administered the night before and on the morning of surgery. Written informed consent for publication was taken from patient. In the operation room, the ECG electrodes were repositioned with reversal of leads as normal lead placement indicated ischemic changes similar to preoperative ECG strip findings (Figure 3). General anaesthesia (propofol, fentanyl, vecuronium based induction and sevoflurane-nitrous oxide based maintenance) supplemented with epidural analgesia was administered

\* Corresponding author.

E-mail address: [royridhi12@gmail.com](mailto:royridhi12@gmail.com) (R. Roy).

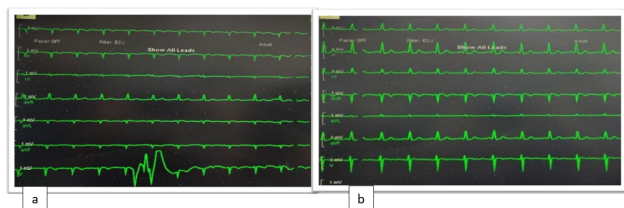


**Figure 1:** ECG strip with normal lead placement (a) and with right leads placement (b)



**Figure 2:** Chest X-ray showing cardiac shadow and gastric bubble on Right side with cystic bronchiectatic changes

utilizing LMA ProSeal™ airway conduit and controlled ventilation. Hydrocortisone 200 mg intravenously was administered for chest condition. Anaesthetic plane was maintained intraoperatively, guided by BIS in the range of 45-55. The airway pressure was consistently high in the absence of any bronchospastic/ obstructive phenomenon. The surgical procedure proceeded uneventfully, lasting ninety minutes and post operative course was unremarkable.



**Figure 3:** Intraoperative ECG with normal lead placement (a) and reversal of leads (b)

Patients with situs inversus totalis pose unique challenges to the anaesthesiologist as well as surgeons. The

condition being rare, the surgeons and anaesthesiologist lack much experience in dealing such patients. These patients pose preoperative diagnostic dilemma. Absence of apex beat and heart sounds on the left precordium should arouse suspicion and these should be checked on right side. If unsuspected or missed on examination, ECG would reveal features suggestive of ischemic heart disease and misdiagnosis. Preoperative detailed clinical examination and chest X-ray usually indicates presence of dextrocardia with situs inversus and ECG with reversal of leads should be ordered to correctly identify any underlying cardiac pathology. CECT chest and abdomen would help identify cardiopulmonary-abdominal transposition and avoid making wrong incision during abdominal surgeries and thereby preventing increased surgical duration/ complications.

Situs inversus totalis is often associated with primary ciliary dyskinesia and bronchiectasis. Optimization of respiratory function using bronchodilators, chest physiotherapy, and incentive spirometry is paramount. Intraoperative use of heat moisture exchange device facilitates administration of moist and filtered gases during mechanical ventilation. Congenital heart disease may also be associated with situs inversus totalis and require preoperative echocardiographic evaluation. Spinal deformities, such as split cord, spina bifida, meningomyelocele, and scoliosis, are documented in the literature, necessitating careful evaluation if surgery under neuraxial anaesthesia is contemplated.<sup>3</sup>

Intraoperative monitoring necessitates placement of ECG electrodes in reverse direction due to altered surface electric polarity, which could otherwise lead to a misleading interpretation of intraoperative ischemia (Figure 3). Premedication drugs that depress ventilation or ciliary activity should be avoided in dextrocardia associated with Kartagener's syndrome.<sup>4</sup> And in the event of cardiac arrhythmia or arrest, cautious application of defibrillator pads in a reversed orientation is crucial. High airway pressures may be observed due to underlying chest condition, in the absence of bronchospasm. This observation underscores the complex nature of the patient's respiratory dynamics and suggests a need for vigilant monitoring and potentially further intervention to address the observed challenges in lung function. Maintenance of adequate depth of anaesthesia and use of agents facilitating bronchodilation is essential.


In the context of situs inversus totalis, it is generally safe to advocate regional anaesthesia for infra-umbilical surgeries over general anaesthesia, provided there is no spinal anomaly. However, in the described case, where the defect extended just below the xiphoid process, a supraumbilical approach was chosen. Hence, an accurate diagnosis of situs inversus, coupled with comprehensive pre-operative evaluation and knowledge, plays a pivotal role


in minimizing potential complications.


## References

1. Bajwa SJ, Kulshrestha A, Kaur J, Gupta S, Singh A, Parmar SS. The challenging aspects and successful anaesthetic management in a case of situs inversus totalis. *Indian J Anaesth*. 2012;56(3):295–7.
2. Song JY, Rana N, Rottman CA. Laparoscopic appendectomy in a female patient with situs inversus: Case report and literature review. *JSLs*. 2004;8(2):175–7.
3. Dwarakanath S, Suri A, Garg A, Mahapatra AK, Mehta VS. Adult complex spinal dysraphism with situs inversus totalis: A rare association and review. *Spine (Phila Pa 1976)*. 1976;30(8):225–8.
4. Bansal T, Lal J. Dextrocardia with situs inversus totalis: Anesthetic implications and considerations. *Indian Anaesth Forum*. 2018;19(2):92–3.


## Author biography


**Ridhi Roy**, PG Student  <https://orcid.org/0009-0005-8224-9137>

**Kapil Chaudhary**, Professor  <https://orcid.org/0000-0002-6018-3406>

**Munisha Agarwal**, Director Professor and Head  <https://orcid.org/0000-0003-2958-6810>

**Nimith Prabhakar**, Senior Resident  <https://orcid.org/0009-0000-8949-5545>

**Gunjan Manchanda**, Senior Specialist  <https://orcid.org/0000-0002-9732-4647>

**Wajaha Karim**, Specialist  <https://orcid.org/0000-0002-8701-4231>

**Cite this article:** Roy R, Chaudhary K, Agarwal M, Prabhakar N, Manchanda G, Karim W. Anaesthetic considerations in dextrocardia with situs inversus totalis: A reversed cardiopulmonary-abdominal landscape. *Indian J Clin Anaesth* 2023;10(4):417-419.