

Content available at: <https://www.ipinnovative.com/open-access-journals>

Indian Journal of Clinical Anaesthesia

Journal homepage: www.ijca.in

Letter to Editor

Epidural knot – A scary complication to be wary of

Teena Peter^{1*}, Sachin George¹¹Dept. of Anaesthesiology, Rajagiri Hospital, Kochi, Kerala, India

ARTICLE INFO

Article history:

Received 29-10-2023

Accepted 10-11-2023

Available online 28-11-2023

This is an Open Access (OA) journal, and articles are distributed under the terms of the [Creative Commons Attribution-NonCommercial-ShareAlike 4.0 License](https://creativecommons.org/licenses/by-nc-sa/4.0/), which allows others to remix, tweak, and build upon the work non-commercially, as long as appropriate credit is given and the new creations are licensed under the identical terms.

For reprints contact: reprint@ipinnovative.com

Keywords:

Epidural knot

Labor analgesia

Epidural complications

Epidural anesthesia, while undoubtedly a superior method for providing pain relief, is not without its potential complications. One such rare yet significant complication is the formation of knots in epidural catheters.¹ Over the years, there have been reported cases of epidural knots and various techniques for their removal.² In this report, we present our experience with a knotted catheter and a unique method we employed to safely extract it.

Our patient, a 28-year-old primigravida, presented for labour epidural. She had no known comorbidities and her blood investigations were normal. After obtaining informed consent, she was positioned in the sitting position for the labour epidural procedure. Following proper aseptic measures and the administration of local anesthesia, we used an 18G Tuohy needle with a loss of resistance (LOR) technique using air to identify the epidural space at the L2-L3 level, approximately 6 cm from the midline.

The epidural catheter was initially threaded smoothly up to 20 cm without any resistance. However, during an attempt to aspirate, the catheter yielded bloody fluid. Consequently, we decided to retract and reposition it. To our surprise, we encountered significant resistance while attempting to pull the catheter back at around 8 cm from its tip. Recognizing

the complexity of the situation, we immediately called in a senior consultant for assistance. Despite their expertise and multiple traction manoeuvres, the catheter remained stuck at approximately 4 cm from its tip. It appeared that the catheter had become entangled in the fibres of the ligamentum flavum, which posed a unique challenge.

We made a carefully considered decision to introduce a Tuohy needle over the catheter in an attempt to release the entrapped ligamentum flavum fibres. During this process, a tell-tale "giveaway" sensation was felt, and the needle was then removed. Upon reapplying sustained traction, the catheter was successfully and safely pulled out intact (Figure 1).

Remarkably, the patient remained pain-free throughout the procedure, with no signs of nerve impingement. Subsequently, we inserted another epidural catheter at the L2-L3 level without any complications, providing adequate pain relief throughout the labour. The patient reported no neurological consequences up to the time of her discharge.

Knottting of epidural catheters is an exceptionally rare complication, with an incidence rate of only 0.0015%.¹ This complication is most frequently observed in obstetric patients and typically occurs in the lumbar region.² Excessive threading of the catheter into the epidural space is a well-documented risk factor.³ Fortunately, in

* Corresponding author.

E-mail address: teena12a@gmail.com (T. Peter).

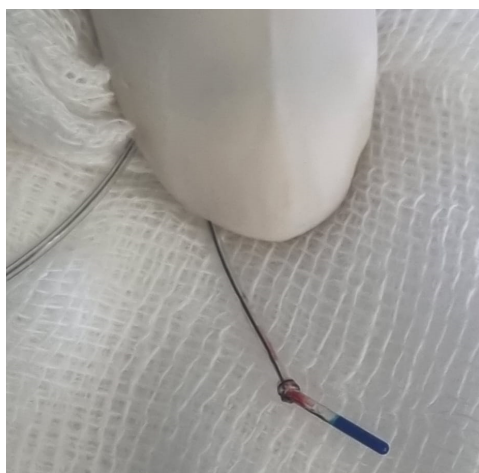


Figure 1: Epidural knot after removing catheter intact

70% of cases, stuck epidural catheters can be removed without breakage through gradual traction with the patient positioned as during insertion.⁴

In our case, we encountered a catheter stuck 4 cm from its tip, and we successfully managed it by taking the calculated risk of releasing ligamentum flavum fibres while carefully monitoring for any signs of paraesthesia and then applying gentle traction. While inserting a needle over a stuck catheter is generally discouraged due to the risk of breakage, our success can be attributed to our thorough assessment of the catheter's anatomical position and ensuring that it was not being unnaturally stretched. If traction had proven unsuccessful in retrieving the catheter, we would have

considered further radiological investigations to pinpoint its exact location.

This case serves as a reminder of the importance of considering the rare but potentially serious complication of epidural knotting in all epidural procedures. It underscores the necessity of threading the catheter only to the required length within the epidural space to mitigate such risks.

Conflict of Interest

None.

References

1. Fibuch EE, Mcnitt JD, Cussen T. Knotting of the Theracath after an uneventful epidural insertion for cesarean delivery. *Anesthesiology*. 1990;73(6):1293.
2. Browne RA, Politi VL. Knotting of an epidural catheter: A case report. *Can Anaesth Soc J*. 1979;26(2):142–4.
3. Gozal D, Gozal Y, Beilin B. Removal of knotted epidural catheters. *Reg Anesth*. 1996;21(1):71–3.
4. Brichant JF, Bonhomme V, Hans P. On knots in epidural catheters: a case report and a review of the literature. *Int J Obstet Anesth*. 2006;15(2):159–62.

Author biography

Teena Peter, Consultant

Sachin George, HOD

Cite this article: Peter T, George S. Epidural knot – A scary complication to be wary of. *Indian J Clin Anaesth* 2023;10(4):415-416.