



## Case Report

# Combined thoracic epidural anaesthesia and interscalene brachial plexus block for modified radical mastectomy in a high-risk patient

Shripad Mahadik<sup>1</sup>, Sushmitha K<sup>1</sup>, Deepak Phalgune<sup>2\*</sup>

<sup>1</sup>Dept. of Anaesthesiology, Poona Hospital and Research Centre, Pune, Maharashtra, India

<sup>2</sup>Dept. of Research, Poona Hospital and Research Centre, Pune, Maharashtra, India



### ARTICLE INFO

#### Article history:

Received 05-09-2023

Accepted 26-10-2023

Available online 28-11-2023

#### Keywords:

Modified radical mastectomy

Bronchial asthma

Brachial plexus block

Thoracic epidural anaesthesia

### ABSTRACT

In a case of malignancy of the breast, operation is one of best option for the management of the patient. Modified radical mastectomy (MMR) is commonly conducted by giving general anaesthesia (GA). But GA is not a rational choice in patients who are suffering from bronchial asthma and other associated comorbidities. These patients have additional danger of perioperative morbidity and mortality especially because of respiratory complications. We report successful perioperative management of MMR under combined thoracic epidural anaesthesia and ipsilateral interscalene brachial plexus block in a diagnosed case of malignancy of breast with bronchial asthma, type 2 diabetes mellitus and hypertension.

This is an Open Access (OA) journal, and articles are distributed under the terms of the [Creative Commons Attribution-NonCommercial-ShareAlike 4.0 License](https://creativecommons.org/licenses/by-nc-sa/4.0/), which allows others to remix, tweak, and build upon the work non-commercially, as long as appropriate credit is given and the new creations are licensed under the identical terms.

For reprints contact: [reprint@ipinnovative.com](mailto:reprint@ipinnovative.com)

## 1. Introduction

The National Breast Cancer Foundation has stated that breast malignancy is the second most common malignancy in women, with 38 lakh females detected in the United States of America as of 2019.<sup>1</sup> Modified radical mastectomy (MRM) is the most common surgical treatment for breast malignancy.<sup>2</sup> General anaesthesia (GA), is commonly used for breast surgery, and GA is considered as the foremost reason of perioperative complications, and the risk of postoperative nausea and vomiting (PONV) in about 50%.<sup>3</sup>

Local anaesthesia reduces circulatory, pulmonary and gastrointestinal adverse events in patients who have a high-risk, and decreased immune suppression.<sup>4,5</sup> Therefore, there is an increasing interest in local-regional anaesthesia as a substitute to GA for MRM. We report successful perioperative management of MRM under combined thoracic epidural anaesthesia (TEA) and ipsilateral

interscalene brachial plexus block in a diagnosed case of malignancy of breast with bronchial asthma, type 2 diabetes mellitus (T2DM) and hypertension.

## 2. Case Report

A 70-year-old lady who has a H/O T2DM, hypertension and hyperreactive airway disease for 40 years attended the OPD of a tertiary care hospital, Pune, India with painless left axillary nodule for the last 15 days. She had an active audible wheeze and a history of excisional biopsy of the left breast lump 4 months ago under GA during which there was post-extubation severe bronchospasm for which she was re-intubated and mechanically ventilated for 3-4 days. Excisional biopsy was suggestive of malignancy of the breast and she was advised to undergo MRM.

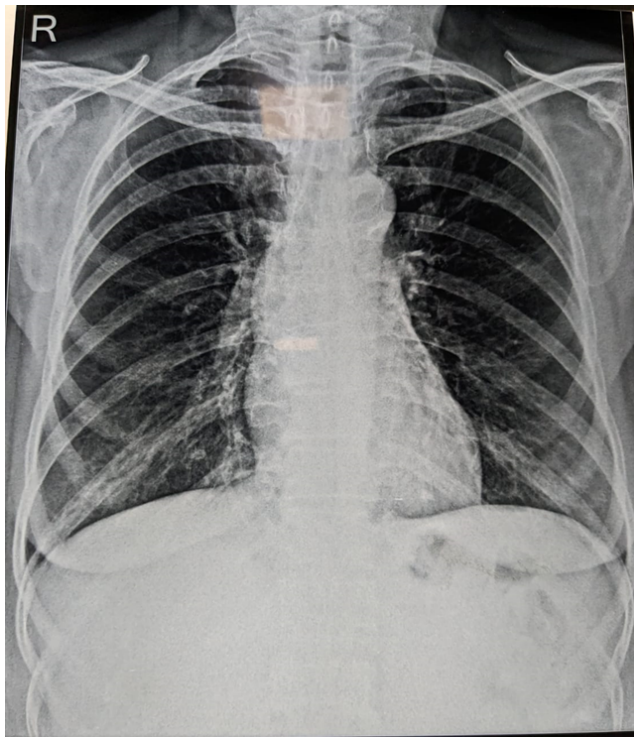
Left side MRM was planned. She was being treated with injectable and inhalational steroids and bronchodilators for bronchial asthma perioperatively. General physical examination was unremarkable. Patient was vitally stable. On auscultation rhonchi were heard in all the areas of the

\* Corresponding author.

E-mail address: [dphalgune@gmail.com](mailto:dphalgune@gmail.com) (D. Phalgune).

chest. Effort tolerance was moderate. Airway examination revealed Mallampatti grade 2 with multiple missing teeth.

Hemogram, blood sugar levels (fasting and post-prandial), kidney function tests, liver function tests, serum electrolytes and coagulation profile were normal. Electrocardiogram (ECG) was suggestive of right bundle branch block, 2-dimensional echocardiography showed sclerotic degenerated aortic valve disease with a left ventricular ejection fraction of 40-45% and chest X-ray had increased broncho-vascular markings bilaterally (Figure 1).



**Figure 1:** X-ray chest

Patient and relatives were informed about pre-existing conditions (bronchial asthma and hypertension) and discussed with various anesthetic plans, along with their potential impacts. After counselling on the benefits of regional anesthesia, they agreed, and gave written informed consent about the same was taken. The night prior to surgery, tab Lorazepam 2 mg, cap Lansoprazole 30 mg were given to alleviate anxiety and decrease acid secretions respectively. Patient was kept nil by mouth for 6 hours prior to surgery and was loaded with 500mL of ringer lactate. In the recovery room, nebulisation using salbutamol 1.25mg and ipratropium bromide 500 $\mu$ g was given.

In the operating room, vital parameters like heart rate, blood pressure, ECG, temperature and respiratory rate were monitored. In sitting position, under aseptic precautions, 18G Tuohy needle was used to induce epidural anaesthesia at T6-T7 interspinous space using hanging drop technique. Epidural catheter was fixed at 11 cms from the skin. Six

mL of 0.5% bupivacaine was given through the epidural catheter and the sensory level achieved was till T4. It was followed by 4 mL of 0.5% bupivacaine twice in a gap of 5-10 minutes and then the sensory level of blockade was from T2- T8 within 20minutes. Left side peripheral nerve stimulator guided interscalene brachial plexus block was given using 6 mL of 0.5% bupivacaine and 9cc of 2% adrenalized lignocaine. Inj. pantoprazole 40 mg, Inj. dexamethasone 8 mg and Inj. metoclopramide 10 mg were given intravenously during the surgery to prevent postoperative nausea and vomiting. The surgery was uneventful. Post-operative pain relief was achieved by 50  $\mu$ g fentanyl and 6 mL of 0.125% bupivacaine 12hourly.

### 3. Discussion

The present case report confirms that regional anaesthesia is a rational and prudent for MRM. The patient had high blood pressure, T2DM and bronchial asthma with active rhonchi, hence GA was not safe to conduct the surgery. The thoracic epidural anaesthesia (TEA) and brachial plexus block were better option than GA. TEA lessens a stress response and airway management is not needed. We supplemented TEA with interscalene brachial plexus block to aid axillary node dissection and to avoid patient discomfort due to hyperextension of the ipsilateral arm during the surgery. Other probable advantages of TEA are hemodynamic stability, lesser pain-relieving medicines, better postoperative pain relief, less PONV, early introduction of feeding, and brief period of hospitalisation. Non-steroidal anti-inflammatory drugs can cause acute attacks of asthma. In the present case satisfactory pain relief was attained by using epidural bupivacaine, fentanyl and intravenous paracetamol. The sporadic use of TEA for surgery of malignancy of breast may be because of complications such as post-dural puncture headache, respiratory complications, damage to spinal cord, spinal/epidural hematoma, and lack of expertise. But if the anaesthesiologist is well experienced and proper precautions are taken, these complications can be prevented.

The nerve supply to the breast, axillary nodes, and pectoral muscles is from the first to the sixth intercostal nerves, brachial plexus, intercostal brachial nerve (T2-T3), supraclavicular nerve, lateral and medial pectoral nerves from the cervical plexus.<sup>6</sup> It was reported that TEA supplemented with interscalene block decreases the use of opioid medications and improves the pain score through the first 24 hours postoperatively in patients who underwent MRM.<sup>7</sup> It was reported that for axillary lymph node dissection local anaesthesia was used with TEA.<sup>8</sup> The paravertebral block is an alternate method to GA for mastectomies. However, paravertebral block requires expertise and is best achieved by the use of ultrasound, which might not be always available in a peripheral set

up. During neural block and surgery, thoracic paravertebral block can cause significant patient distress. For MRM cervical epidural anaesthesia can be used efficaciously; but for patients with poor pulmonary functions and cardiovascular reserve, it is not suggested. Additionally, the phrenic nerve may be paralysed with a cervical epidural block.<sup>9</sup>

Airway hyperresponsiveness during the perioperative period can result in hypoventilation, hypoxemia and cardiac arrhythmia. Therefore, it is essential to select appropriate anaesthetic agents that will benefit the patient. Dexmedetomidine is an anaesthetic adjuvant reported to attenuate perioperative inflammation and improve the immune function of patients who have undergone surgery.<sup>10</sup> Dexmedetomidine is odourless and tasteless and can be administered intranasally, preserving its bioavailability without discomfort. Administered intranasally, it has a relatively fast onset of action of 15 to 30 minutes and a half-life of approximately 2 hours. Because of its pharmacologic properties, dexmedetomidine may offer significant advantages in the setting of acute respiratory distress when sedation is considered. Moreover, patients who receive dexmedetomidine experience a clinically effective sedation, but they are easier to wake in comparison with patients who receive other sedatives.

It was clinically observed that patients who had received dexmedetomidine exhibited reduced airway resistance during mechanical ventilation in surgery and hemodynamic stability during extubation.<sup>11,12</sup>

It has been suggested that the activation of the Toll-like receptor 4/Nuclear factor kappa B (TLR4/NF- $\kappa$ B) pathway can promote the infiltration of inflammatory cells in the airway and trigger airway inflammation.<sup>13</sup> Although strong evidence that the  $\alpha$ -adrenergic receptor is associated with TLR4/NF- $\kappa$ B signalling is still lacking, several studies have indicated that dexmedetomidine can protect organ function by inhibiting TLR4 signalling.<sup>11,14,15</sup> The TLR4/NF- $\kappa$ B signalling pathway has also been associated with the anti-inflammatory effects of dexmedetomidine.<sup>16</sup> Dexmedetomidine may be a safer choice as a sedative and an anaesthetic adjunct in patients with acute asthma. Acute asthma attack causes anxiety and agitation in patients, which hinders treatment and adversely affects patients.<sup>17</sup> Dexmedetomidine allows patients to rest and increase their tolerance to treatment without respiratory depression. It is also used as adjunctive treatment for acute and severe asthma.<sup>17,18</sup>

Lee SH et al. reported that after including patients with chronic obstructive pulmonary disease undergoing lung cancer surgery, dexmedetomidine improved their postoperative clinical status.<sup>19</sup> Groeben H et al. in their study of dogs, showed that dexmedetomidine improved bronchoconstriction and increased the volume of the respiratory tract.<sup>15</sup>

The patients who have high risk of postoperative pulmonary complications, epidural analgesia in the postoperative period improves the perioperative outcome.<sup>8</sup> Epidural fentanyl produces more segmental analgesia with less risk for late respiratory depression. On the other hand, hydrophilic morphine produces delayed respiratory depression which may need an intensive monitoring in the postoperative period.<sup>20</sup>

Sundarathiti et al. in a randomized controlled trial concluded that TEA can be performed using a low dose of local anaesthetic in combination with ipsilateral brachial plexus block for axillary node dissection. The study further stated that TEA can provide better analgesia without probable paralysis of respiratory muscle and sedation that are linked with GA.<sup>21</sup> Doss NW et al. observed that TEA with ropivacaine provides better postoperative analgesia and reduced PONV, enables post-anaesthesia recovery, and provides superior patient satisfaction than GA.<sup>22</sup> Our case report substantiates the earlier studies that MRM can be efficaciously conducted under TEA and ipsilateral interscalene brachial plexus block.

Though MRM is commonly performed under GA even in secondary and tertiary care centres, we emphasize on central and peripheral neuraxial blockade as it offers more patient comfort and better outcome.

#### 4. Conclusions

The effective perioperative management of modified radical mastectomy can be skilfully executed through the synergistic use of thoracic epidural anesthesia (TEA) and an ipsilateral interscalene brachial plexus block. This strategy is especially valuable in a complex clinical scenario involving a patient diagnosed with breast malignancy alongside comorbid conditions such as bronchial asthma, type 2 diabetes mellitus, and hypertension.

#### 5. Source of Funding

None.

#### 6. Conflict of Interest

None.

#### References


- Desantis CE, Ma J, Gaudet MM, Newman LA, Miller KD, Sauer AG, et al. Breast cancer statistics, 2019. *CA Cancer J Clin.* 2019;69(6):438–51.
- Jones C, Lancaster R. Evolution of Operative Technique for Mastectomy. *Surg Clin North Am.* 2018;98(4):835–44.
- Malik OS, Brovman EY, Urman RD. The Use of Regional or Local Anesthesia for Carotid Endarterectomies May Reduce Blood Loss and Pulmonary Complications. *J Cardiothorac Vasc Anesth.* 2019;33(4):935–42.
- Ahn EJ, Kim HJ, Kim KW, Choi HR, Kang H, Bang SR. Comparison of general anaesthesia and regional anaesthesia in terms of mortality and complications in elderly patients with hip fracture: a nationwide population-based study. *BMJ Open.* 2019;9(9):e029245.

5. Wall T, Sherwin A, Ma D, Buggy DJ. Influence of perioperative anaesthetic and analgesic interventions on oncological outcomes: a narrative review. *Br J Anaesth*. 2019;123(2):135–50.
6. Woodworth GE, Ivie RMJ, Nelson SM, Walker CM, Maniker RB. Perioperative breast analgesia: a qualitative review of anatomy and regional techniques. *Reg Anesth Pain Med*. 2017;42(5):609–31.
7. Kaya M, Oğuz G, Şenel G, Kadioğulları N. Postoperative analgesia after modified radical mastectomy: the efficacy of interscalene brachial plexus block. *J Anesth*. 2013;27(6):862–7.
8. Bansal P, Saxena KN, Taneja B, Sareen B. A comparative randomized study of paravertebral block versus wound infiltration of bupivacaine in modified radical mastectomy. *J Anaesthesiol Clin Pharmacol*. 2012;28(1):76–80.
9. Lynch EP, Welch KJ, Carabuena JM, Eberlein TJ. Thoracic epidural anesthesia improves outcome after breast surgery. *Ann Surg*. 1995;222(5):663–9.
10. Wang K, Wu M, Xu J, Wu C, Zhang B, Wang G. Effects of dexmedetomidine on perioperative stress, inflammation, and immune function: Systematic review and meta-analysis. *Br J Anaesth*. 2019;123(6):777–94.
11. Türktan M, Güleç E, Hatipoğlu Z, İlginel MT, Özcengiz D. The effect of sevoflurane and dexmedetomidine on pulmonary mechanics in ICU patients. *Turk J Anaesthesiol Reanim*. 2019;47(3):206–12.
12. Ambesh SP, Dubey M. Effect of intramuscular dexmedetomidine administration before extubation on post-extubation haemodynamics, postoperative sedation, and analgesic requirements: A double blind placebo-controlled study. *Asian J Anaesthesiol*. 2021;59(3):102–10.
13. Duan J, Kang J, Qin W, Deng T, Liu H, Li B, et al. Exposure to formaldehyde and diisononyl phthalate exacerbate neuroinflammation through NF- $\kappa$ B activation in a mouse asthma model. *Ecotoxicol Environ Saf*. 2018;163:356–64.
14. Kuzmich NN, Sivak KV, Chubarev VN, Porozov YB, Savateeva-Lyubimova TN, Peri F. TLR4 signaling pathway modulators as potential therapeutics in inflammation and sepsis. *Vaccines (Basel)*. 2017;5(4):34.
15. Groeben H, Mitzner W, Brown RH. Effects of the alpha2-adrenoceptor agonist dexmedetomidine on bronchoconstriction in dogs. *Anesthesiology*. 2004;100(2):359–63.
16. Kim E, Kim HC, Lee S, Ryu HG, Park YH, Kim J. Dexmedetomidine confers neuroprotection against transient global cerebral ischemia/reperfusion injury in rats by inhibiting inflammation through inactivation of the TLR-4/NF- $\kappa$ B pathway. *Neurosci Lett*. 2017;649:20–7.
17. Takasaki Y, Kido T, Semba K. Dexmedetomidine facilitates induction of noninvasive positive pressure ventilation for acute respiratory failure in patients with severe asthma. *J Anesth*. 2009;23:147–50.
18. Lee JA, Rowen DW, Rose DD. Bronchial thermoplasty: A novel treatment for severe asthma requiring monitored anesthesia care. *AANA J*. 2011;79(6):480–3.
19. Lee SH, Kim N, Lee CY, Ban MG, Oh YJ. Effects of dexmedetomidine on oxygenation and lung mechanics in patients with moderate chronic obstructive pulmonary disease undergoing lung cancer surgery: a randomised double-blinded trial. *Eur J Anaesthesiol*. 2016;33(4):275–82.
20. Trikha A, Sadhasivam S, Saxena A, Arora MK, Deo SV. Thoracic epidural anesthesia for modified radical mastectomy in a patient with cryptogenic fibrosing alveolitis: a case report. *J Clin Anesth*. 2000;12(1):75–9.
21. Sundarathiti P, Pasutharnchat K, Kongdan Y, Suranutkarin PE. Thoracic epidural anesthesia (TEA) with 0.2% ropivacaine in combination with ipsilateral brachial plexus block (BPB) for modified radical mastectomy (MRM). *J Med Assoc Thai*. 2005;88(4):513–20.
22. Doss NW, Ipe J, Crimi T, Rajpal S, Cohen S, Fogler RJ, et al. Continuous thoracic epidural anesthesia with 0.2% ropivacaine versus general anesthesia for perioperative management of modified radical mastectomy. *Anesth Analg*. 2001;92(6):1552–7.

### Author biography

**Shripad Mahadik**, Consultant Anaesthesiologist

**Sushmitha K**, Senior Resident

**Deepak Phalgune**, Research Consultant  <https://orcid.org/0000-0003-4225-8010>

**Cite this article:** Mahadik S, Sushmitha K, Phalgune D. Combined thoracic epidural anaesthesia and interscalene brachial plexus block for modified radical mastectomy in a high-risk patient. *Indian J Clin Anaesth* 2023;10(4):390-393.