

“Anaesthetic Management of Faciomaxillary Injury – A Retrospective Study”

Seema Partani^{1,*}, Rakesh Kushwaha², Rajnindra Sharma³

^{1,2,3}Associate Professor, Geetanjali Medical College & Hospital, Rajasthan

*Corresponding Author:

Email: partaniseema@yahoo.in

Abstract

In this era of modern scientific advancement where automobile industries are reaching new heights and roads are jammed-up with all types of vehicles; accidents form a bulk of cases admitted to trauma ward. Majority of these cases have fascio-maxillary injuries where a proper airway assessment is the most important part of treatment.

In this content a retrospective study was done analyzing the case records of sixty patient with fascio-maxillary injuries admitted to our institute over a period of six months. The aim of this study was to find out the difficulties found during management. Majority of patients were in age group of 20-30 yrs and ten patients had some degree of airway compromised and five had associated head injuries. Out of these ten compromised airway, five were managed with change of position, oral suction & use of oropharyngeal airway; while four needed endotracheal intubation in casualty (Fig. 1) and only one required tracheostomy in casualty. 20 patients were intubated via nasal route. Blood transfusion was done for three patients.

Keywords: Maxillofacial injuries, Nasal intubation, Tracheostomy, Retromolar intubation, Difficult airway, Anaesthetic management, Rapid sequence intubation, Awake intubation.

Access this article online	
Quick Response Code:	Website: www.innovativepublication.com
	DOI: 10.5958/2394-4994.2016.00052.4

Introduction

Maxillofacial injuries are reaching new heights as a result of high velocity trauma arising from road traffic accidents, sports injuries, falls and gunshot wounds, that may lead to massive haemorrhage and maxillofacial injuries along with injury of vital organs. In these patients respiratory obstruction is a major threat with injury to lower jaw, panfacial or laryngeal trauma, mucosal edema. They result in problem of airway management^{1,2}.

The management team must have high index of suspicion **such as airway compromise, difficult intubation, injury to C spine, head injury; postop airway issues, massive oropharyngeal bleeding, foreign bodies in mouth, blunt** chest trauma, pelvic and long bone injury. Any delay in pre-hospital care may lead to morbidity and mortality.

Patient and Method

Udaipur (Rajasthan) is a tourist place on global map where, there are increasing numbers of vehicle, as well as road traffic accidents. In this context a retrospective study was done analyzing the case records over a six month period, in which sixty patients with fascio-maxillary injuries were managed in our institute.

When patient reached casualty a complete physical examination was done (from head to toe) and on suspicion neck x-ray or CT scan was also done to rule out cervical spine injury. As per need other investigations, blood grouping and cross match were also ordered.

The aim of this study was to find out demography, type of injuries, difficulties faced during anaesthesia and management.

Result

Majority of patients (80%) were in 20-30 yrs of age with male predominance (male 50; female 10). 93% injuries were because of road traffic accidents. A compromised airway was present in ten patients; Out of ten airway compromised patients five were managed with change of position, proper suctioning and insertion of oropharyngeal airways while four needed immediate intubation. Only one patient required tracheostomy prior to anaesthesia (Table 1). Three patients had profuse bleeding and required blood transfusion. One patient who had fractured mandible along with blunt trauma abdomen & right pneumothorax was operated in emergency for splenectomy after putting an ICTD. Orthopedic injury was present in six patients. Five patients had associated head injury (Refer Table 2)

15 patients had maxillary injury, and Lefort III fracture was present in three cases (Refer Table 3).

After stabilizing the general condition of all the patients, airway was assessed for mouth opening and condition of the oral cavity. Routine monitoring was done in the form of pulse oximetry, NIBP and ECG on arrival in operation theatre. An 18G IV cannula was inserted.

In emergency surgery every patient was taken under suspicion of full stomach. Inj Omeprazole and inj. metoclopramide was given.

Patients were premedicated with Inj glycopyrrolate 0.2 mg and Inj Tramadol 100mg IV. After Preoxygenation general anaesthesia was given. Out of 60 patients, 24 patients were operated in emergency, in which rapid sequence induction was done for 15 patients (as had history of full stomach), while five were already intubated in casualty (including one tracheostomy). (Refer Table 2).

Only five patients had vomiting in pre-operative period. Cervical spine injury was not found in any case and no patient had unconsciousness. Four patients needed blood transfusion. All patients had soft tissue

edema because of injury. (Refer Picture of one patient- Fig. 1a & b).

Overall in 20 patients nasal intubation was done. One case had frontobasal fracture in which first a Ryle's tube was inserted through nasal route, when the attempt was successful a cuffed endotracheal tube was passed over it easily.

In two patient retromolar intubation was done while in one case submental intubation was done. Saline soaked oropharyngeal packing was done in all patients.

After surgery all patients were able to extubate on table except two patients who required ventilator therapy and were successfully extubated within 24 hours. Postoperative complications were not significant. All patient received inj. diclofenac sodium intravenously for postoperative pain relief.

Table 1: Preoperative status

A. Airway not compromised	50 patient
B. Compromised airway	10 patient
a. Postural adjustment & oral airway insertion	(5)
b. Immediate endotracheal intubation (four).	(4)
c. Tracheostomy required	(1)

Table 2 Details of Injury

Injury	Patient number
Facial Injury:	
a. fractured mandible	17 (30%)
b. fractured nasal bone	15 (25%)
c. fractured maxilla	8 (13.3%)
d. fractured zygoma	3 (5%)
e. fractured mandible + maxilla	4 (6.6%)
f. Panfacial	3 (5%)
g. Split facial wound	10(16.6%)
Other concomitant injury:	
a. Head injury	5
b. Chest injury	3
c. Orthopedic injury	6
d. Blunt trauma abdomen	1
Mode of injury:	
a. Road traffic accident	54
b. Sharp weapon	4
c. Fall from height	2

Table 3: Injury distribution according to Le Fort

Le Fort I	Le Fort II	Le Fort III	Mixed
2	4	3	6

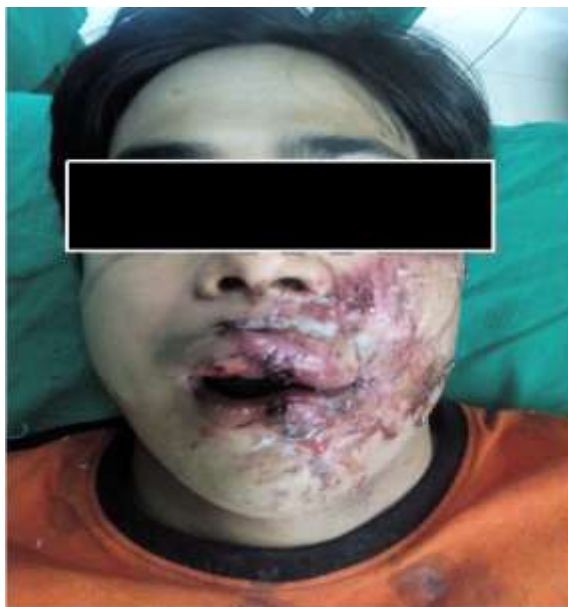

Fig. 1a: Patient having fracture mandible (Scan below Fig. 2b)

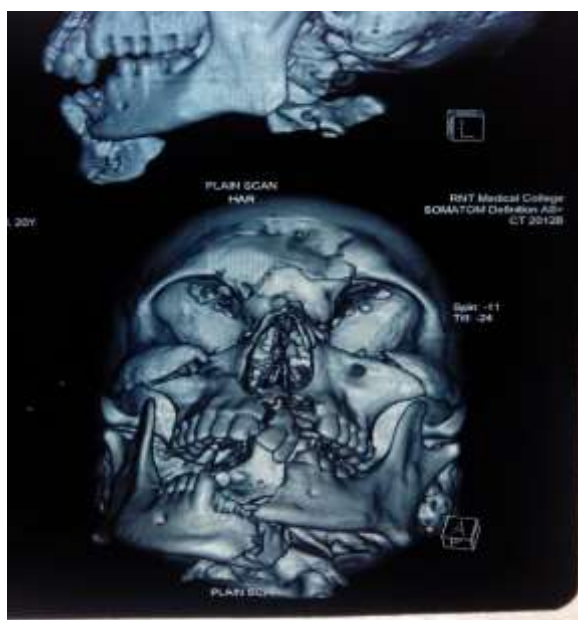


Fig. 1b: Scan of above patient

Discussion

Maxillofacial injury patients need special attention as these injuries are with or without head injury, cervical spine fracture, thoracic injury or polytrauma. All patients need care by a specialized person or team. These patients need early airway evaluation and control, to decrease morbidity and mortality.

When these faciomaxillary injury patients are present in emergency department in sitting or prone position in which the airway is maintained, they must be left in that position until they proceed for anesthetic induction. Trauma patients are always considered as full stomach and are at risk for aspiration during anesthesia, so we must take prophylaxis/preventive measures like

use of prokinetic drugs, sallick maneuver, and rapid sequence induction³.

Mallampatti classification may not be accurate in these patients because of tissue edema, disrupted anatomy, muscle spasm, pain on jaw movement and airway edema.

Nasal intubation is main stay in these patients to check dental occlusion for proper reduction and fixation of fractured bone and surgical access^{1,4}. When there is contraindication of nasal intubation in fracture of base of skull, pan facial trauma or displaced bone obliterating the nasal passage, retromolar intubation can be done. If required surgery can be facilitated with submental intubation⁵.

If available video laryngoscope or flexible fiberoptic intubation is advantageous in these patients. Flexible fiberoptic intubation is preferred in anticipated difficult airway preferably undergoing elective procedure. Surgical airway is reserved for emergencies because of failed intubation or severe injury^{6,7} for this we must observe patients and whenever we are not able to maintain oxygen saturation by airway maneuver and oral suctioning, we should use supraglottic devices like I-Gel/LMA/Intubation. If it fails or is not possible then surgical airway (tracheostomy) and ventilation should be maintained.

While performing intubation, one must have a look in the oral cavity to remove fragment of bone, loose broken teeth, clot, and debris to avoid chances of foreign body airway⁸. Throat pack should be removed at the end of surgery. Extubation should be planned according to patient. The decision to extubate the trachea is always a clinical judgment. If difficult airway is anticipated then extubation can be delayed or it should be with tube exchanger/airway catheter⁹, so that the patient can be ventilated/reintubated (if required)⁶. When in doubt do not take it out. Extubate when fully conscious⁸. In case of associated rib injury or upper abdominal injury/surgery, patient must keep on supportive elective ventilation along with good opiate analgesic/ epidural analgesic/intercostals n. block.

Conclusion

Anaesthetic management of a patient with fascio maxillary trauma is a challenge as in these patient airway is compromised. It involves vital and non-vital organs, looks ghastly, may lead to massive hemorrhage and is potentially life threatening. Problems faced as anaesthesiologist include identifying facial, laryngeal, pharyngeal structures; sharing of same field by surgeon and application of face mask to achieve a leak proof seal. Good assistance and difficult airway cart is required in emergency. Clear any blood clot and mucus from oral cavity and nose, remove foreign body (if present) and control tongue position. These patient must be treated as full stomach, so they must receive inj metoclopramide and rapid sequence induction should be done to prevent aspiration. When patient has undergone major surgery or difficult intubation, extubation should be done carefully (on airway exchange catheter).

Reference

1. Saraswat V. Airway management in Maxillofacial Trauma: A retrospective review of 127 cases. *Indian J. Anaesth.* 2008;52:311-16.
2. Gruen RL, Jurkovich GJ, McIntyre LK, Foy HM, Maier RV. Pattern of errors contributing to trauma Mortality lessons learned from 2594 deaths. *Ann Surg* 2006;244:371-80.
3. Dutton RP, Mccum M, Grisson TE. Anesthesia for trauma. In Text book "Miller RD. Miller's Anesthesia, 7th Edition (International edition). Churchill Livingstone Elsevier. Year 2010. Philadelphia. P.2283-2311.

4. Lee SS, Huang SH, Wu SH, Sun IF, Chu KS, Lai CS et al. A review of intraoperative airway management for mid face facial bone fracture patients. *Ann Plast surg.* 2009;63:162-6.
5. Altamir FH. The submental route for endotracheal intubation. A New Technique *Journal of maxillofacial Surg.* 1986;14:64-5.
6. Walls RM. Airway management. *Emerg Med Clin North Am.* 1993;11:53-60.
7. Cicala RS, Kudsk KA, Butts A et al. Initial evaluation and management of upper airway injury in trauma patients. *J clin Anesth* 1991;3:91-8
8. Shearer VE, Gardner J, Murphy MT. Perioperative anesthetic management of maxillofacial trauma including ophthalmic injuries. *Anesthesiology clinics of North America* 1999;17:141-52.
9. Henderson J. Airway Management. In Text book "Miller RD. Miller's Anesthesia". 7th Edition. Churchill Livingstone Elsevier. Year 2010. Philadelphia. P. 1601-3.