



## Case Report

# Iatrogenic injury of aortic valve leaflet during mitral valve replacement: A transesophageal echocardiographic finding

Shailendra Singh <sup>1,\*</sup>

<sup>1</sup>All India Institute of Medical Sciences, New Delhi, India



## ARTICLE INFO

### Article history:

Received 20-09-2022

Accepted 28-12-2022

Available online 05-06-2023

### Keywords:

Aortic regurgitation

Transesophageal echocardiography

Left coronary cusp

Non-coronary cusp

Cardiopulmonary bypass

## ABSTRACT

Iatrogenic aortic valve injury during non-aortic cardiac surgery is an infrequent complication. Iatrogenic aortic regurgitation (AR) has been reported after mitral valve repair, aortic valve repair, septal myomectomy, closure of the ventricular septal defect, and atrial septal defect repair. Various causes have been reported for AR after non-aortic cardiac surgery. Perforation of the aortic valve leaflet is a common cause of AR. Other causes of AR are leaflet tension and leaflet retraction due to inadvertent suture placement. A few previous case reports have presented severe AR as a complication of iatrogenic involvement of aortic valve leaflet during MV surgery. We report a case of severe AR and severe aortic stenosis occurring immediately after mitral valve replacement. This was diagnosed intraoperatively by Transesophageal echocardiography (TEE) and aortic valve replacement was done.

This is an Open Access (OA) journal, and articles are distributed under the terms of the [Creative Commons Attribution-NonCommercial-ShareAlike 4.0 License](https://creativecommons.org/licenses/by-nc-sa/4.0/), which allows others to remix, tweak, and build upon the work non-commercially, as long as appropriate credit is given and the new creations are licensed under the identical terms.

For reprints contact: [reprint@ipinnovative.com](mailto:reprint@ipinnovative.com)

## 1. Introduction

Iatrogenic valvular insufficiency has been reported undergoing various cardiac procedures such as leaflet entrapment or valve perforation. The aortic valve (AV) appears to be more prone to such potential complications because of its central location and proximity of the individual cusps to various cardiac structures. However, due to high-resolution TEE, it has been proven that we have extra diagnostic benefits in surgical procedures for valvular heart disease. The main advantage of the method in this point is the rapid detection of morphological pathology of the valves. TEE is the modality of choice in the detection and measurement of vegetation and abscesses in infective endocarditis. The transesophageal approach especially in combination with color-doppler flow imaging is superior to the transthoracic method if we want to detect any abscesses or any injury secondary to complications like

communication to adjacent structures or implication of the mitral valve.

## 2. Case Report

A 27 years old man presented to our center with a diagnosed case of mitral stenosis of rheumatic origin with a history of closed mitral commissurotomy in 1999. For the last 5 years, he was having a progressive increase in dyspnea on exertion and palpitation.

Trans thoracic echocardiography revealed thickened calcific and doming anterior mitral leaflet. The Mitral valve area was 1.2 cm<sup>2</sup>. The patient was diagnosed to have severe mitral regurgitation. The mitral subvalvular apparatus was severely deformed. The biventricular function was good.

The patient was posted for mitral valve replacement. Anesthetic induction and conduction of cardiopulmonary bypass were uneventful.

The mitral valve was replaced with a 29mm Carpentier Edwards Perimount (Edwards life sciences LLC, Irvine,

\* Corresponding author.

E-mail address: [drssingh2016@gmail.com](mailto:drssingh2016@gmail.com) (S. Singh).

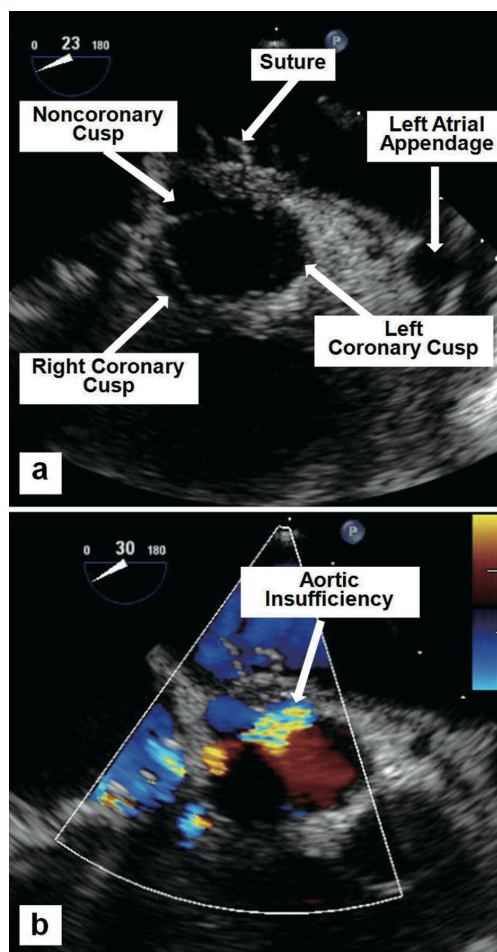
USA) bioprosthetic valve and subtotal chordal preservation was done.

After mitral valve implantation, the patient was weaned off cardiopulmonary bypass (CPB) but despite high inotropic support systemic pressure was low. Visually the right ventricular contraction was good but the lateral left ventricular contraction was very poor. Since the patient was hemodynamically unstable and required stepping up inotropic support, a TEE Probe (Philips iE 33) was inserted.

TEE revealed a normally functioning prosthetic mitral valve but there was severely impaired left ventricle function. On further examination, aortic valve leaflet motion was restrictive in both mid esophageal short axis view as well as in long axis view. Color Doppler across the aortic valve in mid-esophageal long axis view showed turbulence during systole and significant eccentric aortic regurgitation in diastole. In the mid esophageal short axis view, a tear in the left coronary cusp (LCC) was apparent along with the restricted motion of the non-coronary cusp (NCC), LCC, and right coronary cusp (RCC). In deep Trans gastric view, the peak pressure gradient across the aortic valve was 35mmHg with a corresponding systolic systemic pressure of 60 mmHg.

Based on these TEE findings CPB was reinstated. After arotomy, three sutures could be seen passing through the aortic valve leaflet. One suture crossed the commissure between the NCC and LCC. Another suture passed through the LCC and RCC at the commissural level. The third suture passed through the LCC resulting in its tear. Involvement of the commissures between NCC, LCC, and LCC, RCC resulting in restricted motion of all the three leaflets during systole. The aortic valve leaflets were damaged beyond repair and the aortic valve had to be replaced with a 19-size Carpentier Edwards paramount bioprosthetic valve (Edwards Lifesciences LLC, Irvine, USA).

Post aortic valve replacement the patients could be weaned from CPB but with high inotropic support. The patient's trachea was extubated after 2 days of mechanical ventilation. However, after one day of spontaneous ventilation patient become dyspneic and had to be reintubated. Transthoracic echocardiography revealed severe LV dysfunction with an ejection fraction of 15%. Milrinone was added to the earlier inotropic support of dopamine, dobutamine, and adrenaline. Considering the poor LV performance and the need for prolonged ventilation, a tracheostomy was performed on the 7<sup>th</sup> postoperative day. On the 8<sup>th</sup> day of tracheostomy, ventilatory support was removed because of improving LV function and decreased need for inotropic support. The tracheostomy tube was removed on the 17<sup>th</sup> postoperative day. On the 20<sup>th</sup> postoperative day, the patient was discharged with a left ventricular ejection fraction of 45%.



**Fig. 1:** Mid-esophageal TEE images showing a suture tethering the non-coronary cusp (a), which was resulting moderate-to-severe Aortic insufficiency by color flow Doppler (b)

### 3. Discussion

Suture-related injury to the aortic valve should always be considered and should be excluded when surgical corrections of adjacent cardiac structures are performed. During mitral surgery, great care is required when suturing at the base of the anterior leaflet.

So, it is a well-known fact that patients undergoing mitral valve repair/replacement for severe mitral regurgitation are prone to LV dysfunction post-surgery, especially when the LV function is impaired pre-surgery. In such cases, the distinction between primary LV dysfunction and other causes resulting in secondary LV dysfunction has to be made.

TEE can be used as an important intraoperative tool to find out the reason for the difficulty in weaning from CPB despite adequate valve surgery and optimal inotropic support. TEE has been notified as a Class IIa recommendation while doing mitral valve replacement. It also allows the detection of technical problems such as

paravalvular regurgitation, abnormal valve leaflet motion, or tethering of a cusp of the aortic valve with a suture placed in the mitral annulus.

In our case, we at first attributed postoperative LV dysfunction to pre-surgery. Replacement of a regurgitant valve with a competent valve suddenly imposes a greater amount of afterload on the left ventricle and predisposes it to acute dysfunction. But the hemodynamics of the patient did not improve even with high inotropic support. At this point, one of the following possibilities could have been present. The prosthetic valve malfunctions, incorporation of the left circumflex coronary artery, or iatrogenic involvement of the aortic valve. There was no change in the ECG which could suggest intraoperative entrapment of the LCX artery. TEE as a rescue tool helped us to find out the exact cause of such an acute LV dysfunction.

The LCC and the NCC are likely to get damaged during mitral valve repair/replacement. These cusps are at risk during suture placement in the anterior portion of the mitral annulus. Deeper suture bites in the posterior annulus increase the risk of injury to the left circumflex coronary artery. This can also result in severe LV dysfunction after mitral valve surgery.

Hill et al<sup>1</sup> have reported 6 cases of aortic regurgitation caused by leaflet perforation which was diagnosed later by transthoracic echocardiography. All 6 patients had undergone non-aortic cardiac surgery earlier. Repeat operation for the aortic valve was performed in 5 patients.

Ducharme et al<sup>2</sup> reported severe AR immediately after the insertion of a mitral annuloplasty ring. AR was found to be due to LCC retraction as a result of infoldings of the corresponding aortic wall. No suture could be found passing through the aortic leaflet. The tension created by the ring was thought to be the probable cause for leaflet retraction. Releasing 3 sutures on the ring resulted in the correction of the problem.

Rother et al<sup>3</sup> reported that a 46-year-old man who, after elective MV repair for severe MR used a Carpentier-Edwards annuloplasty ring, which was found to have a non-mobile left coronary cusp of the Aortic Valve during intraoperative TEE, causing moderate AI.

Mehta et al<sup>4</sup> also reported a case of Iatrogenic aortic incompetence after mitral valve replacement.

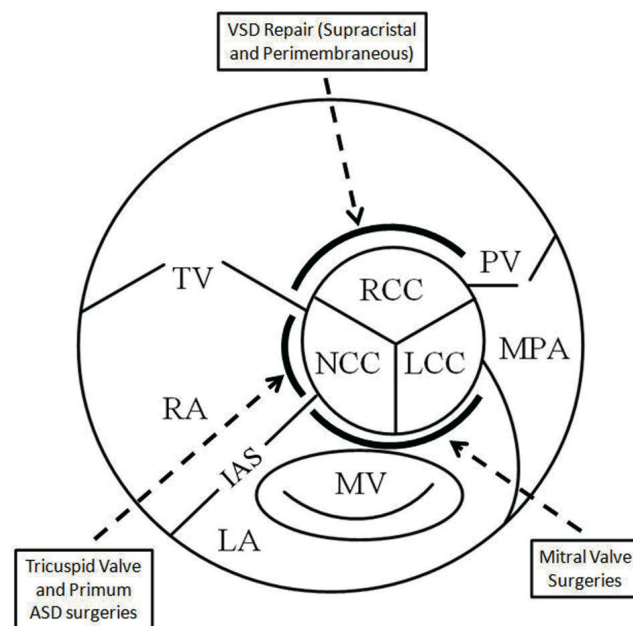
Dogan et al<sup>5</sup> reported one case of iatrogenic valvular perforation following valve replacement surgery involving the aortic and MVs. That case was an MV replacement on a 30-year-old man due to rheumatic heart disease 10 years earlier, he was found to have a perforation of the non-coronary cusp of his AV resulting in mild AI.

Koh and Gandhi<sup>6</sup> reported a case of mechanical tilting disk aortic prosthesis malfunction during MV replacement for rheumatic mitral stenosis in a 50-year-old man. In this case, traditional mid-esophageal TEE views were not helpful due to excess shadowing over the aortic prosthesis

from the newly placed MV prosthesis.

Woo et al<sup>7</sup> reported a 22-year-old woman with mild to moderate AI due to AV right coronary cusp perforation detected 15 years following simple membranous ventricular septal defect (VSD) repair, in the absence of any evidence of endocarditis.

In our case, 3 sutures had passed across the aortic leaflet. One suture had passed through the NCC & LCC commissure and another through the LCC & RCC. This is the effect that resulted in LCC being fused to NCC & RCC. Because of involvement at the commissures, the NCC & RCC had a restricted opening resulting in a gradient across the aortic valve. The peak systolic gradient was only 35mmHg in presence of severe LV dysfunction with systolic pressure of 60 mmHg. This gradient would have become significant if there was no LV dysfunction. The suture, which passed across the LCC, resulted in the perforation. This was the site of severe eccentric aortic insufficiency. TEE helped us to find out the cause of poor LV function after mitral valve replacement and the inability to sustain adequate hemodynamics despite stepped-up inotropic support.



**Fig. 2:** Schematic showing the central location of the aortic valve and the vulnerability of the cusps concerning adjacent surgery. RCC: Right coronary cusp; LCC: Left coronary cusp; NCC: Non-coronary cusp; TV: Tricuspid valve; MV: Mitral valve; PV: Pulmonic valve; MPA: Main pulmonary artery; LA: Left atrium; RA: Right atrium; IAS: Interatrial septum

#### 4. Conclusion

Besides confirming the adequacy of valvular surgery, Intraoperative TEE can help in confirming the possibility

of iatrogenic damage to the adjacent structures. Damage to AV cusps can result in varying degrees of insufficiency following different cardiac surgeries, is due to the location of the centrally placed Aortic Valve. Different techniques and modalities can be used to identify such events. Strict monitoring is recommended concerning such potentially life-threatening complications. Different multimodality imaging techniques should be employed during diagnosis so that early intervention can be implemented to prevent such incidences.

Finally, one should keep in mind that, during mitral surgery, every aortic cusp is at risk, so it makes preoperative TEE a mandatory procedure.

### 5. Source of Funding

None.


### 6. Conflict of Interest

None.

### References

- Hill AC, Bansal RC, Razzouk AJ, Liu M, Bailey LL, Gundry SR. Echocardiographic recognition of iatrogenic aortic valve perforation. *Ann Thorac Surg.* 1997;64(3):684–9.
- Ducharme A, Couvral JF, Dore A, Leclere Y, Tardif JC. Severe aortic regurgitation immediately after mitral valve Annuloplasty. *Ann Thorac Surg.* 1999;67(5):1487–9.
- Rother A, Smith B, Adams DH, Collard CD. TEE diagnosis of acute aortic valve insufficiency after mitral valve repair. *Anesth Analg.* 2000;91:499–500.
- Mehta AR, Hunsaker R. Iatrogenic aortic incompetence after mitral valve replacement. *J Cardiothorac Vasc Anesth.* 2007;21(2):276–8.
- Dogan M, Acikel S, Arslantas U, Cimen T, Yeter E. Inadvertent complication of prosthetic valve surgery: leaflet perforation. *Acta Medica (Hradec Kralove).* 2013;56(4):167–9.
- Koh TW, Gandhi S. Intraoperative transesophageal echocardiographic assessment of acute prosthetic aortic valve regurgitation after mitral valve replacement: the value of the deep transgastric long-axis view. *J Am Soc Echocardiogr.* 2002;15(12):1538–40.
- Woo JJ, Koh YY, Chang KS, Hong SP. A case of iatrogenic aortic valve leaflet perforation after the closure of a ventricular septal defect. *Int J Cardiovasc Imaging.* 2010;26(Suppl 1):169–72.

### Author biography

**Shailendra Singh**, Specialist (Anaesthesia)  <https://orcid.org/0000-0002-8454-2020>

**Cite this article:** Singh S. Iatrogenic injury of aortic valve leaflet during mitral valve replacement: A transesophageal echocardiographic finding. *Indian J Clin Anaesth* 2023;10(2):204-207.