



Case Report

Rare incidental presentation of urinary bladder paraganglioma and the anaesthetic challenges faced: A case report

Gopal Krishan Jalwal^{1,*}, Jyoti Kanwat¹, Brijesh Garg¹, Bhanupreet Kaur¹

¹Dept. of Anaesthesia, All India Institute of Medical Science, Bathinda, Punjab, India



ARTICLE INFO

Article history:

Received 09-01-2023

Accepted 21-02-2023

Available online 05-06-2023

Keywords:

Urinary bladder

Paraganglioma

Zellballen

Anaesthesia

ABSTRACT

Urinary bladder paraganglioma is an extra-adrenal pheochromocytoma. As it lacks specific symptoms and because of its rare occurrence, it presents incidentally while tumour handling. A forty-eight-year-old female who presented with nausea, vomiting, weight loss, pain abdomen and hematuria was diagnosed with a bladder mass. She was scheduled for transurethral resection of the bladder tumour. On tumour manipulation, it showed numerous fluctuations in heart rate and blood pressure, from where a differential diagnosis of urinary bladder paraganglioma was made. Histopathology revealed a Zellballen pattern of paraganglioma. This case was discharged successfully postoperatively. But if undiagnosed preoperatively, it can be a real challenge because of the fatal hypertensive crisis and life-threatening cardiopulmonary complications.

This is an Open Access (OA) journal, and articles are distributed under the terms of the [Creative Commons Attribution-NonCommercial-ShareAlike 4.0 License](https://creativecommons.org/licenses/by-nc-sa/4.0/), which allows others to remix, tweak, and build upon the work non-commercially, as long as appropriate credit is given and the new creations are licensed under the identical terms.

For reprints contact: reprint@ipinnovative.com

1. Introduction

Neoplasms arising from the chromaffin cells of the sympathetic nervous system are called pheochromocytomas. 70% of pheochromocytomas arise in the adrenal medulla. Extra-adrenal paragangliomas arise predominantly in the retroperitoneum, extending from the upper abdomen to the pelvic floor. 9.8% of extra-adrenal paragangliomas arise from neuroectodermal tissue within the urinary bladder. Common sites are trigone followed by dome and bilateral wall.^{1,2} Preoperative diagnosis of urinary bladder paraganglioma remains a challenge because of the lack of specific symptoms and rare occurrences. It may present with a classical triad of hematuria, hypertension and micturitional attacks typical of a pheochromocytoma syndrome (headache, anxiousness and pounding sensation). Herein, we report an unusual case of intraoperatively diagnosed pheochromocytoma and its

anaesthesia management after diagnosis.

2. Case Report

A 48-year-old female, 55 kg weight, was admitted to the urology department with a history of nausea, vomiting, weight loss and pain in the pelvic region for one month and complained of hematuria for 10 days. No history of headache, sweating, palpitations or fever was present. She had no other comorbidities. General physical examination was unremarkable. Baseline vitals showed blood pressure (BP) of 130/78 mmHg, and heart rate (HR) 80/min. All routine investigations were normal except urine analysis, which revealed a red blood cell count (RBC) of more than 100/high-power field (HPF). Abdominal ultrasound showed a large protruding mass (25*17*22 mm) arising from the right postero-lateral wall of the urinary bladder. Contrast Enhanced Computed tomography scan (CECT) showed a well-defined polypoidal lesion (27*20*20 mm) arising from the right posterolateral wall adjacent to the utero vesical

* Corresponding author.

E-mail address: gopaljalwal@gmail.com (G. K. Jalwal).

junction suggestive of malignant nature. Clinical findings and imaging reports reflected a urinary bladder tumour. The patient was scheduled for Transurethral resection of bladder tumour (TURBT). Pre anaesthetic check-up was done, and the patient was advised nil per oral. Spinal anaesthesia was planned.

The patient was shifted to the operating room (OR) on the day of surgery. Monitors were attached. Subarachnoid block (SAB) was given at the L3-4 level. It was supplemented with right obturator nerve block. Cystoscopy was done, and it showed a polypoidal tumour (Figure 1). On the manipulation of the tumour, the patient's blood pressure sharply rose from 120/80 mmHg to 220/110 mmHg with pulse rate of 120 beats/min. Surgery was halted and the patient regained the vitals to normal. The second attempt of tumour manipulation gave a similar response to BP and HR. Injection esmolol bolus 30 mg followed by injection labetalol (total 15 mg in graded doses of 5mg each) was given intravenously but it did not control blood pressure and heart rate except for a transient decrease. Surgery was halted again, and vitals regained normality. A differential diagnosis of bladder paraganglioma was made and a biopsy sample was sent to confirm the diagnosis. Spinal anaesthesia was then converted to general anaesthesia.

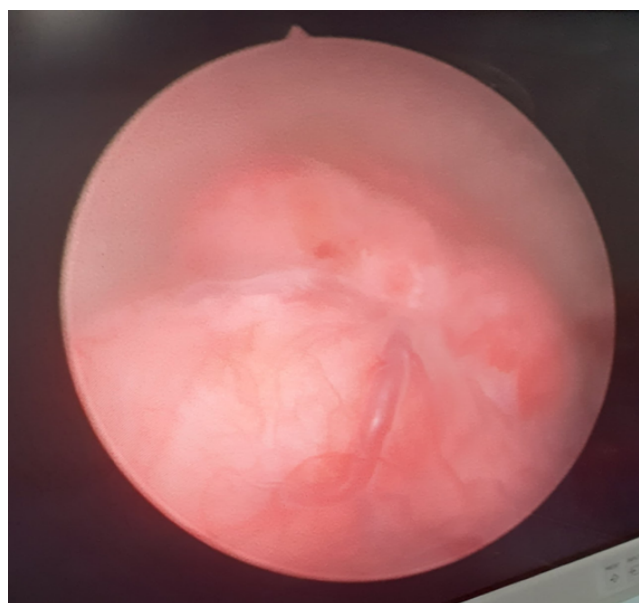


Fig. 1: Polypoidal tumor growth on cystoscopy

Before induction of general anaesthesia, arterial and central venous lines were established. Induction was done with fentanyl (3mg/kg), lidocaine (1.5mg/kg), propofol (2mg/kg) and rocuronium (1mg/kg). An endotracheal tube was inserted. The invasive arterial blood pressure (IABP) rose up significantly at the time of intubation. 30 mg bolus of esmolol was given to normalize the vitals. Anaesthesia was maintained with oxygen, nitrous oxide, sevoflurane

and an intermittent dose of vecuronium and fentanyl. Sodium Nitroprusside 1 mcg/kg/min infusion was started and titrated to maintain blood pressure within normal range. Significant blood pressure and heart rate fluctuations were noted during surgical exploration (Figure 2). Additionally, infusion of propofol 4mg/kg/h, fentanyl 1 mg/kg/h and Sevoflurane-2 MAC were administered to prevent extreme hypertensive episodes. A total of 5 litres of fluid was given to target central venous pressure (CVP) of 8 to 10 cm H₂O and correct volume depletion. Five minutes before complete resection of the tumour, Sodium Nitroprusside, propofol and fentanyl infusion were stopped and fluid was rushed. After complete resection of the tumour, the pressure of the patient dropped to 80/60 mmHg, following which noradrenaline infusion was started. The patient was shifted to the intensive care unit for further ventilation, where she was gradually weaned from the ventilator as well as vasopressor support. The patient was successfully extubated after 8 hours of shifting to the ICU.

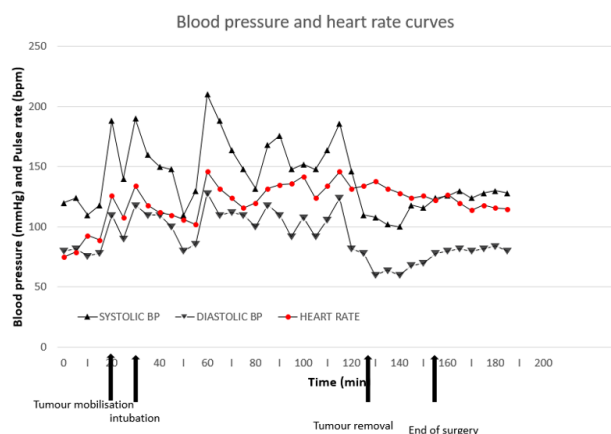


Fig. 2: Showing heart rate and invasive blood pressure fluctuations

Pathological examination revealed that the tumour was poorly circumscribed and intermingled with muscle bundles of the bladder wall and a typical zellballen pattern of paraganglioma was present. Few bizarre cells were also present. (Figure 3)

3. Discussion

Preoperative diagnostic tests for extra-adrenal pheochromocytoma include urinary catecholamines, Vanillylmandelic Acid (VMA), metanephrines, plasma catecholamines levels, and glucagon provocation tests to confirm catecholamine-producing tumours.³ Since ours was an incidental finding during the procedure, these tests could not be performed pre-operatively. Although rare, pheochromocytoma should be considered while handling bladder mass if blood pressure and heart rate shoot up significantly.

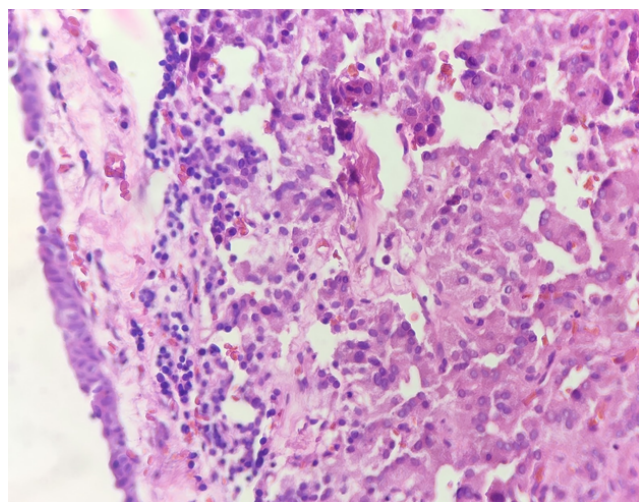


Fig. 3: Histopathological examination showing Zellballen pattern

Paragangliomas of the urinary bladder are histologically similar to adrenal pheochromocytoma. Tumours are poorly circumscribed and intermingled with adjacent muscle bundles of the bladder wall. The typical Zellballen pattern of growth i.e. cell clusters is the most common variant. Histopathological findings of our case were consistent with this pattern (Figure 3). Other patterns that are reported in the literature include trabecular, ribbon and sarcomatoid patterns.⁴

Pheochromocytomas represent significant management challenges to the anaesthesiologist. It has been postulated that anaesthesia induction, endotracheal intubation and tumour being moved might release a large number of catecholamines.⁵ From a hemodynamic perspective, few other clinical situations present a more complex and life-threatening situation - particularly when undiagnosed.⁶ The later situation may precipitate a hypertensive crisis, which can be life-threatening, with a published 80% mortality.⁷ Patients with pre-diagnosed bladder paraganglioma are advised to have adequate hydration, alpha and beta blockers to reduce the effect of excess circulating catecholamines. In our case, as it was diagnosed intraoperatively, so we faced a potentially fatal hypertensive crisis and hemodynamic instability. Due to excessive catecholamines and contracted intravascular volume it was not possible to manage in regional anaesthesia so spinal anaesthesia was converted to general anaesthesia and the effect of noxious stimuli was minimized by deep anaesthesia. Malignant hypertension was managed using nitroprusside infusion. Frequent communication with the surgeon during the resection of the tumour also helped us manage wide swings in blood pressure. Adequate fluid was given to counter the negative balance. Nitrous oxide, vecuronium, fentanyl, and Sevoflurane provided cardiovascular stability throughout the surgery. Severe hypotension was noticed on completion of tumour resection, resulting from the abrupt cessation of

catecholamines. Vasoactive drugs and noradrenaline were used to maintain normal blood pressure, but after a few hours of surgery, the patient was off inotropes.

4. Conclusion

To conclude, urinary bladder paraganglioma is a very rare tumour, and diagnosis remains challenging because of nonspecific symptoms. Undiagnosed paraganglioma can pose a very fatal hypertensive crisis and life-threatening cardiopulmonary complications. Well thought and carefully outlined a perioperative plan to manage fluctuations in blood pressure, heart rate and intravascular volume can lead to smooth recovery without any adverse events.

5. Source of Funding

None.


6. Conflict of Interest

None.


References

1. Schutz W, Vogel E. Pheochromocytoma of the urinary bladder—a case report and review of the literature. *Urol Int.* 1984;39(4):250–5.
2. Davaris P, Petraki K, Arvanitis D, Papacharalarnmpous N, Morakis A, Zorzos S. Urinary bladder paraganglioma (U.B.P.). *Pathol Res Pract.* 1986;181(1):101–6.
3. Bravo EL, Tarazi RC, Gifford RW, Stewart BH. Circulating and urinary catecholamines in pheochromocytoma. Diagnostic and pathophysiologic implications. *N Engl J Med.* 1979;301(13):682–6.
4. Kangi WY, Shen JT, Chai CY. Paraganglioma of urinary bladder: A case report. *Kaohsiung J Med Sci.* 2003;19(3):136–9.
5. Splinter WM, Milne B, Nickel C, Loomis C. Perioperative management for resection of a malignant non-chromaffin paraganglioma of bladder. *Can J Anaesth.* 1989;36(2):215–8.
6. Myklejord DJ. Undiagnosed pheochromocytoma: The anaesthesiologist nightmare. *Clin Med Res.* 2004;2(1):59–62.
7. Roizen MF, Schreider BD, Hassan S. Anaesthesiasia for patients with pheochromocytoma. *Anesthesiol Clin North Am.* 1987;5:269–75.

Author biography

Gopal Krishan Jalwal, Assistant Professor  <https://orcid.org/0000-0003-4890-7907>

Jyoti Kanwat, Assistant Professor  <https://orcid.org/0000-0002-5886-8238>

Brijesh Garg, Senior Resident  <https://orcid.org/0000-0001-9865-0471>

Bhanupreet Kaur, Senior Resident  <https://orcid.org/0000-0002-6702-3448>

Cite this article: Jalwal GK, Kanwat J, Garg B, Kaur B. Rare incidental presentation of urinary bladder paraganglioma and the anaesthetic challenges faced: A case report. *Indian J Clin Anaesth* 2023;10(2):201-203.