



Case Report

Perioperative management of post covid mucormycosis patient with dilated cardiomyopathy and atrial fibrillation posted for endoscopic debridement- A case report

Mitali Dilipkumar Agrawal^{1,*}, Ranjeeta M Tambey¹

¹Dept. of Anaesthesiology, Government Medical College, Nagpur, Maharashtra, India



ARTICLE INFO

Article history:

Received 02-08-2022

Accepted 22-08-2022

Available online 15-11-2022

Keywords:

Dilated cardiomyopathy

COVID 19

Mucormycosis

ABSTRACT

Anaesthesiologists being the frontline worker in COVID 19 pandemic, also contributed to the management of post-COVID sequelae like mucormycosis. Hereby reporting a case of successful anaesthetic management of a 60-year-old male with post COVID mucormycosis having an orbital extension, with co-morbidities like IHD, dilated cardiomyopathy, rate-controlled atrial fibrillation on regular treatment posted for emergency endoscopic debridement. Patient received amphotericin lipid complex. Preoperative 2D ECHO suggestive of ejection fraction of 23%, dilated LV, severe LV systolic dysfunction, mild MR, TR, AR, non-valvular atrial fibrillation, and no LA clot. While shifting the patient postoperatively, patient had a cardiorespiratory arrest, revived after 2 cycles of CPR and had atrial fibrillation with fast ventricular rate which was successfully cardioverted to normal sinus rhythm after synchronized cardioversion. Such cases always pose a challenge to anaesthesiologists as post covid systemic complications superadded with cardiac co-morbidities increase the overall risk.

This is an Open Access (OA) journal, and articles are distributed under the terms of the [Creative Commons Attribution-NonCommercial-ShareAlike 4.0 License](https://creativecommons.org/licenses/by-nc-sa/4.0/), which allows others to remix, tweak, and build upon the work non-commercially, as long as appropriate credit is given and the new creations are licensed under the identical terms.

For reprints contact: reprint@ipinnovative.com

1. Introduction

The incidence of rhino orbital mucormycosis in post-COVID patients is found to be 26.7%, with 54% overall mortality.¹ Mucormycosis is being observed in both people with COVID-19 and those recovering from the disease. Uncontrolled diabetes and overzealous steroid use comprise major factors aggravating the illness. Multiple factors like residual pulmonary dysfunction, myocardial dysfunction, adrenal suppression, difficult airway and adverse effects of amphotericin B, alter anaesthetic management in these patients. Dilated cardiomyopathy (DCMP) is the most common form of cardiomyopathy, incidence being 6/100000 population. It is defined as Echocardiography findings of presence of

1. Fractional myocardial shortening less than 25% and /or ejection fraction less than 45%.
2. Left ventricular end diastolic diameter greater than 117%.²

Hereby reporting successful perioperative management of a patient with post COVID mucormycosis having orbital extension associated with co-morbidities like IHD, dilated cardiomyopathy, rate-controlled atrial fibrillation on regular treatment posted for emergency endoscopic debridement.

2. Case Report

A 60-year-old male patient, weighing 71 kg, height 162 cm, BMI 27.05, presented with complaints of tingling sensation and pain over right side of face with nasal discharge since 5 days. A month ago, he suffered COVID 19 infection HRCT CTSS 8/25 and required minimal oxygen

* Corresponding author.

E-mail address: mitalidagrwal17@gmail.com (M. D. Agrawal).

and steroids for 15 days. Biopsy from nasal mucosa was s/o mucormycosis. Patient was non-diabetic, non-hypertensive. History of Ischemic Heart Disease with congestive cardiac failure 2 years back with atrial fibrillation on treatment since then. He underwent angiography at that time with no other intervention. Drug history shown in Table 1.

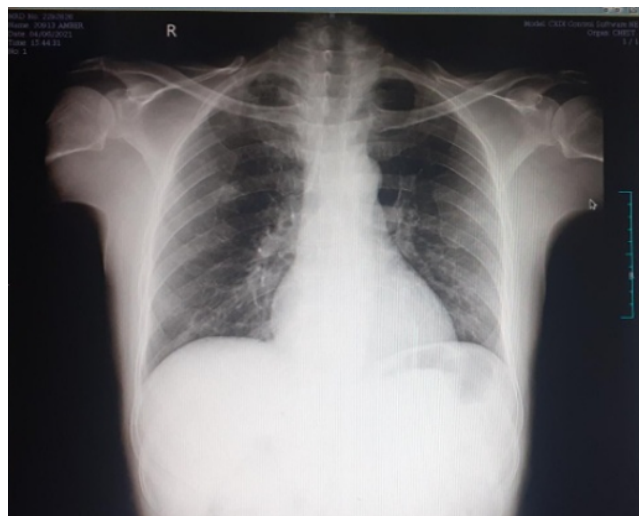

Fig. 1: Chest X-ray

Table 1: Drug history of patient

Drug history

1. Tab.Spironolactone 12.5 mg OD
2. Tab.Torsemide 5 mg OD
3. Tab.Atorvastatin 10 mg HS
4. Tab.Aspirin 75 mg OD
5. Tab.Clopidogrel 75 mg OD
6. Cap.Diltiazem CD 90mg OD

Fundus examination revealed bilateral grade I hypertensive retinopathy. Haematological investigations (CBC, LFT, KFT, TFT, serum electrolytes, coagulation profile, FBS, PPBS) were within normal limits. Chest X-ray was normal. An electrocardiogram showed atrial fibrillation. 2D ECHO was suggestive of ejection fraction 23%, dilated left ventricle, severe LV systolic dysfunction, mild tricuspid regurgitation, aortic regurgitation, non-valvular atrial fibrillation with no LA clot. MRI brain orbit revealed subtle edema in intraconal retrobulbar fat of right orbit, mucosal thickening in B/L maxillary sinuses s/o mucormycosis with no brain parenchyma involvement.

He was planned for endoscopic debridement on an emergency basis due to orbital involvement and pre anaesthetic checkup was done. Preoperatively, Pulse rate was 90-130/minute, irregular, good volume, and no apex pulse deficit. Blood pressure was 112/70 mm Hg in supine and 110/64 mm Hg in standing. Systemic examination and airway assessment were normal, effort tolerance being one

flight of stairs. High-risk informed consent was taken from relatives, and statins, rate-controlling medications were continued on the morning of surgery. Diuretics were stopped a day prior. Patient fasted overnight.

Patient was brought to OT on wheelchair. In the preoperative holding area, blood sugar was 104mg%. Triple lumen central venous line secured in right subclavian vein. Right radial artery cannulated with 22G arterial line under local anesthesia. Non-invasive monitors viz., automated blood pressure, pulse oximeter, electrocardiogram, and temperature probe along with invasive blood pressure monitor were attached. Baseline vital signs were recorded. General anaesthesia was planned. Premedication was done with inj.Pantoprazole 40 mg and inj. fentanyl 3mcg/kg. After preoxygenation with 100% O₂ for 3min, induced with inj. etomidate 0.4mg/kg and inj.vecuronium 0.1mg/kg. Airway secured with 8.5 mm ETT. Vitals were maintained during intubation. Anaesthesia was maintained with oxygen, nitrous oxide, sevoflurane and vecuronium boluses.

Patient had intraoperative supraventricular tachycardia (HR-180/min), managed with inj. Metoprolol 5 mg and Inj.Verapamil 5 mg. The surgery lasted 2 hours, estimated blood loss of 400 mL. Total intravenous fluid administered was 750 ml. Inj.Paracetamol 1g iv administered for analgesia. Patient reversed with inj. Neostigmine 0.05mg/kg and inj. Glycopyrrolate 8µg/kg and extubated 10 minutes after the end of surgery, maintaining vitals. After 15 minutes of extubation, patient had a cardiorespiratory arrest, 2 cycles of CPR given. Patient was revived as per ACLS protocol. It was followed by acute cardiogenic pulmonary edema. Patient was reintubated immediately and put on mechanical ventilation. Inj.Noradrenaline 8 µg/min started and shifted to PACU.

Postoperatively, patient developed AF with fast ventricular rate-Synchronized biphasic cardioversion of 100 J once escalated to 200 J twice consecutively administered. After sinus rhythm, patient was started on infusions of inj. Amiodarone, Inj.Furosemide along with noradrenaline support. All supports were weaned off after 60hours. Patient was extubated uneventfully after 72 hours. He was started on Inj.Enoxaparin 0.4mg BD with other medications. CT brain plain was normal. He was shifted to ward on day 6 and discharged on day 17 without any complications and neurological deficit. He received inj. Amphotericin B(lipid complex), broad-spectrum antibiotics and cardiac medications after serial electrolytes and KFT monitoring and corrections. Follow up 1 and 2 months after surgery were normal with no recurrence.

3. Discussion

DCMP is a syndrome characterized by cardiac enlargement and impaired systolic function of one or both ventricles. Anaesthetic goals are to

1. Maintain normovolemia.
2. Avoid overdose of drugs as circulation time is slow.
3. Avoid ventricular afterload.
4. Avoid sudden hypo tension especially when regional anaesthesia is used.²

Drugs like etomidate and narcotics having low cardiac depression potential are used frequently. Adequate oxygen-carrying capacity (cardiac output and hemoglobin) ensures good outcome.³ To improve cardiac output inotropes, vasopressors and left ventricular assist devices can be used. Skeletal muscle paralysis is to be provided by nondepolarizing muscle relaxant lacking significant cardiovascular effect. Estimation and correction of electrolytes done preoperatively. Because of poor cardiac ejection, ventricular enlargement, and elevated filling pressures, the fluid overload in the perioperative period could potentially deteriorate cardiac and pulmonary status.⁴

Normal ventricular rate atrial fibrillation is usually asymptomatic and do not pose any major anaesthetic problem. However, AF with rapid ventricular response can lead to significant cardiovascular complications, including hypotension, rate related myocardial ischemia, heart failure and pulmonary edema. Normal atrial activity accounts for at least 10% of ventricular filling, which can increase upto 40% at higher heart rates. The elderly population is more dependent on atrial filling due to reducing elasticity of the ventricles. Treatment aims at treating the cause. The fastest method of converting AF to sinus rhythm is by direct current cardioversion (DCCV). DCCV requires a defibrillator that delivers a synchronized (to minimize the R on T phenomenon) shock at appropriate energy, as well as adequate anesthesia for the patient.

Recent studies on post-COVID-19 patients have documented residual shortness of breath and deranged PFTs.⁵ Hence, a detailed respiratory evaluation in the preoperative period is necessary. For emergency surgery, risk stratification along with postoperative ventilatory management should be planned.⁶ Mucormycosis is an aggressive, life-threatening infection requiring prompt diagnosis and early treatment. Prognosis depends on the rapidity of diagnosis and treatment, site of infection and comorbidities. Rapid invasion of disease, inadequate availability of amphotericin B, urgency of debridement offer little time for optimization in the preoperative period. A detailed history of steroid use must be obtained as it may cause adrenal suppression leading to perioperative hypotension. So, a stress dose of corticosteroids should be considered in these patients, if other, more common causes of persistent hypotension are ruled out.⁷ Use of succinylcholine should be avoided in patients recovering from prolonged critical COVID-19 illness to prevent myopathy-induced hyperkalemia.⁸ Patients with Rhino Orbital Cerebral mucormycosis may present with both difficult mask ventilation as well as endotracheal intubation due to epiglottitis and supraglottic edema associated

with fungal debris. So, a difficult airway cart should be kept ready.⁹ Perioperative central venous cannulation should be considered especially in cardiac patients. Due to AmB-induced side effects like nephrotoxicity, hypotension, hypokalaemia, hypomagnesemia, arrhythmias, and fever, continuous invasive arterial pressure and arterial blood gas analysis should be considered for patients undergoing extensive surgery. Arrangement of postoperative ICU care is important due to the associated comorbidities and delayed recovery.

4. Conclusion

Dilated cardiomyopathy with atrial fibrillation should be optimized preoperatively for better outcomes for patients undergoing non-cardiac surgery. Mucormycosis with DCMP predisposes to increase chances of postoperative pulmonary complications. Decision of immediate extubation in such patients should be taken cautiously and not hurried. Synchronized cardioversion should not be withheld in patients with hemodynamic instability for the need of anticoagulation. This case emphasizes the importance of perioperative monitoring, optimization and PACU care for better outcomes in high-risk patients.

5. Source of Funding

None.


6. Conflict of Interest

None.

References

1. COVID-19-Associated Mucormycosis: Triple Threat of the Pandemic; 1993. Available from: <https://asm.org/Articles/2021/July/COVID-19-Associated-Mucormycosis-Triple-Threat-of>.
2. Stoelting RK, Dierdorf SF. Anaesthesia and Coexisting Disease. In: Stoelting RK, editor. *Cardiomyopathy*. New York: Churchill Livingstone; 1993. p. 97–102.
3. Sharma R, Francis DP, Pitt B. Hemoglobin predicts survival in patients with chronic heart failure: a sub study of the ELITE II trial. *Eur Heart J*. 2004;25(12):1021–28.
4. Ituk US, Habib AS, Polin CM, Allen TK. Anesthetic management and outcomes of parturients with dilated cardiomyopathy in an academic centre. *Can J Anaesth*. 2015;62(3):278–88.
5. Huang Y, Tan C, Wu J, Chen M, Wang Z, Luo L, et al. Impact of coronavirus disease 2019 on pulmonary function in early convalescence phase. *Respir Res*. 2020;21:163. doi:10.1186/s12931-020-01429-6.
6. Gupta KK, Singh A, Kalia A, Kandhola R. Anaesthetic considerations for post-COVID-19 mucormycosis surgery- A case report and review of literature. *Indian J Anaesth*. 2021;65(7):545–7.
7. Liu MM, Reidy AB, Saatee S, Collard CD. Perioperative steroid management. *Anesthesiology*. 2017;127:166–72.
8. Bagnato S, Boccagni C, Marino G, Prestandrea C, D'Agostino T, Rubino F. Critical illness myopathy after COVID-19. *Int J Infect Dis*. 2020;99:276–8.
9. Karaaslan E. Anesthetic management of rhinoorbitocerebral mucormycosis; Focus on challenges. *J Mycol Med*. 2019;29(3):219–22.

Author biography

Mitali Dilipkumar Agrawal, Junior Resident 3rd Year
 <https://orcid.org/0000-0002-0665-449X>

Ranjeeta M Tambey, Associate Professor

Cite this article: Agrawal MD, Tambey RM. Perioperative management of post covid mucormycosis patient with dilated cardiomyopathy and atrial fibrillation posted for endoscopic debridement- A case report. *Indian J Clin Anaesth* 2022;9(4):504-507.