

Content available at: <https://www.ipinnovative.com/open-access-journals>

Indian Journal of Clinical Anaesthesia

Journal homepage: www.ijca.in

Case Series

Tocilizumab as a breakthrough in the cytokine storm of COVID-19 pneumonia- Case series in the intensive care unit

Michell Gulabani^{1,*}, Pragma¹, Richa Chauhan¹, Ashok Kumar Saxena¹

¹Dept. of Anaesthesia, University College of Medical Sciences, New Delhi, India



ARTICLE INFO

Article history:

Received 31-05-2022

Accepted 18-06-2022

Available online 13-08-2022

Keywords:

Tocilizumab

Cytokine storm

Interleukin 6

COVID 19

ABSTRACT

Tocilizumab (TCZ) is a promising treatment for management of COVID-19 pneumonia amid many controversies linked to its potential benefit. The exact time for administration of the drug to avail maximum clinical benefit is still unclear. We present a case series in which three patients with severe COVID 19 (respiratory rate of more than 30/min, breathlessness and hypoxia with Spo₂<92% on room air) and without any pre-existing co-morbid conditions were administered Inj TCZ intravenously based on increasing levels of inflammatory markers (CRP and IL6), worsening dyspnea and radiographic evidence of COVID-19 deterioration. They were admitted in our Intensive care unit (ICU) nearly 7-10 after symptom onset. Their inflammatory markers were raised with CRP>75 mg/dl, IL-6 > 200 pg/ml and ABG depicted falling trend in Pao₂/Fio₂ ratio despite adequate ventilation. These patients received TCZ nearly 9 to 14 days of ICU stay after excluding secondary bacterial and fungal infections (sputum, urine and blood culture) as their inflammatory markers increased suddenly during the late phase of the disease. Their liver and kidney functions were acceptable and no neutropenia or thrombocytopenia was ensured. Their inflammatory markers improved significantly post intervention and they weaned from non-invasive ventilation, transferred from the intensive care unit to the ward and later discharged in 20-25 days from the hospital.

Therefore, we would like to emphasize consideration of TCZ in worsening critically ill COVID-19 patients as a pharmacological modality even during late phase of the disease as a means to improve oxygenation, avoiding mechanical ventilation and subsequent morbidity and mortality. COVID 19 is a dynamically evolving disease and new treatment modalities at the different stages of the disease may yield benefits in certain sub-groups of patients.

This is an Open Access (OA) journal, and articles are distributed under the terms of the [Creative Commons Attribution-NonCommercial-ShareAlike 4.0 License](https://creativecommons.org/licenses/by-nc-sa/4.0/), which allows others to remix, tweak, and build upon the work non-commercially, as long as appropriate credit is given and the new creations are licensed under the identical terms.

For reprints contact: reprint@ipinnovative.com

1. Introduction

COVID-19 pandemic is affecting millions of lives globally. Evidence shows biological therapy targeting cytokines improves clinical outcome in cytokine storm. Tocilizumab (TCZ) acts on interleukin 6 (IL-6) receptor and downregulates immune response which is the major cause of pathological damage to lungs in COVID-19.¹ Nevertheless, TCZ has been associated with controversies in its use in

moderate-severe COVID illness, including the timing of administration and its potential adverse effects. This case series highlights the fact that TCZ emerged as a therapeutic modality in patients in whom the conventional regimens did not show improvement. Despite utilizing all treatment modalities and managing the patients to the best of our efforts the clinical condition of these patients was showing a declining trend. Though TCZ is predominantly effective in the early phases of carefully selected cases of COVID-19 infection, it may also be useful to delay invasive mechanical ventilation in the later part of severe COVID-19 disease, if

* Corresponding author.

E-mail address: michellgulabani@gmail.com (M. Gulabani).

used judiciously.

2. Case Series

Patient 1: A 48 years COVID-19 positive female presented with fever, cough and breathlessness for four days. Her oxygen saturation (Spo₂) on room air was 89% and on non-rebreathing mask (NRBM) was 97%. Oxygen was continued by NRBM for three days in the ward, but her condition deteriorated, therefore was shifted to ICU on fourth day of admission. In ICU her SpO₂ was 77% on room air with respiratory distress, therefore Non-invasive ventilation (NIV) initiated and treatment as per institutional protocol for critically ill COVID-19 patients was given. Inflammatory markers on admission in ICU were IL6-7.80 pg/ml (Normal range = 0-43.5pg/ml), C-Reactive Protein (CRP)-17.45mg/L (Normal range=<10mg/L). Next few days her oxygen requirement, ventilatory parameters and ABG (Arterial Blood Gas) depicted clinical deterioration. Serial inflammatory markers increased from baseline values to IL6-300 pg/ml, CRP-81mg/dl by ninth day of ICU. We initiated institutional protocol for procuring Inj TCZ 400 mg and administered it intravenously on eleventh day of ICU. Subsequently, she improved clinically and her oxygen requirement decreased. Her inflammatory markers 24 hours post intervention were IL6-34 pg/ml, CRP-57 mg/dl and 72hrs later were IL6-19 pg/ml and CRP-39 mg/dl. Gradually she was weaned from NIV to facemask by twenty-fifth day of ICU.

Patient 2: A 52 years COVID-19 positive female presented with fever, cough for six days and breathlessness for one day. Her Spo₂ was 91% on room air and 97% oxygen supplementation by face mask. She was in ward for five days where her clinical course was declining, hence was shifted to ICU where NIV was initiated owing to her respiratory distress. Her baseline markers were IL6-26 pg/ml, CRP-3.8 mg/dl. On the 12th day of ICU her markers were: IL-6-81.6 pg/ml, CRP-100 mg/dl. Her ABG depicted impending respiratory failure warranting mechanical ventilation. Therefore, we administered Inj TCZ 400 mg intravenously on the 14th day of ICU. Within 24 hours, her oxygen requirement improved and her inflammatory markers 24 hours later were: IL-6-59.3 pg/ml, CRP-3.2 mg/dl. We were able to step down to minimal ventilatory support in eight days.

Patient 3: A 37 years COVID-19 positive male was directly shifted from emergency room to the ICU in view of falling Spo₂. He had fever, cough with expectoration for 6-7 days and breathlessness for 1-2 days. His Spo₂ was 82% on Room air and on NRBM was 96-97%. Occasionally NIV support was given owing to his respiratory discomfort. On ICU admission markers were IL-6-12 pg/ml, CRP-18 mg/dl. Repeat markers on 8th day of ICU were: IL-6-74.8 pg/ml, CRP-78 mg/dl. Thus, Inj TCZ 400 mg was considered apt and was given intravenously on 9th day of ICU. Following

which markers decreased to CRP-19 mg/dl, IL-6-37.8 pg/ml within 24 hours.

3. Discussion

IL-6 plays key role in host immune response resulting in diffuse alveolar damage and microvascular thrombosis leading to acute lung damage.² TCZ is a recombinant humanized monoclonal antibody against both soluble and membrane bound IL-6 receptor and improves the outcome in critically ill COVID-19 patients. Its use is advocated for the treatment of severe rheumatoid arthritis, systemic juvenile idiopathic arthritis, giant cell arteritis, and life-threatening cytokine release syndrome induced by chimeric antigen receptor T cell therapy.³

The recommended dose of TCZ is 4–8 mg/kg administered as a single 60- minute intravenous infusion every 4 weeks. The common side effects are headache, hypertension, rash, swelling and itching. The severe adverse effects being secondary bacterial, fungal infections, sepsis and severe hypersensitivity reactions. Its safety in pregnancy and lactation has not been established.⁴

According to the AIIMS/ICMR-COVID-19 National Task Force, TCZ may be considered in severe disease within 24 to 48 hours of ICU, with raised inflammatory markers(CRP/IL6) and no clinical improvement despite use of steroids provided they have no active bacterial, fungal or tubercular infection.⁵

Reiterating these guidelines, the Directorate General of Health Services, Government of India had approved the use of TCZ for critically ill patients who show no improvement in Spo₂ even after 24-48 hours of steroid administration having raised inflammatory markers (CRP>75mg/L).

The recovery trial, a multicentre, randomised, controlled, open-label platform, administered TCZ(within 1-5 days of hospitalization)to 2022 patients and who had severe COVID-19(oxygen saturation <92% on room air or requirement for supplemental oxygen), systemic inflammation (C-reactive protein ≥75 mg/L), and no clear evidence of an active infection other than SARS-CoV-2 and usual care to 2094 patients. They concluded TCZ improved clinical outcome, reduced mortality and increased the possibility of 28 day discharge with early use as chances of complicating bacterial infection are low during early phase of hospitalization.⁶

WHO (World Health Organisation) prequalifies Tocilizumab only for patients with severe disease. It should be given by a healthcare provider with adequate monitoring, oxygen, corticosteroids and other medications.⁷

Gupta S and Leaf DE⁸ in an editorial in The Lancet advocated the use of TCZ in severely ill COVID 19 patients, in accordance with the findings of the recovery trial.

Boregowda et al⁹ in a systematic review and meta analysis of 3641 patients with severe COVID 19 compared TCZ and standard of care group, concluded that the former

reduced mortality by 3.81%. The authors further suggested that the administration of tocilizumab at the beginning of the cytokine storm would be beneficial than starting it when the cytokine storm is uncontrollable. Nevertheless, its timing of administration continues to be ascertained. Moreover, in developing countries like ours, expensive treatment such as TCZ may be delayed over more economical options such as steroids.

In a systematic review and meta-analysis by Kotak S et al¹⁰ on the use of TCZ in patients of COVID 19, the TCZ group had lower mortality and lesser need for mechanical ventilation as compared to the control group denoting an improvement in oxygenation indices.

Raquel et al¹¹ conducted a study on 112 patients to compare efficacy of TCZ within ten days of symptom onset to injecting the drug from day 11. They concluded that TCZ had higher efficacy if administered after 10 days from symptom onset.

P Sinha et al¹² gave TCZ in 255 patients and concluded that optimal timing for administering TCZ is early during course of disease.

Christine A. Vu¹³ et administered TCZ in 60 patients where median time from hospital admission to receiving TCZ was two days and from symptom onset to administration was eight days. They concluded that TCZ may have a therapeutic role in treatment of early stages of COVID-19.

Capra et al¹⁴ conducted a retrospective cohort study and administered TCZ during the early stage of COVID-19 pneumonia that lead to suppression of the hyper immune response and decreased mortality.

Similarly Gupta S et al¹⁵ in a retrospective cohort among critically ill patients with COVID-19, found, the risk of in-hospital mortality was lower in patients treated with TCZ in the first 2 days of ICU admission compared with patients whose treatment did not include early use of TCZ. The patients who were admitted to ICU after 7 days of hospital admission were excluded, thus advocating the use of TCZ in the early phase of COVID illness.

Tleyjeh IM et al.¹⁶ in a systematic review on efficacy and safety of TCZ in COVID 19 patients did not find any adverse event or higher risk of infection with its use.

The role of TCZ in patients of COVID 19 has been questioned in a few studies, with regards to its early administration in the course of COVID 19. Chen CX et al.¹⁷ in a systematic review and meta analysis of 32 studies concluded that TCZ reduced the rate of death but not of surrogate end points like intensive care unit stay, invasive mechanical ventilation and duration of hospitalization. The COVID 19 patient group in this review was of heterogenous severity and many studies were observational, lacking a control group.

Stone JH et al.¹⁸ in a randomized controlled trial to test the safety and efficacy of TCZ in patients (242) of severe

COVID 19 with standard of care treatment and TCZ or placebo concluded that TCZ had no significant effect on the risk of intubation or death or on disease worsening. Despite this, patients on TCZ did not have any major adverse effects and had fewer serious infections than those with placebo.

Similarly, the role of TCZ in the early course of COVID 19 to prevent worsening of pneumonia was analyzed in a randomized control trial by Salvarani C et al¹⁹ who found no benefit in disease progression when compared with the standard of care treatment.

In another randomized controlled trial by Olivier Hermine et al²⁰ to determine if TCZ improved outcome in patients with moderate-severe COVID 19 concluded that TCZ reduced the risk of mechanical ventilation or death by 14th day of administration but no difference on day 28 mortality was found.

The above studies findings^{17–20} should be confirmed with a larger, placebo controlled randomized clinical trials with longer follow-up to evaluate possible applications of TCZ in different stages of the disease.

We administered TCZ in these three patients with severe COVID 19 based on increasing levels of inflammatory markers, worsening dyspnea and radiographic evidence of COVID-19 deterioration. All patients had severe disease with RR > 30/min, breathlessness and hypoxia (Spo₂ < 92% on room air) without any pre-existing co-morbid conditions. Their treatment included Inj methylprednisolone 62.5 mg bd, Inj enoxaparin 40 mg BD subcutaneously, Inj Remdesivir 200 mg stat followed by 100 mg OD for 4 days iv, antibiotics and supportive care. They were admitted in our ICU nearly 7-10 after symptom onset. Their inflammatory markers were raised with CRP > 75 mg/dl, IL-6 > 200 pg/ml and ABG depicted falling trend in Pao₂/Fio₂ ratio despite adequate ventilation.

These patients received TCZ nearly 9 to 14 days of ICU stay after excluding secondary bacterial and fungal infections (sputum, urine and blood culture) as their inflammatory markers increased suddenly during the late phase of the disease. Figures 1, 2 and 3. Their liver and kidney functions were acceptable and no neutropenia or thrombocytopenia was ensured. Their inflammatory markers improved significantly post intervention and they weaned from non-invasive ventilation, transferred from the intensive care unit to the ward and later discharged in 20-25 days from the hospital.

After intensive search of literature, the exact timing for TCZ administration could not be ascertained. Therefore, we would like to emphasize consideration of TCZ in worsening critically ill COVID-19 patients as a pharmacological modality even during late phase of the disease. COVID-19 in its clinical presentation, progression and response to therapeutic modalities is dynamically evolving and host immune response varies extensively, therefore interventional decisions need to be tailor made for

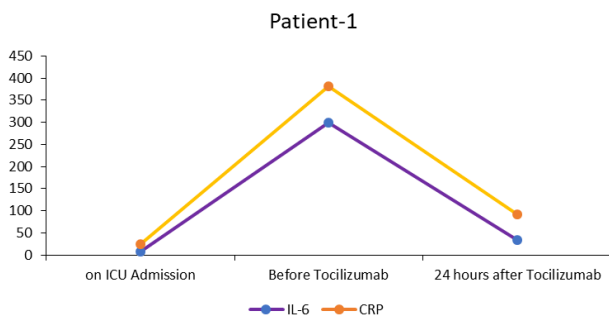


Fig. 1: Respective patients (1,2,3) denoting trends of the inflammatory markers

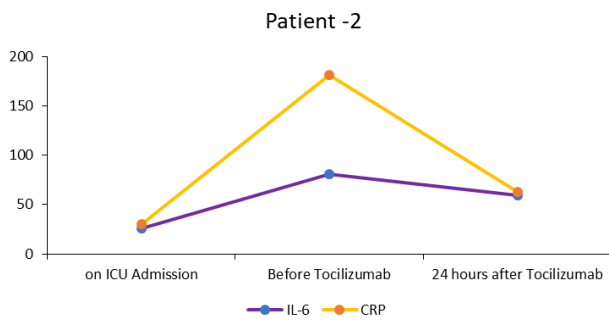


Fig. 2: Respective patients (1,2,3) denoting trends of the inflammatory markers

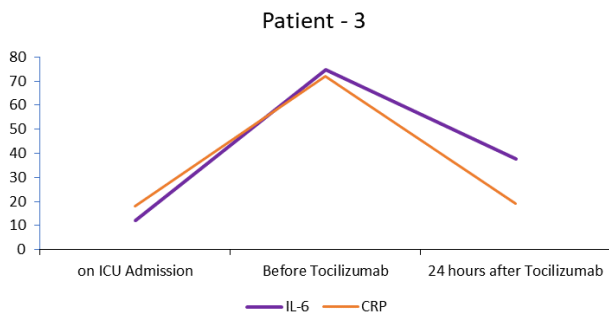


Fig. 3: Respective patients (1,2,3) denoting trends of the inflammatory markers

each patient.

Future studies are needed to help determine which group of patients derive the greatest benefit from the drug and whether combined therapy with corticosteroids or antiviral agents may further improve outcomes.

4. Source of Funding

None.

5. Conflict of Interest


The authors declare no conflict of interest.

References

- Salama C, Han J, Yau L, Reiss WG, Kramer B, Neidhart JD, et al. Tocilizumab in Patients Hospitalized with COVID-19 Pneumonia. *N Engl J Med.* 2021;384(1):20–30.
- Ye Q, Wang B, Mao J. The pathogenesis and treatment of the ‘Cytokine Storm’ in COVID-19. *J Infect.* 2020;80(6):607–13.
- Guaraldi G, Meschiari M, Cozzi-Lepri A, Milic J, Tonelli R, Menozzi M, et al. Tocilizumab in patients with severe COVID-19: a retrospective cohort study. *Lancet Rheumatol.* 2020;2(8):474–84.
- Samaee H, Mohsenzadegan M, Ala S, Maroufi SS, Moradimajid P. Tocilizumab for treatment patients with COVID-19: Recommended medication for novel disease. *Int Immunopharmacol.* 2020;89:107018.
- AIIMS/ICMR COVID-19 National Task Force/Joint Monitoring Group, Ministry of Health and Family Welfare, Government of India guidelines: Clinical Guidance for Management of Adult COVID-19 Patients;17th may 2021. Available from: https://www.icmr.gov.in/pdf/covid/techdoc/archive/COVID_Management_Algorithm_17052021.pdf.
- Recovery Collaborative Group. Tocilizumab in patients admitted to hospital with COVID-19 (Recovery): a randomised, controlled, open-label, platform trial. *Lancet.* 2021;397(10285):1637–45.
- Available from: <https://www.who.int/news/item/11-02-2022-who-qualifies-first-mono-clonal-antibody---tocilizumab-to-treat-covid-19>.
- Gupta S, Leaf DE. Tocilizumab in COVID-19: some clarity amid controversy. *Lancet.* 2021;397(10285):1599–1601.
- Boregowda U, Periseti A, Nanjappa A, Gajendran M, Kuttisridharan G, Goyal H. Addition of Tocilizumab to the Standard of Care Reduces Mortality in Severe COVID-19: A Systematic Review and Meta-Analysis. *Front Med (Lausanne).* 2020;7:586221.
- Kotak S, Khatri M, Malik M, Malik M, Hassan W, Amjad A, et al. Use of Tocilizumab in COVID-19: A Systematic Review and Meta-Analysis of Current Evidence. *Cureus.* 2009;12(10):10869.
- Diaz RM, García MAA, Muñoz FJT, Perez L, Gonzalez MM, Bermejo JAM, et al. Does timing matter on tocilizumab administration? Clinical, analytical and radiological outcomes in COVID-19. *Eur J Hosp Pharm.* 2021;doi:10.1136/ejpharm-2020-002669.
- Sinha P, Mostaghim A, Bielick CG, McLaughlin A, Hamer DH, Wetzler LM, et al. Sagar M; Boston Medical Center Covid-19 Treatment Panel. Early administration of interleukin-6 inhibitors for patients with severe COVID-19 disease is associated with decreased intubation, reduced mortality, and increased discharge. *Int J Infect Dis.* 2020;99:28–33.
- Vu CA, Deronde KJ, Vega AD, Maxam M, Holt G, Natori Y, et al. Effects of Tocilizumab in COVID-19 patients: a cohort study. *BMC Infect Dis.* 2020;20(1):964.
- Capra R, DeRossi N, Mattioli F, Romanelli G, Scarpazza C, Sormani MP, et al. Impact of low dose tocilizumab on mortality rate in patients with COVID-19 related pneumonia. *Eur J Intern Med.* 2020;76:31–5.
- Gupta S, Wang W, Hayek SS, Chan L, Mathews KS, Melamed ML, et al. Stop-COVID Investigators. Association Between Early Treatment With Tocilizumab and Mortality Among Critically Ill Patients With COVID-19. *JAMA Intern Med.* 2021;181(1):41–51.
- Tleyjeh IM, Kashour Z, Damlaj M, Riaz M, Tlayjeh H, Altannir M, et al. Efficacy and safety of tocilizumab in COVID-19 patients: a living systematic review and meta-analysis. *Clin Microbiol Infect.* 2021;27(2):215–27.
- Chen CX, Hu F, Wei J, Yuan LT, Wen TM, Gale RP, et al. Systematic review and meta-analysis of tocilizumab in persons with coronavirus disease-2019 (COVID-19). *Leukemia.* 2021;35(6):1661–70.
- Stone JH, Frigault MJ, Serling-Boyd NJ, Fernandes AD, Harvey L, Foulkes AS, et al. BACC Bay Tocilizumab Trial Investigators. Efficacy of Tocilizumab in Patients Hospitalized with Covid-19. *N Engl J Med.* 2020;383(24):2333–44.

19. Salvarani C, Dolci G, Massari M. Effect of Tocilizumab vs Standard Care on Clinical Worsening in Patients Hospitalized With COVID-19 Pneumonia: A Randomized Clinical Trial. *JAMA Intern Med.* 2021;181(1):24–31.
20. Hermine O, Mariette X, Tharaux P, Resche-Rigon M, Porcher R, Ravaud P, et al. Effect of Tocilizumab vs Usual Care in Adults Hospitalized With COVID-19 and Moderate or Severe Pneumonia: A Randomized Clinical Trial. *JAMA Intern Med.* 2021;181(1):32–40.

Author biography

Michell Gulabani, Assistant Professor  <https://orcid.org/0000-0001-7729-181X>

Pragya, Senior Resident  <https://orcid.org/0000-0003-0808-4301>

Richa Chauhan, Assistant Professor

Ashok Kumar Saxena, Professor

Cite this article: Gulabani M, Pragya, Chauhan R, Saxena AK. Tocilizumab as a breakthrough in the cytokine storm of COVID-19 pneumonia- Case series in the intensive care unit. *Indian J Clin Anaesth* 2022;9(3):382-386.