



## Case Series

## Pericapsular Nerve Group (PENG) block with bupivacaine for relieving pain during positioning for spinal anaesthesia in 4 patients during hip fracture surgery - A case series

Anita Sharma<sup>1,\*</sup>, Shelly Rana<sup>1</sup>, Aditi Ranaut<sup>1</sup>, Nidhi Thakur<sup>1</sup>

<sup>1</sup>Dept. of Anaesthesiology, Dr. R.P. Govt. Medical College, Kangra, Himachal Pradesh, India



## ARTICLE INFO

## Article history:

Received 25-12-2021

Accepted 12-01-2022

Available online 12-02-2022

## Keywords:

Bupivacaine

PENG block

Regional analgesia

Hip surgery

## ABSTRACT

Pericapsular nerve group (PENG) block is a novel approach for providing peri-operative analgesia wherein the articular branches of femoral nerve, obturator nerve and accessory obturator nerve are blocked. It has been found to be very effective as a regional anaesthesia technique during hip surgeries. We, hereby evaluated the USG guided PENG block with 0.25% bupivacaine (20ml) in 4 patients scheduled to undergo hip fracture surgeries. There was significant reduction in the pain scores both at resting position and 15 degree leg raise after the institution of block in all patients. All patients could sit upright during the institution of spinal anaesthesia.

This is an Open Access (OA) journal, and articles are distributed under the terms of the [Creative Commons Attribution-NonCommercial-ShareAlike 4.0 License](https://creativecommons.org/licenses/by-nc-sa/4.0/), which allows others to remix, tweak, and build upon the work non-commercially, as long as appropriate credit is given and the new creations are licensed under the identical terms.

For reprints contact: [reprint@ipinnovative.com](mailto:reprint@ipinnovative.com)

## 1. Introduction

Elderly people are quite prone to hip fractures because of age related osteoporosis and other degenerative changes.<sup>1</sup> The surgical reduction and fixation of the fractures are the only definitive treatment in most patients.<sup>2</sup> Opioids and various other drugs are used to relieve the associated pain prior to the surgery but the related adverse effects like nausea, vomiting, respiratory depression, hypotension, and delirium preclude their much use.<sup>3</sup> Femoral Nerve Block (FNB) and Fascia Iliaca Block (FIB), are used for achieving effective perioperative analgesia because of their opioid-sparing effects<sup>4,5</sup> but the analgesic effect of these blockades is only moderate as the obturator nerve (ON) is not adequately affected.<sup>6</sup> The anterior hip capsule is the richly innervated by ON, accessory obturator nerve (AON) and femoral nerve (FN). The high articular branches from FN and AON are consistently found between the anterior inferior iliac spine (AIIS) and the ilio-pubic eminence

(IPE), whereas the ON is located close to the infero-medial acetabulum. The pericapsular nerve group (PENG) block is an ultrasound guided approach,<sup>7</sup> which blocks these articular branches of FN, ON, AON and is found to be very effective as a regional anaesthesia technique for hip fracture surgeries. Few studies have demonstrated its beneficial effects in reducing the pain during the procedures. A recent case series on the use of PENG block found that 9 out of 10 patients did not require any support while making them upright for spinal anaesthesia (SA).<sup>8</sup> There is a considerable scope and evidence to increase its application and thus we hereby report the use of USG-guided PENG block by using 0.25% bupivacaine (20ml) in 4 patients.

## 2. Case Series

The PENG block was performed in 4 patients scheduled to undergo hip fracture orthopaedic surgery under spinal anaesthesia. All the patients were explained about the procedure during the pre-anaesthetic visit one day prior to the surgery and informed written consent was taken.

\* Corresponding author.

E-mail address: [anitasharma677@gmail.com](mailto:anitasharma677@gmail.com) (A. Sharma).

Patients were informed about the verbal analogue score (VAS) for pain assessment ranging from 0 to 10, with 0 being “no pain” and 10 being “the worst pain imaginable.” Standard hospital protocol regarding medical optimisation, intravenous line placement, pre-medication, and antibiotic prophylaxis were followed. In the operating room, monitors for non-invasive blood pressure, 5-leads continuous electrocardiogram, and pulse oximeter were attached. The sono-anatomy of the hip was analysed in the supine position, by using a low frequency curvilinear probe (3–5 Hz) to view AIIS, IPE, and pubic ramus (PR) and a pulsating femoral artery (FA) above the iliacus muscle. After all aseptic precautions, under local anaesthesia, PENG block was given with 23G spinal needle connected to de-aired extension tubing with 10-ml syringe using in-plane approach. A total of 20ml of local anaesthetic drugs (bupivacaine 0.25%) was given after hydro-dissection and negative aspiration.

The pain assessment before the block at both resting and dynamic position (15-degree leg raise test) was done utilizing VAS score. The pain assessment in both the positions was repeated after 20 minutes after the block.

The ease of sitting for the conduct of regional anaesthesia was graded as: 0-not satisfactory, 1-satisfactory, 2-good and 3-optimal.

The demographic profile of the patients is tabulated below. (Table 1)

The pain scores at rest at T0 (before the block) were 8,7,8,6 (on a scale of 0-10) in patients 1,2,3 and 4 respectively. (Figure 1) The dynamic pain scores (assessed at 15-degree leg raise) were 10 in all the patients prior to the procedure. (Figure 1)

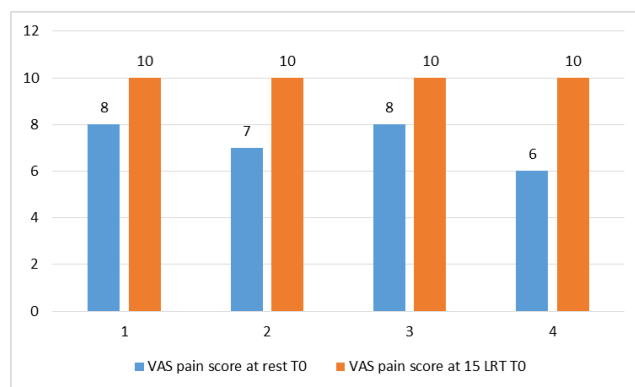


Fig. 1: Pre block pain scores

After the institution of block the pain of all the patients reduced considerably. At 20 minutes after the block the pain scores at rest were at the level of 0,0,0,2 in case 1,2,3 and 4 respectively. The dynamic scores also fell quite significantly in three patients to level of 1 while one patient had moderate improvement as he rated the pain scores at 4 (Figure 2).

The patients could sit upright comfortably during the institution of spinal anaesthesia as their pain component was considerably reduced. When asked to grade the ease of sitting for spinal anaesthesia, three patients rated 3 and one patient rated it as 1 (Figure 3).

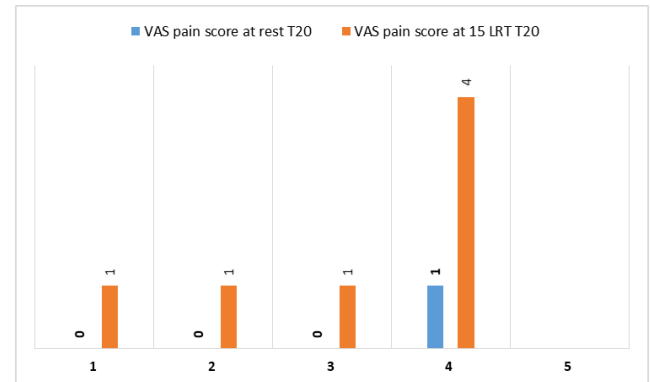


Fig. 2: Post block pain scores

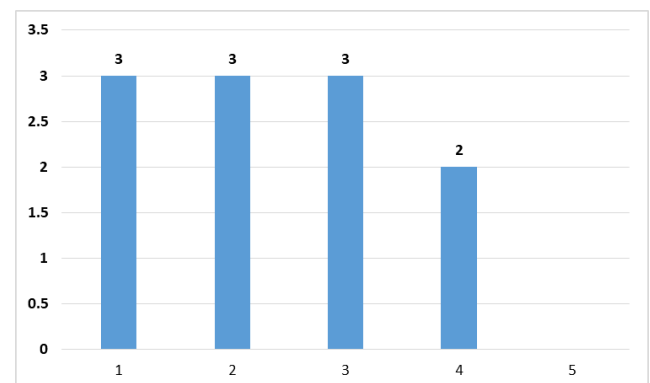


Fig. 3: Ease of positioning for SA

### 3. Discussion

There are only a few studies, most of them being case reports or small series which have demonstrated the application of PENG block in decreasing the pain and helping in the positioning of patients for spinal anaesthesia. Giron-Arango et al<sup>7</sup> in a retrospective cohort of 5 patients demonstrated a decrease of 7 points in median pain scores. They used 20 ml of 0.25% bupivacaine with epinephrine (1:400,000) in 4 cases & 20 ml of 0.5% ropivacaine with epinephrine (1:200,000) plus dexamethasone 4mg in one of the case. Acharya et al<sup>8</sup> also inferred that PENG block is an extremely useful approach for hip surgeries by using 20 ml of 0.125% bupivacaine in 10 of their patients. NRS pain scores were 6-9 (pre-block) vs 3 in three, 2 in four and 1 in three patients after the block. 9 out of 10 patients sat upright at the time of institution of sub-arachnoid block. Jadon et al<sup>9</sup> demonstrated a decrease in pain scores by

**Table 1:** Demographic profile of the patients

Case	Age	Gender	ASA	Type of hip fracture
1	77	F	II	Intertrochanteric; femur; Right
2	50	M	I	Intertrochanteric; femur; Right
3	70	M	II	Sub-trochanteric; femur; Left
4	88	M	II	Intertrochanteric; femur; Right

using 20 ml of 0.25% bupivacaine in 10 patients. NRS pain scores at rest were 6 (pre-block) vs 2 (post block) while scores at 150 leg raise were 8 (pre-block) vs 3 (post block). There was also significant ease of positioning during spinal anaesthesia. Talawar et al<sup>10</sup> (by using 10ml of 0.5% bupivacaine with 10ml of 2% lignocaine-adrenaline) demonstrated the absence of sensation in anterior, medial and lateral compartments of gluteal region in one of their patient undergoing hip arthroscopy. Sahoo et al<sup>11</sup> demonstrated a significant decrease in VAS pain scores both at rest and at 150 leg raise position after the PENG block (Pre-block VAS at rest: 7.45±1.53; Post block (30 mins) VAS at rest: 1.1±1.07) (Pre-block VAS at 15° passive SLR: 9.45±0.75 Post procedure VAS at 15° passive SLR (30 min): 2.35±1.34). Ease of patient positioning for spinal anaesthesia also improved (0-3): 2.65±0.67. Pagano et al<sup>12</sup> also (20 ml of mepivacaine 1% and 0.5% ropivacaine) demonstrated a median reduction of pain (NRS) up to 4 points at rest and 6 points in dynamic state in 6 patients. Brown et al<sup>13</sup> in a prospective series of 28 patients demonstrated a median reduction in pre-operative to post-operative pain of 7 points (range 3-10) on VNRS. There was also decrease in post-operative opioid use and improvement in patient satisfaction scores. Ueshima et al<sup>14</sup> used 10 ml of 1% lignocaine for repositioning of hip dislocation occurring as a complication of hip surgery in 2 of their patients and reported a reduction in pain scores in both the patients (from 10/10 to 3/10 in one case).

The present series also demonstrated a reduction in the pain scores both at rest and at 15-degree leg raise in 4 patients by using 20 ml of 0.25% bupivacaine in PENG block. Pre-block scores at rest were 8,7,8,6 (in patients 1,2,3 and 4 respectively) and at 15-degree leg raise were 10 in all the patients. After the institution of block the pain of all the patients reduced considerably. Post block NRS pain scores after 20 minutes at rest were at the level of 0,0,0,2 (in patients 1,2,3 and 4 respectively) and dynamic scores also fell quite significantly. All the patients could sit upright comfortably during the institution of spinal anaesthesia (ease of sitting for spinal anaesthesia in three patients rated as 3 and one patient rated as 1).

#### 4. Conclusion

This case series may help to reflect a new and alternative technique of nerve blockade for patients supposed to undergo hip fracture surgery. Still, more randomized

controlled trials are required to establish the efficacy, safety, and advantages of PENG block over other regional analgesic techniques and to ascertain the optimal volume/dose and type of local anaesthetics and adjuvant drugs used.

#### 5. Source of Funding

None.

#### 6. Conflict of Interest

The authors declare no conflict of interest.

#### References

- Brauer CA, Coca-Perrillon M, Cutler DM, Rosen AB. Incidence and mortality of hip fractures in the United States. *JAMA*. 2009;302(14):1573–9.
- Neuman MD, Fleisher LA, Even-Shoshan O, Mi L, Silber JH. Non operative care for hip fracture in the elderly: the influence of race, income, and comorbidities. *Med Care*. 2010;48(4):314–20.
- Morrison RS, Magaziner J, Koval KJ, McLaughlin MA, Orosz G, Strauss E, et al. Relationship between pain and opioid analgesics on the development of delirium following hip fracture. *J Gerontol A Biol Sci Med Sci*. 2003;58(1):76–81.
- Foss NB, Kristensen BB, Bundgaard M, Bak M, Heiring C, Virkelyst C, et al. Fascia iliaca compartment blockade for acute pain control in hip fracture patients: a randomized, placebo-controlled trial. *Anesthesiology*. 2007;106(4):773–8.
- Haines L, Dickman E, Ayvazyan S, Pearl M, Wu S, Rosenblum D. Ultrasound-guided fascia iliaca compartment block for hip fractures in the emergency department. *J Emerg Med*. 2012;43(4):692–7.
- Guay J, Parker MJ, Griffiths R, Kopp S. Peripheral nerve blocks for hip fractures. *Cochrane Database Syst Rev*. 2017;5(5):CD001159.
- Girón-Arango L, Peng PW, Chin KJ, Brull R, Perlas A. Pericapsular nerve group (PENG) block for hip fracture. *Reg Anesth Pain Med*. 2018;43(8):859–63.
- Acharya U, Lamsal R. Pericapsular Nerve Group Block: An Excellent Option for Analgesia for Positional Pain in Hip Fractures. *Case Rep Anesthesiol*. 2020;(8):1–3. doi:10.1155/2020/1830136.
- Jadon A, Sinha N, Chakraborty S, Singh B, Agrawal A. Pericapsular nerve group (PENG) block: A feasibility study of landmark based technique. *Indian J Anaesth*. 2020;64(8):710–3.
- Talawar P, Tandon S, Tripathy DK, Kaushal A. Combined pericapsular nerve group and lateral femoral cutaneous nerve blocks for surgical anaesthesia in hip arthroscopy. *Indian J Anaesth*. 2020;64:638–40.
- Sahoo RK, Jadon A, Sharma SK, Peng PW. Peri-capsular nerve group block provides excellent analgesia in hip fractures and positioning for spinal anaesthesia: A prospective cohort study. *Indian J Anaesth*. 2020;64(10):898–900.
- Pagano T, Scarpato F, Chiccone G, Carbone D, Bussemi CB, Albano F. Analgesic evaluation of ultrasound-guided Pericapsular Nerve Group (PENG) block for emergency hip surgery in fragile patients: a case series. *Arthroplasty*. 2019;1:18. doi:10.1186/s42836-019-0018-0.
- Brown B, Lin DY, Saies A, Vermeulen M, Kroon HM, Doornberg J, et al. The Pericapsular Nerve Group Block for Hip Fracture Surgery:


A Prospective Case Series. *J Anesth Clin Res.* 2021;12(4):999.

14. Ueshima H, Otake H. Pericapsular nerve group (PENG) block is effective for dislocation of the hip joint. *J Clin Anesth.* 2019;52:83. doi:10.1016/j.jclinane.2018.09.022.

**Aditi Ranaut**, Junior Resident

**Nidhi Thakur**, Junior Resident

### Author biography

**Anita Sharma**, Senior Resident  <https://orcid.org/0000-0002-3365-1833>

**Shelly Rana**, Professor

**Cite this article:** Sharma A, Rana S, Ranaut A, Thakur N. Pericapsular Nerve Group (PENG) block with bupivacaine for relieving pain during positioning for spinal anaesthesia in 4 patients during hip fracture surgery - A case series. *Indian J Clin Anaesth* 2022;9(1):129-132.