

Ureteroscope guided intubation in a child with Temporo Mandibular Joint Ankylosis

Mrunalini Parasa,^{1,*}, Nagendranath Vemuri², Shaik Mastan Saheb³,
Divya Nayak L⁴, Vidyasagar Ramakrishnan⁵

¹Associate Professor, ²Professor, ³Professor and HOD, ⁴Postgraduate, Dept. of Anaesthesiology,

⁵Associate Professor, Dept. of ENT and Head and Neck Surgery

NRI Academy of Science Chinnakakani, Guntur District, Andhra Pradesh, India - 522503

***Corresponding Author:**

E-mail: parasamrunalini@hotmail.com

Abstract

Temporo mandibular joint ankylosis is an anticipated difficult intubation scenario. Awake fibre optic intubation is the safest approach to secure the airway. Availability of an adequate sized flexible fibreoptic bronchoscope is a prerequisite for successful endotracheal intubation. We report the use of a flexible urethroscope to facilitate nasotracheal intubation in a four years child.

Key Words: TMJ Ankylosis, Flexible fiberoptic bronchoscope, Difficult intubation, Urethroscope, Pediatric intubation

Access this article online	
Quick Response Code:	Website: www.innovativepublication.com
	DOI: 10.5958/2394-4994.2016.00021.4

Introduction

Temporo mandibular joint (TMJ) is a synovial articulation between the mandible and mandibular fossa of the temporal bone. Ankylosis of TMJ is associated with trauma (13-100%), infection (0-53%), systemic disorders like ankylosing spondylitis, rheumatoid arthritis or psoriasis and can even be idiopathic¹. We report a case of ureteroscope guided fibre optic intubation in a case of TMJ ankylosis.

Case Report

A 4year old male child of 10 Kgs weight with retrognathia and ankylosis of the left TMJ was scheduled for gap arthroplasty and coronoidectomy with interpositional costochondral graft. He was apparently normal till 10 months of age, after which he developed progressive restriction of mouth opening which resulted in poor intake of solid food. There was no history of birth trauma, otitis media or any other infections. History and examination did not reveal any congenital anomalies.

The mean maximal incisal opening was 0.5cm and there was mandibular hypoplasia with deviation of mandible to the left (Figure: 1). 3D CT showed mandibular hypoplasia, flattening of left mandibular condyle with erosion, reduced TMJ space and shallow left glenoid fossa.

Written informed consent was taken from the parents after explaining the potential complications and the possibility of a tracheostomy. Standard monitoring was established which included ECG, NIBP and SpO₂. Xylometazoline drops were instilled into both nostrils to facilitate nasal mucosal vasoconstriction.

An inhalational induction was planned and the child was anaesthetised with 8% sevoflurane in 100% oxygen and adequacy of mask ventilation was confirmed. A 22gauge IV access was secured and 5 µg.Kg⁻¹ glycopyrrolate and 0.02 mg.Kg⁻¹ of midazolam were administered. A 9 F 60cms long flexible ureteroscope (Figure: 2) was used to facilitate nasotracheal intubation and a 4.5 mm inner diameter uncuffed portex tube was railroaded in to the trachea over the scope after visualisation of the tracheal rings. 2 mg.Kg⁻¹ propofol, 2µg.Kg⁻¹ fentanyl and 0.1mg.Kg⁻¹ vecuronium were administered after confirmation of satisfactory ETCO₂ waveform and bilateral equal air entry. 1% sevoflurane in 50: 50 nitrous oxide and oxygen was used for anaesthetic maintenance.

We were prepared to perform an emergency tracheostomy which was our plan B and an ENT colleague was in attendance. The mean maximal incisal opening increased to 4cm after the surgical procedure. The child was extubated following reversal of residual neuromuscular blockade. Further postoperative course was uneventful. The child was advised jaw stretching exercises from third postoperative day and was discharged on the 6th postoperative day.

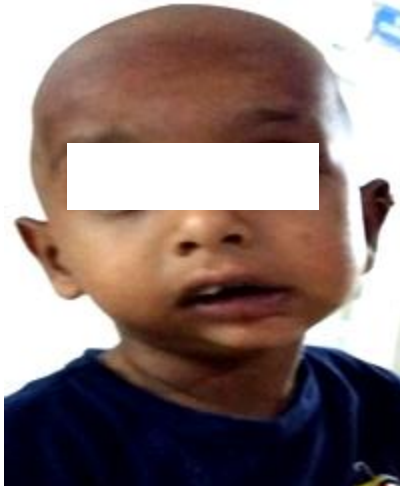

Fig. : 1 Left Temporomandibular joint ankylosis with deviation of mandible to left and retrognathia

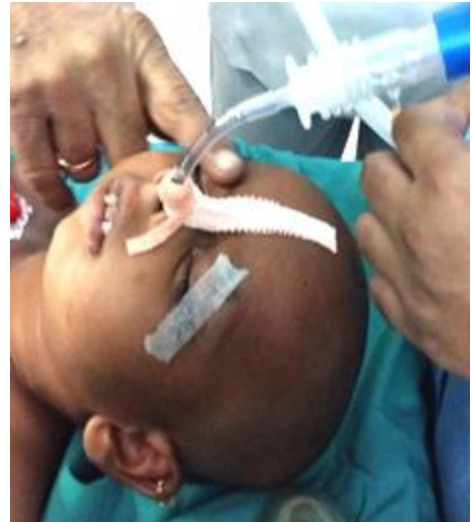

Fig. 4: Urethroscope guided 4.5 sized nasotracheal tube. Also note the retrognathia

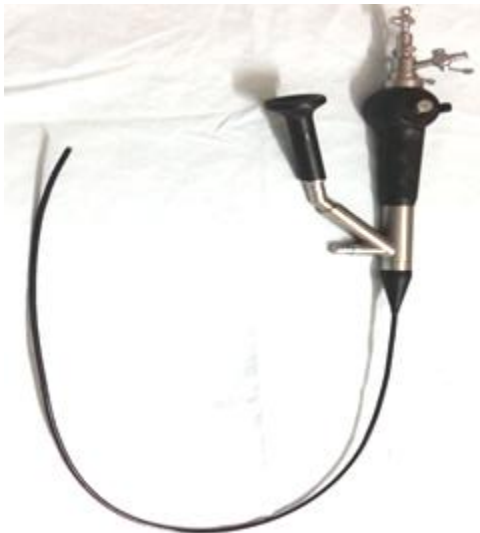

Fig. 2: Flexible fiberoptic urethroscope.

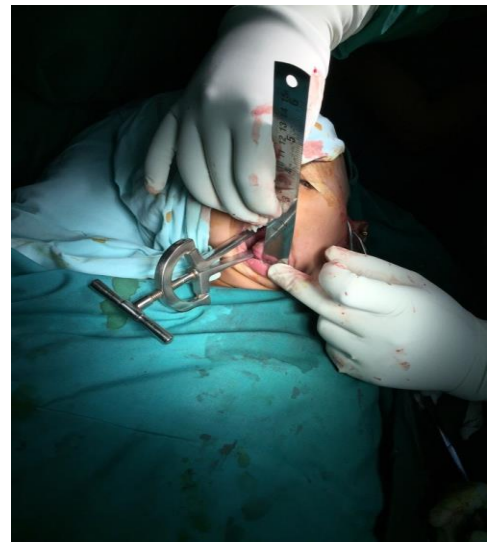


Fig. 5: Mean maximal incisal opening of 4cm intraoperatively.

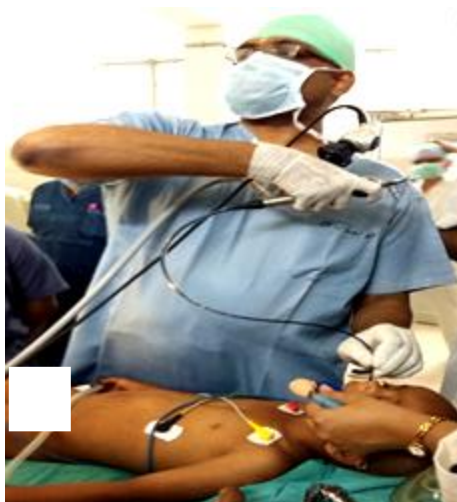

Fig. 3 Nasotracheal intubation using a flexible urethroscope.

Discussion

TMJ ankylosis leads to painless chronic progressive limitation of mouth opening. Ankylosis in a growing child adversely affects the growth and development of jaws, impairs mastication and oral hygiene, predisposes to dental caries, produces micrognathia, facial asymmetry, bird face deformity and adds burden on the child's tender psyche².

Anaesthetising such a patient needs a thorough preoperative assessment, appropriate anaesthetic plan and preparation and the availability of and expertise in using the required equipment. Airway difficulty in this case was due to restricted mouth opening, mandibular hypoplasia, retrognathia and reduced mandibular space with overcrowding of soft tissues. Facial asymmetry could also alter the position of the larynx³. It is unlikely to visualise any part of the larynx by direct

laryngoscope and perform conventional tracheal intubation, if the mouth opening is less than 25mm⁴. An uncooperative and apprehensive child will not allow airway blocks, awake blind nasal or awake fiberoptic intubation. Hence induction with an inhalation anaesthetic was attempted simultaneously confirming the adequacy of mask ventilation. For this child, it would have been ideal to use a 2.2 mm outer diameter fiberoptic scope upon which an endotracheal tube as small as 3mm internal diameter could be mounted to intubate the trachea³. Since a scope of such dimensions was not available in our hospital, we chose to use a flexible ureteroscope.

The idea of using a ureteroscope to assist fiberoptic intubation was borne out of the history of introduction of fiberoptic assisted tracheal intubation. Dr Peter Murphy, then a Senior Registrar at the National Hospital for Nerve diseases in Queen square, London first conceived the idea of using fiberoptic technology for securing the airway⁵. And he was indeed the first person to secure the airway using this technology and the first to describe the technique which was published in "Anaesthesia"⁵. He used a choledochoscope to achieve success with this technique. As the instrument had a fitting that allowed still photography, he was able to obtain the first photograph of the trachea using this technique and included it in his paper⁵.

There was an option to secure the airway blindly under deep inhalational anaesthesia and the technique has its own drawbacks including trauma, the requirement for multiple attempts including failure. Failure to achieve nasotracheal intubation and complications like laryngospasm were a possibility in this case. Hence we were prepared to perform a tracheostomy at any juncture. The disadvantages with the ureteroscope were its long length and increased weight due to additional attachments at the handle.

Conclusion

In this era of rapid technological advances the history of anaesthesia has given us clues to try novel techniques in difficult airway scenarios. Though unfamiliar, the similarity in the basic working principle of a ureteroscope and a fibre-optic scope and the situational demand made us choose the ureteroscope instead.

Competing interests: No external funding and no competing interests declared

Source of Support: Nil

References

1. Mansour A. Qudah, Muawia A. Qudeimat, Jasser Al-Maaita. Treatment of TMJ ankylosis in Jordanian children – a comparison of two surgical techniques. *Journal of Cranio Maxillary surgery* 2005;33(1):30-36.
2. Bob Rishiraj, Leland R. Mc Fadden. Treatment of Temporomandibular Joint Ankylosis : A case report. *J Can Dent Assoc* 2001; 67(11): 659-63.
3. T Sahoo, Y Patil, R Patel, L Dewoolkar. Anaesthetic Management Of A Child With Temporomandibular Joint Ankylosis With Extrahepatic Portal Vein Obstruction For Ankylosis Release. *The Internet Journal of Anesthesiology* 2007; 16(1).
4. T. Kawasaki, T. Sata, C. Kawasaki, M. Ogata and A. Shigematsu. Airway management of a child with Temporomandibular Joint Ankylosis following otitis media. *Anaesthesia* 2002;57(3): 294-295.
5. I. Calder. Murphy P. A fiber-optic endoscope used for nasal intubation. *Anaesthesia* 1967; 22:489-91. *Anaesthesia* 2010; 65: 1133-1136.