

## Anesthetic Management of Arthrogryposis Multiplex Congenita in Children: A Retrospective Review of 27 Cases

Anuradha Ganigara<sup>1,\*</sup>, Chandrika Y Ramavakoda<sup>2</sup>, Madhavi Nishtala<sup>3</sup>, Chandrakala K R<sup>4</sup>

<sup>1,2,3,4</sup>Department of Anaesthesiology, Indira Gandhi Institute of Child Health, Bangalore, Karnataka, India.

\*Corresponding Author:

E-mail: anuradhasudhir@gmail.com

### Abstract

**Background:** Arthrogryposis Multiplex Congenita, is a rare non-progressive congenital syndrome spectrum that causes multiple joint contractures and fibrosis with an intact sensory system and normal intellect. Pediatric patients with AMC frequently present for multiple orthopedic surgeries requiring general anesthesia. Children with arthrogryposis have micrognathia, a high arched palate, a short and rigid webbed neck making tracheal intubation difficult and at times impossible. The extensive contractures, tense skin, minimal muscle mass and subcutaneous tissue pose additional challenges for intraoperative positioning and intravenous access.

**Aims:** To emphasize the anesthetic challenges encountered in this group of patients

**Methods:** A retrospective case note review was performed on 27 children with AMC syndrome over a 5 year period. They belonged to ASA class 1 and 2 with age group between Day 15 of life to 14 years of age and weighing from 2.5 kg to 64 kg.

**Results:** In the majority of cases, the course of general anaesthesia was normal. Clinically, the incidence of Larsen's syndrome in our series was 18%, one child had Freeman Sheldon syndrome and the rest 77% fit into the AMC group. Difficult airway was encountered in 22% of patients with 18% of them having difficult intravenous access. 25% of children presented for multiple orthopedic corrective procedures.

**Conclusions:** Children with AMC have unique needs which need to be recognized preoperatively and dealt adequately. Difficult airway needs to be anticipated which warrants the presence of not only a sophisticated airway cart but also a highly experienced anesthesiologist. These children come for multiple repeat procedures and issues like difficult intravenous access and positioning need to be addressed as well.

**Keywords:** Children, Arthrogryposis multiplex congenital, difficult airway, anesthesia, hyperthermia, intravenous access

Access this article online	
Quick Response Code:	Website: www.innovativepublication.com
	DOI: 10.5958/2394-4994.2016.00015.9

### Introduction

The most baffling and earliest report of Arthrogryposis multiplex congenita can be found in Hindu mythology which describes Ashthavakra as a small boy who was cursed in utero by his father sage Khagodara for his intelligence and was thus born with eight different deformities of the body.<sup>1</sup>

In the west, it was recognized in the early 12th century and in the year 1923, Stern proposed the term Arthrogryposis (*arthro*, joint, *gryp*, curved, literally means curved joint) multiplex congenita. AMC is now perceived as a rare, congenital, non progressive disorder with limitation of movement of 2 or more joints caused by shortening of flexor muscles in different areas of the body.<sup>2</sup>

The primary pathology for development of AMC is in utero restriction of fetal joint mobility. Therefore compromise in fetal joint motility due to any cause

even for short duration may result in joint fixation. This in turn leads to a vicious cycle of growth of extra connective tissue around a functionally normal joint and further restriction of joint movement in utero. Earlier the joint involvement and longer the duration of joint movement restriction, more severe is the contracture at birth. This fetal akinesia leads to series of events which affect various organ systems of the fetus. The newborn could thus have intrauterine growth retardation, congenital contractures of limbs, craniofacial abnormality, midline defects with a short gut, feeding problems and failure to thrive.<sup>3</sup>

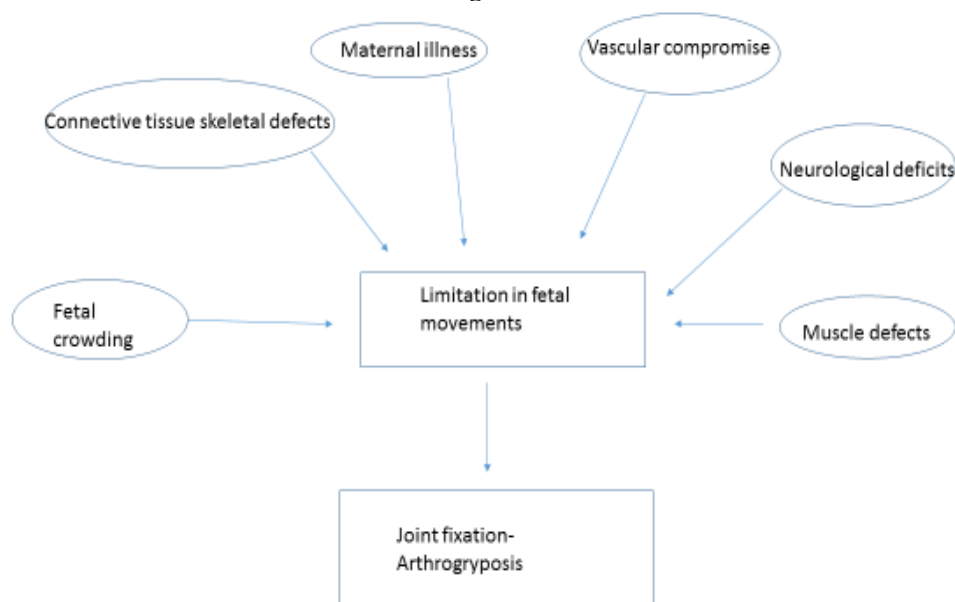
The incidence of AMC is around 1 in 3000 live births. Six major reasons leading to joint restriction are described below in the figure 1.<sup>3,4</sup> AMC has been clinically classified into 3 groups based on the severity of disease spectrum. Type 1 affects primarily the extremities, Type 2 involves primary midline malformations with involvement of extremities. In Type 3 associated central nervous system dysfunction are seen.<sup>3</sup>

Amyoplasia (a-no, myo- muscle, plasia- growth) is the classic form which has an incidence of 1 in 10000 and is characterized by typical symmetrical positioning of limbs with absent muscle tissue, midfacial hemangioma and normal intelligence. 200 different syndromes have been associated with Arthrogryposis

and include Distal Arthrogryposis type I, IIB, IIE, Beals syndrome, multiple pterygium syndrome, Freeman Sheldon syndrome, Diastrophic dysplasia, Larsen's syndrome, Marfan's syndrome, Pena shokeir syndrome, Cerebro oculo facial syndrome, Potter

syndrome etcetera. AMC is purely a descriptive diagnosis; hence all care must be taken to evaluate these children for underlying multi organ system dysfunction.

**Figure 1**



**Table 1: gives a brief description of various deformities associated with AMC.<sup>5,6</sup>**

Airway	Micrognathia, Webbed neck, Mandibulofacial dysostosis, High arched palate, cleft palate, poor gag reflex, poor suck reflex, dysphagia, esophageal dysfunction, loss of supraglottic tone
CNS, Spine	Cortical brain atrophy, vertebral anomalies, hydrocephalus, spina bifida, scoliosis, sacral agenesis
Cardiovascular system	Patent ductus arteriosus, Aortic stenosis, Coarctation of aorta
Respiratory system	Tracheo esophageal fistula, Restrictive lung disease, aspiration pneumonitis
Gastrointestinal system	Gastroesophageal reflux, esophageal dysmotility
Genitourinary system	Cryptorchidism, hypospadias, renal defects
Abdomen and extremities	Inguinal hernias, constriction bands, clinodactyly, muscle atrophy

Arthrogryptic children need multiple orthopedic procedures to improve the function or appearance of the limb affected and thus there are pertinent anesthetic concerns when these children present to us.<sup>7</sup>

### Methods

With institutional review board approval, a retrospective review was done of children with AMC posted for operative procedures under anesthesia the past 5 year period. Twenty seven children belonging to ASA class 1 and 2 within the age group of day 1 of life to 14 years of life and weighing from 3.3 kg to 64 kg were anesthetized. In addition to general demographic data, data regarding type of surgical procedure, anesthesia techniques including airway management,

post-operative pain management and pertinent perioperative information was reviewed.

### Results

In our cohort of 27 patients, 19 boys and 8 girls were anesthetized 34 times during the study period. The weight of these children ranged from 3.3 kilograms to 64 kilograms. The children were in the age group of day 15 of life to 14 years of age.

Five children were clinically diagnosed to have Larsen's syndrome (18%) and one child had Freeman

Sheldon syndrome. The other twenty one children were diagnosed as cases of AMC with no further subclassification (77.7%).

Seven children were anaesthetized on an average of two times for multiple orthopedic corrective procedures. Anesthesia was delivered 14 times for hip spica application or change in corrective cast, 5 times for Ilizarov ring fixator application to the affected limb with another 3 for minimally invasive percutaneous tenotomy procedures. 12 children underwent invasive procedures like adductor tenotomies, open reduction of dislocated joints and other corrective orthopedic procedures.

Difficult intravenous access was found in five patients (18%). Difficult intravenous access was defined as more than 3 attempts by an experienced pediatric anesthesiologist to cannulate a peripheral vein. In one infant scalp veins were used and in a 5 year old boy, one of the anterior abdominal veins were used for venous access after confirming the direction of venous drainage. External jugular vein was used for venous access in a 14 year old boy.

Sevoflurane was commonly used for induction of anesthesia (24), halothane used in 8 patients and intravenous propofol was used for induction in two children. Anesthesia was maintained with gas oxygen and nitrous oxide in ratio of 1:1 with isoflurane to maintain an end tidal concentration of 1 MAC. Intravenous Fentanyl 2micrograms/kilograms was used for analgesia and atracurium in titrated doses was used for muscle relaxation in all patients requiring endotracheal tube intubation and mechanical ventilation. Mechanical ventilation in pressure controlled mode with age appropriate respiratory frequency was employed to achieve an end tidal carbon dioxide concentration of 35-40 mm Hg. Anesthesia was delivered via a face mask for 15 minor procedures under sedation, thrice a supraglottic device either a classic LMA or Proseal was used and in 14 situations the patients were intubated and ventilated when invasive procedures were planned. Two children received regional anesthesia in the form of spinal anaesthesia and lumbar epidural anesthesia under dexmedetomidine sedation.

Difficult airway was anticipated in 10 patients based on 3 important preoperative difficult airway predictors namely: mouth opening, micrognathia and neck extension. Difficult mask ventilation with difficult intubation was seen in 1 patient, 6 of them had difficult intubation with Cormack Lehane grade of greater than 3(22%). Age of children with difficult airway varied from 1 month of age to 5 years 6 months.

Regional anesthesia in the form of caudal epidural analgesia was employed in eight children, with spinal anesthesia and lumbar epidural anesthesia in one and three patients respectively. In one child regional anesthesia was offered as the sole anesthetic under dexmedetomidine sedation and in two of the patients,

epidural anesthesia was abandoned due to severe anatomical deformities of the lumbar spine.

Temperature was monitored in all patients in whom either the airway was managed using a supraglottic device or endotracheal tube. No rise in temperature was noted in any of the patients posted for corrective surgery.

At the end of the procedure, after reversal of the neuromuscular blocking agent and extubation, they were monitored for post anesthesia complications in the recovery room for 2 hours and shifted subsequently to the postoperative ward. No anesthetic related event was recorded in the post-operative period.

## Discussion

Children affected with AMC often require anesthesia for multiple corrective orthopedic and reconstructive procedures. Normal childhood experiences are important for a healthy adult life and thus when these arthrogryptic children present for multiple surgical corrections, we as anesthesiologists must have concrete suitable plans to ensure least interference with their growth and development. They are often referred to as "birthday surgeries" further emphasizing the need for incident free and pain free hospital stay.<sup>8</sup>

The most important anesthetic concern in children with AMC is airway management. The airway poses a difficulty due to associated maxillofacial abnormalities like micrognathia, high arched palate, short, rigid webbed neck, temporomandibular joint dislocation, cervical spine instability, microstomia and associated facial asymmetry.<sup>5,9</sup>

In our series of AMC, six children had (22.22 %) documented difficult airway. One child had difficulty in both mask ventilation and intubation and his airway was secured via blind nasal intubation under deep spontaneous ventilation. Two children with Larsen's syndrome had Cormack Lehane grade of class 3a on direct laryngoscopy and associated subglottic stenosis requiring passage of endotracheal tube one size lesser than age appropriate ones. One child presented with Freeman Sheldon syndrome with less than 1 centimetre mouth opening. His airway was very ingeniously managed with a classic LMA which was folded on itself, completely deflated and inserted via the 360 degree rotational technique. After insertion it was slowly inflated to give a good seal and anesthesia was maintained with propofol infusion without use of muscle relaxants.

It becomes imperative that the airway of children with AMC is evaluated preoperatively and an adequate airway management plan is in place before anesthetizing these children. We believe that best predictors of difficult airway in children are presence of micro/retrognathia, limited mouth opening, limited neck extension with syndromic or features of facial

asymmetry. Using these predictors we predicted a probable difficult airway in 37 % of our children.

Thus, easily accessible difficult airway cart in the operative room is mandatory. In our series, we managed the predicted difficult airways using multiple approaches like airway instrumentation under deep spontaneous ventilation, intubation stylets, optimal external laryngeal manipulation and use of supraglottic devices. We did not use sophisticated equipment like flexible fiberoptic bronchoscopy, videolaryngoscopes to instrument the airway because of unavailability.

Difficult airway incidence has been around 22- 25 % in two different reviews, broadly echoing our results.<sup>5,10</sup> Postoperative respiratory complications due to concurrent restrictive lung disease, poor gag and cough reflex, poor airway control has been mentioned in various reviews but we did not encounter any such problems postoperatively. We partly attribute this to multimodal approach to pain management viz judicious use of opioid analgesics with supplementary regional anesthesia and paracetamol suppositories.

Regional anesthesia can be challenging in these patients because of the presence of scoliosis and spinal deformities.<sup>11</sup> Presence of severe spinal deformity in two children aged 12 and 14 years precluded the use of regional technique and the procedure was abandoned, surgery was continued in one of them with general anesthesia and endo tracheal tube intubation and mechanical ventilation and the other child received spinal anesthesia which again, was successful after three attempts.

We found that both the airway access and spinal anatomy becomes more challenging with the growth of these children. An issue that generates immense interest in children with AMC and anesthesia is that of its probable association with malignant hyperthermia.<sup>5,12,13,14</sup> Case reports of suspected malignant hyperthermia have been reported by Froster –Iskenius et al and Hopkins et al. Martin s et al in their review on AMC in 12 children have also reported hyperthermia not greater than 38.8degree Celsius though without any evidence of malignant hyperthermia.<sup>5,13,14</sup> On a similar note, Baines et al in their review of patients with AMC found no evidence of malignant hyperthermia in 396 anesthetic exposures in 67 patients with AMC.<sup>12</sup> In our series we have not encountered any rise in body temperature of children with AMC but nevertheless intraoperative temperature monitoring is mandatory for all patients with AMC presenting for anesthesia. Other concerns which need to be addressed include intravenous access, positioning and choice of neuromuscular blocking agents.

These children because of extensive skin contractures, minimal muscle mass and scanty subcutaneous tissue tend to have difficult intravenous access. Their external appearance is often likened to “wooden dolls”.<sup>15</sup> We used anterior abdominal veins, scalp veins and external jugular vein as alternate routes

for intravenous access and before accessing such veins it is essential to know the venous drainage of the chosen vessel. Intraoperative positioning needs special mention because of existing joint contractures, osteoporotic bones and therefore one should ensure adequate padding of all bony protruberances.<sup>5,16</sup>

Associated myopathy and poor muscle mass in these children can lead to postoperative ventilatory depression and thus it is prudent to use neuromuscular blocking agents judiciously. We used titrated doses of atracurium as the neuromuscular blocking agent and faced no such perioperative problems like delayed recovery, hypoventilation.<sup>5</sup>

Lastly, we need to overemphasize the fact that these children with AMC present to us for anesthesia for multiple procedures and thus the need to establish an exceptional rapport with this special group of children who are otherwise mostly blessed with normal intelligence.<sup>17</sup> Adequate premedication, counselling all go hand in hand in establishing social, mental and emotional wellbeing of these special children.

In conclusion, in this retrospective article we reviewed our institutional protocol for anesthetizing children with AMC and found that airway mangement is the most crucial factor while handling these children. Apart from a progressively difficult airway, issues like co existing neuromuscular or congenital abnormalities, provision of regional pain management strategies, difficulties encountered while positioning and securing intravenous access for fluid management and the anesthetic need for multiple procedures need to be appropriately addressed.

**Conflict of Interest:** None

**Source of Support:** Nil

## References

1. Williams G M. Handbook of Hindu mythology. Oxford university Press. ISBN 978-0-19-5-33261-2
2. Bharucha E P, Pandya SS and Dastur D K. Arthrogryposis multiplex congenital. Part 1 :Clinical and electromyographic aspects. Journal of Neurology, Neurosurgery and Psychiatry,1972; 35:425-434
3. Staheli L T, Hall J G, Jaffe K M and Pahalke DO. Chapter one: Overview of Arthrogryposis. Hall J G. pages- 1-24 -Arthrogryposis –a text atlas. Cambridge university press.1998. ISBN 0-521-57106-5
4. Hall J G. Arthrogryposis( Multiple Congenital Contractures). In : Rimion RL CJ, Pyeritz RE et al ed. Emery and Rimion’s Principles and Practice of Medical Genetics.5<sup>th</sup> ed. Philadelphia: Churchill Livingstone 2007:3785-856
5. Martin S and Tobias J D. Perioperative care of the child with arthrogryposis. *Pediatr Anesth* 2006;16:31-37
6. Nguyen N H, Morvant E M, Mayhew J F. Anesthetic management of patients with Arthrgryposis multiplex congenital and severe micrognathia. *J Clin Anesth* 2000;12(3):227-30
7. Thompson GH, Bilenker R M. Comprehensive management of Arthrgryposis multiplex congenita. *Clin Orthop* 1985;194:6-14

8. Wlasczuk E G, Majewski J, Szczygiel R and Kurak J. Anesthesia in patients with arthrogryposis. *Anesthesiology Intensive Therapy* 2011;2:79-81
9. Epstein J B, Wittenberg G J. Maxillofacial manifestations and management of arthrogryposis: literature review and case report. *J Oral Maxillofac Surg* 1987;45:274-279
10. Steinberg B, Nelson V S, Feinberg S E et al. Incidence of maxillofacial involvement in Arthrogryposis multiplex congenita. *J Oral Maxillofac Surg* 1996;54:956-959
11. Yingsakmongkol W, Kumar S J. Scoliosis in arthrogryposis multiplex congenita: results after nonsurgical and surgical treatment. *J Pediatr Orthop* 2000;20:656-661
12. Baines D B, Douglas I D, Overton J H. Anesthesia for patients with arthrogryposis multiplex congenita: what is the risk of malignant hyperthermia? *Anesth Intensive Care* 1986;14:370-372
13. Hopkins P M, Ellis F R, Halsall P J. Hypermetabolism in arthrogryposis multiplex congenita. *Anesthesia* 1991;46(5):374-5
14. Froster -Iskenius U G, Weterson J R, Hall J G. A recessive form of congenital contractures and torticollis associated with malignant hyperthermia. *J Med Genet* 1988;25:102-12
15. Oberoi G S, Kaul H L, Gill I S, Batra R K. Anesthesia in Arthrogryposis multiplex congenita: case report. *Can J Anesth* 1987;34:288-90
16. Pujari V S, Shivanna S, Anandaswamy T C and Manjunath A C. Arthrogryposis multiplex congenita: An anesthetic challenge. *Anesth Essays Res* 2012;6:78-80
17. Lloyd- Roberts and Lettin A W F. Arthrogryposis multiplex congenita. *The journal of bone and joint surgery* 1970;52B(3):494-508.