

## Comparison of orotracheal versus nasotracheal fiberoptic intubation in simulated cervical spine patients, under conscious sedation

Tarang Jain<sup>1,\*</sup>, Lalit Gupta<sup>2</sup>, Manoj Bhardwaj<sup>3</sup>

<sup>1,2</sup>Assistant Professor, <sup>3</sup>Professor, Dept. of Anaesthesia, <sup>1</sup>ESI-PGIMS, Basaidarapur, New Delhi, <sup>2,3</sup>Maulana Azad Medical College, Delhi, India

\*Corresponding Author: Tarang Jain

Email: dr.tarang@yahoo.co.in

Received: 19<sup>th</sup> July, 2018

Accepted: 27<sup>th</sup> July, 2018

### Abstract

**Introduction and Aims:** Airway management in a patient with cervical spine injury is considered a challenge. Minimizing neck movement and maintaining head in neutral position is essential to prevent secondary neurological injury. Flexible fiberoptic intubation causes minimal cervical spine movement. In this study, we evaluated and compared orotracheal and nasotracheal flexible fiberoptic intubation in a patient with simulated cervical spine injury (using a cervical collar), under conscious sedation.

**Materials and Methods:** Sixty patients were randomly allocated into oral and nasal groups. After premedication and preparation with Xylometazoline nasal drops and lignocaine nebulization, bolus fentanyl and propofol infusion was started to achieve conscious sedation. Flexible fiberoptic intubation was performed orally or nasally, after placement of a cervical collar. Operator ease and hemodynamics were monitored.

**Result:** In the oral group, 86.7% and in the nasal group, 93.3% first attempts were successful. The ease of fiberoptic intubation was graded to be excellent in a significantly greater number of patients in the nasal group as compared to the oral group. Hemodynamic variability though present was not clinically relevant, this might have been secondary to use of adequate sedation.

**Conclusion:** The ease of fiberoptic intubation in simulated cervical spine injury, under conscious sedation was found to be significantly better in the nasotracheal group. Hemodynamic stability was demonstrated in both the groups in our study.

**Keywords:** Cervical spine, Simulated cervical spine, Fiberoptic intubation, Oral fiberoptic intubation, Nasal fiberoptic intubation, Conscious sedation.

### Introduction

Cervical spine injured patients present an airway management challenge, as any movement of the cervical spine exacerbates the injury.<sup>1</sup> Presence of cervical collar prevents neck movement but can cause reduction in mouth opening, this makes laryngoscopy difficult and impairs visualization of the glottic opening.<sup>2,3</sup> Fiberoptic intubation is an established method of securing airway in patients having cervical spine injury. Rosenblatt et al<sup>4</sup> and Lord et al<sup>5</sup> have advocated use of bronchoscope for intubation in cervical spine injury patients. Flexible fiberoptic intubation causes minimal cervical spine movement, and is the gold standard for intubation in suspected cervical spine injury.<sup>6,7</sup>

Fiberoptic intubation has been carried out successfully in patients with cervical spine injury via both the oral and nasal route, but literature lacks comparison among these two methods. In this study, we evaluated and compared orotracheal and nasotracheal flexible fiberoptic intubation in a patient with simulated cervical spine injury (using a cervical collar), under conscious sedation.

This study was conducted in the Department of Anesthesiology and Intensive Care, MAMC and LNH after approval from Ethical committee and institutional review board clearance. The study was conducted on 60 patients ASA 1-2, aged 20-50 years admitted in Lok Nayak Hospital, New Delhi undergoing elective surgery, other than neck surgery, requiring endotracheal

intubation after obtaining consent. Randomization done using a computer generated random number table. Patients having difficult airway, hypertension or use of drugs modifying blood pressure, Respiratory/Cardiac/Esophageal disease, and difficult nasal route/any contraindication to nasal intubation and having increased risk of gastric aspiration were excluded from the study.

### Materials and Methods

All the patients were premedicated with 0.25 mg Alprazolam night before and 2 hours prior to start of the surgery. Topical anaesthesia of the airway was achieved by nebulization with 5 ml of 4% Lignocaine. Xylometazoline nasal drops were put twice at an interval of 15 minutes in all patients to achieve vasoconstriction. All patients received glycopyrrolate (0.2 mg intramuscular) thirty minutes before shifting to operation theatre. Five minutes after giving midazolam (0.03mg/kg) and fentanyl (1.5 µg/kg) intravenously, Propofol 0.5 mg/kg was given followed by an infusion of 50 µg/kg/min to achieve conscious sedation. Oxygen was given at 4 l/min via nasal cannula and continued during the fiberoptic intubation using the working channel of the fibroscope. The semirigid collar used to simulate cervical spine injury was inserted after giving sedation.

Fiberscope loaded with predetermined sized (6.5 for females, 7.5 for males) endotracheal tube was introduced

through oral or nasal route and on visualization of the glottic opening; vocal cords were sprayed with 2ml of 2% lignocaine through the working channel of the fibroscope. This process was repeated after the fibroscope had crossed the vocal cords. When the carina was visible an endotracheal tube of size 7.5 in males and size 6.5 in females was guided into place (3-4 cm above the carina) and then Bain's circuit was connected and intubation was confirmed by appearance of Et CO<sub>2</sub> graph. General anaesthesia was then provided by giving propofol (0.5mg/kg), vecuronium 0.1mg/ and isoflurane at 0.8% through Bain's circuit.

Sedation score of the patients and vitals (NIBP, PR, and SpO<sub>2</sub>) were monitored before starting fibroscopy. Patient's consciousness was assessed and propofol infusion was adjusted to attain Ramsay Sedation score 3. During fibroscopy and intubation, maneuvers to clear airway like chin lift, jaw thrust and 180° rotation of endotracheal tube over fibroscope were performed, when required. A total of three attempts were made. Inability to intubate despite applying airway clearing maneuvers (chin lift and jaw thrust) and of 180° rotation of endotracheal tube over fibroscope was considered as a failure of securing airway, following which the cervical collar was removed the patient paralyzed and intubated using direct laryngoscopy.

The operator performing the procedure graded the ease of handling at previously determined points, which included insertion of fibroscope, visualization of glottic opening, sliding of endotracheal tube and overall ease of handling, as difficult, easy and excellent.

The patients were assessed for sore throat, 2 hours and 24 hours after completion of the surgery.

Data was statistically analyzed as Mean  $\pm$  SD with 95% confidence interval. Comparison of two Means for continuous variables such as heart rate, blood pressure, and mean arterial blood pressure was performed using the Student -t test and non-parametric variables using

Mann-Whitney test. For categorical variables Chi-square/Fischer exact test was used. Intragroup comparison at two points in time was done using Paired t-test and for non-parametric variables using Wilcoxon signed rank test. A p value of <0.05 was considered statistically significant.

### Observation

Sixty patients were included in this study. Demographic characteristics including age, height, weight, body mass index, gender, and criteria of airway assessment were found comparable and statistically insignificant ( $p > 0.05$ )

A total of three attempts were allowed in the study. In the oral group, 86.7% (26/30) intubations were successful in the first attempt and 6.7% (2/30) in the second attempt. Two patients (6.7%) could not be intubated in the third attempt also. In the nasal group, 93.3% (28/30) were successful in the first attempt and 3.3% (1/30) in the second attempt. The third attempt was unsuccessful in one patient in the nasal group. In all three patients, a failure to intubate was because of inability to slide the tube over the fibroscope beyond a certain point, 16 cm in the oral and 20 cm in the nasal (Table 1). More airway clearing maneuvers were required in the oral group for visualization of the epiglottis (50%) as compared to the nasal group (33.33%), the difference was not statistically different ( $p$  value > nasal group). The mean insertion time was more in the nasal group (2.8 min) compared to the oral group (2.7 min), though the difference was not statistically significant.

The ease of fibreoptic intubation was graded to be excellent in a significantly greater number of patients in the nasal group as compared to the oral group with regards to the visualization of the epiglottis (100% vs 73.3%) and advancement of fibroscope into the glottic opening (96.7% versus 70% :  $p < 0.05$ ).

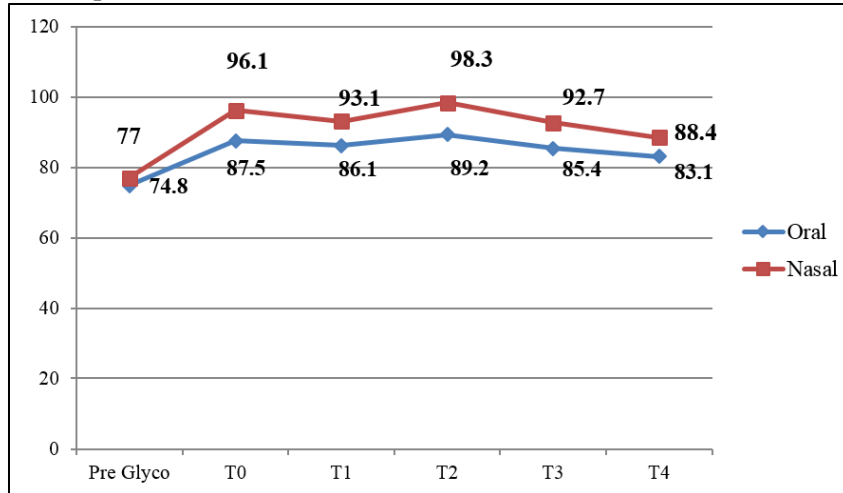
**Table 1: Results of oral/nasal fibreoptic intubation**

Parameters	Oral Group	Nasal Group
Successful Fibreoptic Intubation	28/30	29/30
First Attempt	26/30	28/30
Second Attempt	2/30	1/30
Mean intubation Time	162.68 sec (86-295)	169.9 sec (90-230)
Reason of failure of intubation: (n)	1. Inability to advance ETT at level of pyriform fossae (2) 2. Obstruction to passage of ETT beyond tip of fibroscope (2) 3. Inability to advance the ETT beyond the pyriform fossae(2)	1. Inability to advance ETT due to obstruction in nasal cavity(1) 2. Patient movement leading to esophageal intubation(1) 3. Inability to advance ETT due to obstruction at level of pyriform fossae(1)
Airway clearing maneuvers	15/30	10/30
Chin Lift	11/15	10/10
Jaw Thrust	4/15	Nil
Propofol Increment dose(mg) Mean $\pm$ SD	42.0 (29.2)	36.3 (15.6)
Incidence of limb movement	11/30	9/30
Incidence of cough	7/30	4/30
Desaturation	15/30	13/30
Sore throat	13/30	9/30

All the patients in both groups remained hemodynamically stable throughout the procedure. On comparison, after intubation the pulse rate, SBP, DBP,MAP were lower in the oral group and the

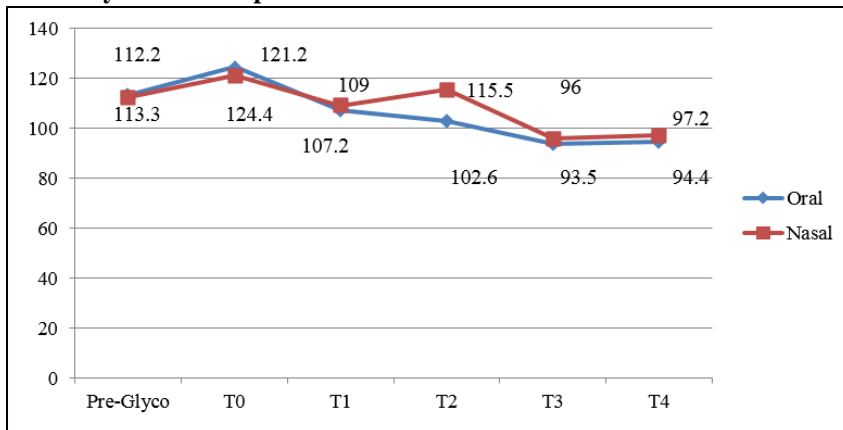
difference was found to be statistically significant, p value of <0.05 (Graph 1,2,3).

**Graph 1: Comparison of pulse rate**



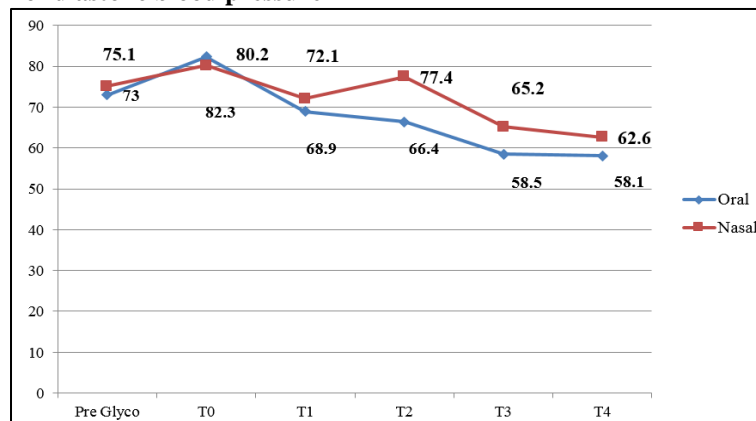
(Significant post intubation (T2) variation seen p: 0.031)

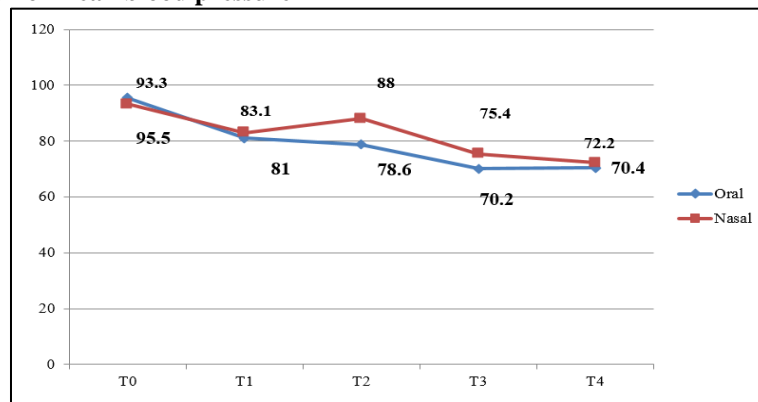
**Graph 2: Comparison of systolic blood pressure**



(Significant post intubation (T2) variation seen p: 0.001)

**Graph 3: Comparison of diastolic blood pressure**



**Graph 4: Comparison of mean blood pressure**

(Significant post intubation (T2) variation seen p: 0.005)

## Discussion

Use of the fiberoptic bronchoscope to facilitate tracheal intubation in cervical spine-injured patients has been advocated by neuroanesthesia experts' nationwide<sup>8</sup> with stabilization of the cervical spine. The patient's protective reflexes are largely left intact and a neurologic assessment can be made after intubation to ensure that there has been no change in the patient's status.<sup>1</sup> Use of sedation has resulted in better patient cooperation and comfort. These considerations support the use of the tracheal intubation facilitated by a fiberoptic bronchoscope in the management of the airway of cervical spine injury patients. Both orotracheal and nasotracheal routes can be used for fiberoptic intubation. However, there is no clinical outcome data suggesting better ease and safety comparing the two routes in cervical spine injury. This prospective randomized controlled study was conducted to compare the ease, safety and hemodynamic changes between orotracheal and nasotracheal fiberoptic intubation, in simulated cervical spine injury, under conscious sedation, under comparable doses of midazolam, fentanyl and propofol.

The two groups were demographically comparable with respect to the sex, weight, height and body mass index distribution, ASA Grading and MMPC. Success rate of intubation was 93.3% (n=30) in Oral Group (O) and 96.7% (n=30) in Nasal Group (N). The first attempt success rate was 86.7% in the oral group and 93.3% in the nasal group. Two cases in the oral group and one case in the nasal group were successful in the second attempt in the oral group, fiberoptic intubation was achieved without any maneuver in 50% patients in the oral group and 66.7% patients in the nasal group. Chin lift was the most commonly used maneuver used in 36.6% of the cases in the oral group and 33.3% cases in the nasal group. Jaw thrust was used in 13.3% patients in the oral group and was not required in any patient in the nasal group.

In a similar study Sharma et al<sup>9</sup> had a success rate of 60% in the first attempt, which increased to 100% after removal of endotracheal tube by 5 cm and railroading after 90° rotation. This high rate of unsuccessful intubation in the first attempt in the study by Sharma et

al could be due to a larger size of tube used – size 7 in female and 8 in male patients. In our study, relatively small size of endotracheal tube and opening of the airway by the chin lift maneuver might have led to better success rate in the first attempt.

The success rate of nasotracheal fiberoptic intubation in our study was similar to the study by Fuchs et al<sup>10</sup> with a success rate of 96.3% in 327 neurosurgical patients who underwent intubation under general anesthesia. Their failure rate of 3.6% was due to nasal anatomic abnormalities preventing trans-nasal insertion of endotracheal tube. In their study they have not mentioned if any maneuver to facilitate intubation was attempted. Woodall et al<sup>11</sup> had a failure rate of 10% of patients, with awake fiberoptic nasal intubation. They attributed the failure to intubate due to anatomic reasons in 10 patients and inadequate anesthesia in 8 patients. In our study, patients were optimally sedated and topicalized which might have led to better success rate.

The mean insertion time in our study was 162.68 sec in the oral group and 169.97 sec in the nasal group the insertion time reported by Sharma et al<sup>9</sup> in their study was 11 sec for orotracheal fiberoptic intubation. This was significantly less as compared to our study due to different start and end times. They defined the insertion time as the time from starting advancement of the tracheal tube to withdrawal of the fibrescope. This was different from our study where we considered the time from entry of scope into oral cavity to confirmation of endotracheal tube placement.

The insertion time reported by Fuchs et al<sup>10</sup> for nasotracheal fiberoptic intubation was 7.3 min, with a range of 2-50 min. Their insertion time started from application of cocaine to the nasal mucosa and ended at positioning of the endotracheal tube. This may have been responsible for the longer time taken in their study. This differed from our study; our insertion time was from insertion of fibrescope into the nasopharynx to confirmation of endotracheal tube placement.

In the nasal group, handling of the fibrescope was significantly better than the oral group during visualization of epiglottis and advancement of

fibrescope into the glottic opening. The ease of insertion of the fibrescope through the oro/nasopharynx and ease of intubation, sliding of endotracheal tube was found to be similar in both the groups. On overall grading and scoring there was statistically better ease of intubation seen in the nasal group as compared to the oral group.

There is a lack of evidence in literature regarding subjective assessment of fiberoptic intubation. Though Asai and Shingu<sup>12</sup> in their review article have mentioned a variability of 0-90% in the incidence of difficulty in sliding the endotracheal tube in fiberoptic orotracheal intubation. The studies of Asai and Marsh et al reported an incidence of 83% and 90% difficulty in sliding the tube in their studies respectively. They reported an incidence of 10-90% difficulty in sliding the endotracheal tube in nasotracheal fiberoptic intubation. The studies of Jones and Barker reported an incidence rate of 73% and 50% in their studies respectively. In these studies, the assessment criteria were not defined clearly. Further, the assessment was graded only with regards to sliding of tube and not the ease of insertion, handling of the fibrescope and visualization of glottic opening considered in our study.

The saturation was > 95% in all patients, providing oxygen at 4L/min via nasal cannula, prior to fibroscopy. Desaturation (SpO<sub>2</sub><90%) occurred in two cases in the oral group while sliding the endotracheal tube over the fibrescope, after giving an incremental dose (10 mg) of propofol on patient movement. The first attempt was abandoned as the patients went into apnea. Propofol infusion was stopped and 100% oxygen given in both cases. The second attempt in both the cases was successful, without any episode of desaturation. Woodall et al<sup>11</sup> in their study provided supplemental oxygen via nasal cannula in all patients during awake fiberoptic intubation. They reported three cases of hypoxia occurred, these incidences of hypoxia occurred despite lack of sedation. Fuchs et al<sup>10</sup> in a similar study reported a saturation of less than 90% in 11.6% of cases, with saturation being less than 80% in 4 patients. They attributed this to over sedation or inadequate local anesthesia and bronchospasm. They have not mentioned whether oxygen was provided to the patients in their study.

The sedation scores of the patient were assessed as per the Ramsay Sedation Score at different steps during fiberoptic intubation, they stayed at 3 or 4 for the duration of the procedure. Spontaneous respiration was present in the patients at all points of time.

Laryngospasm occurred in two patients in the oral group and one patient in the nasal group. It occurred on spraying lignocaine through the working channel of the scope and resolved on its own after 30 seconds. This could have been due to local anesthetic action of lignocaine which resolved the spasm.

Cough was present in 7 (23.33%) patients in the oral group and 4 (13.33%) patients in the nasal group. In our study, propofol was given to suppress further coughing

in these patients. This was similar to that reported by Sharma et al.<sup>9</sup> They reported an incidence rate of cough as occurring in 25.71% of patients their study. Coughing leading to head and neck movement, is deleterious in cervical spine injury patients. Our study may be lacking in adequacy of topicalization of the airway. This might have led to airway stimulation and coughing.

Bleeding was present in 6.6% of patients in the oral group and 13.3% of patients in the nasal group (It was noticed to be minor in all the patients and did not interfere with the fiberoptic attempt. Woodall et al<sup>11</sup> and Fuchs et al,<sup>10</sup> reported an incidence of 10% and 8.8% incidence of minor bleeding.

Thirteen patients (44.8%) in the oral group and nine patients (30%) in the nasal group complained of sore throat after 2 hours. The sore throat resolved in 36 hours, without any intervention. Fuchs et al<sup>10</sup> found the incidence rate of sore throat as 6% in their study. This is considerably higher than our study; however the time period for the observation has not been mentioned in their study. Woodall et al<sup>11</sup> found the incidence rate of sore throat to be 35% in their study. This could have been due to the multiple attempts of fiberoptic intubation in their study.

The change in pulse rate and systolic and diastolic blood pressure in the oral group remained insignificant when compared at different time intervals but in the nasal group on comparison at different time intervals, increase was significant after intubation (T2) when compared to the post sedation value (T1). When the two groups were compared, the rise in was more in the nasal group as compared to the oral group after intubation (T3). This difference between the two groups was statistically significant. This could be due to increased airway stimulation, as the fibrescope and endotracheal tube had to traverse a longer route via the nasal cavity. This change was however not clinically important. The hemodynamic stability demonstrated in both the groups in our study, could have been due to optimum topicalization and adequate sedation, which blunted the response caused by airway stimulation.

Xue et al<sup>13</sup> in their study showed that both fiberoptic orotracheal and nasotracheal intubation cause significant increases in pulse rate and blood pressure. In both the oral and nasal routes in their study, there was a significant rise in systolic and diastolic as well as mean arterial pressure and pulse rate as compared to the post induction values. This rise was more in the nasal group as compared to the oral group though this was not significant. The blood pressure returned to the post induction values in both groups within 3 minutes though pulse rate in the oral group settled comparatively later than the nasal group. They have postulated that this difference in the post intubation response between oral and nasal routes is due to greater stimulation of airway structures in the nasal group. This could be due to insertion of fiberoptic scope and endotracheal tube through the nasal cavity leading to greater circulatory

response. In a similar study Woodall et al<sup>11</sup> on awake nasotracheal fiberoptic intubation, found that the increase in systolic blood pressure per subject ranged from 0-63 mm Hg (0-53%), while the increase in heart rate ranged from 0-59 beats per minute. They concluded that hemodynamic stability had been lost as a consequence of avoiding sedation. In our study, adequate sedation may have been responsible for the hemodynamic stability seen. Williams et al<sup>14</sup> in their study demonstrated an average increase in mean arterial pressure of 16.2% with a range of 1-33.3%. The heart rate values in their study were more variable, with an average increase of 30.2% and a range of 0-158.3%. This variability could have been due to avoidance of sedation in their study.

### Conclusions

The ease of fiberoptic intubation in simulated cervical spine injury, under conscious sedation was found to be significantly better in the nasotracheal group. Hemodynamic stability was demonstrated in both the groups in our study.

**Conflicts of Interest:** None.

### References

1. Crosby ET. Airway management in adults after cervical spine trauma. *Anesthesiol.* 2006;104(6):1293-318.
2. Graham JJ. Complications of cervical spine surgery-A five-year report on a survey of the membership of the Cervical Spine Research Society by the Morbidity and Mortality Committee. *Spine.* 1989;14:1046-1050.
3. Sahin A, Salman MA, Erden A, Aypar U. Upper cervical vertebrae movement during intubating laryngeal mask, fiberoptic and direct laryngoscopy: a video-fluoroscopic study. *Eur J Anaesthesiol.* 2004;21:819-823.
4. Rosenblatt WH, Wagner PJ, Ovassapian A, Zain ZN. Practice patterns in managing the difficult airway by anesthesiologists in the United States. *Anesth Analg.* 1998;87:153-157.
5. Lord SA, Boswell WC, Williams JS, Odon JW, Boyd CR. Airway control in trauma patients with cervical spine fractures. *Prehosp Disas Med.* 1994;9:44-49.
6. Wong DM, Prabhu A, Chakraborty S, Tan G, Massicotte EM, Cooper R. Cervical spine motion during flexible bronchoscopy compared with the Lo-Pro Glidescope. *Br J Anaesth.* 2009;102(3):424-430.
7. Byhahn C, Nemetz S, Brietkreutz R, Zwissler B, Kaufmann M, Meininger D. Tracheal intubation using the Bonfils intubation fibrescope or direct laryngoscopy for patients with a simulated difficult airway. *Can J Anesth.* 2008;55(4):232-237.
8. Koerner IP, Brambrink AM. Fiberoptic techniques. *Best Pract Res Clin Anaesthesiol.* 2005;19(4):611-621.
9. Sharma D, Bithal PK, Rath GP, Pandia MP. Effect of orientation of a standard polyvinyl chloride tracheal tube on success rates during awake flexible fiberoptic intubation. *Anaesthesia.* 2006;61(9):845-848.
10. Fuchs G, Schwarz G, Baumgartner A, Kaltenböck F, Voit-Augustin H, Planinz W. Fiberoptic intubation in 327 neurosurgical patients with lesions of the cervical spine. *J Neurosurg Anesthesiol.* 1999;11(1):11-16.
11. Woodall NM, Harwood RJ, Barker GL. Complications of awake fiberoptic intubation without sedation in 200 healthy anaesthetists attending a training course. *Br J Anaesth.* 2008;100(6):850-855.
12. Asai T, Shingu K. Difficulty in advancing a tracheal tube over a fiberoptic bronchoscope: incidence, causes and solutions. *Br J Anaesth.* 2004;92(6):870-881.
13. Woodall NM, Harwood RJ, Barker GL. Complications of awake fiberoptic intubation without sedation in 200 healthy anaesthetists attending a training course. *Br J Anaesth.* 2008;100(6):850-855.
14. Williams KA, Barker GL, Harwood RJ, Woodall NM. Combined nebulization and spray-as-you-go topical local anaesthesia of the airway. *Br J Anaesth.* 2005;95(4):549-553.

**How to cite this article:** Jain T, Gupta L, Bhardwaj M. Comparison of orotracheal versus nasotracheal fiberoptic intubation in simulated cervical spine patients, under conscious sedation. *Indian J Clin Anaesth.* 2018;5(4):603-608.