

Palatal Fistula repair by Tongue Flap- A challenge to Anaesthesiologist

Ragi Jain^{1,*}, Puneet Bhandari²

¹Professor, ²PG Student, Dept. of Anaesthesia, Santosh Medical College, Ghaziabad

***Corresponding Author:**

Email: ragijain5@gmail.com

Abstract

Airway management is an important aspect of anaesthesia practice, entailing not only a thorough expertise, but also familiarity with alternate techniques, especially when surgery is for upper airway pathology. A 7-year old child with palatal fistula presented to our pre-anaesthetic clinic, for its closure by tongue flap. Child had been previously operated for cleft lip and palate. Palatal fistula closure was done in two stages. 1st stage included tongue flap being attached to the fistula and 2nd stage included the release of this tongue flap. We will be discussing the airway management of this case, and especially the 2nd stage where tongue had occupied much of the oral cavity, making administration of general anaesthesia a challenge in such cases.

Keywords: Palatal fistula, Tongue flap, Anaesthesia, Difficult airway

Introduction

One of the fundamental responsibilities of anaesthesiologist is to mitigate the adverse effects of anaesthesia on respiratory system by maintaining airway patency and ensuring adequate ventilation and oxygenation.⁽¹⁾ Hence airway management is one of the most challenging aspects of this specialty, despite the numerous gadgets available. This challenge increases manifold when surgery in itself pertains to the upper airways.

Case Report

We present a case of 7-year old boy, weighing 17-kilogram scheduled for repair of palatal fistula by posterior tongue flap. He had already undergone four surgeries for repair of cleft lip and palate in some other institute. This palatal fistula closure had to be accomplished with posterior tongue flap, which entailed two stage surgeries. In the 1st stage, dorsal tongue flap was raised and attached to the palatal fistula, while the 2nd stage consisted of dissection of the tongue flap. After getting pre-anaesthetic checkup done, the 1st stage surgery was performed under nasotracheal intubation. This surgical session went uneventful. Child was discharged from the hospital after ascertaining satisfactory intake of oral feeds.

For the second stage surgery for release of tongue flap one month later, we again planned for nasotracheal intubation. Orotracheal intubation did not seem possible as tongue had occupied much of the oral cavity and also surgical team favored nasal intubation. We had already explained about the absence of pediatric fiberscope in our institute. After obtaining pre-anaesthetic checkup clearance for the 2nd stage surgery, we planned for the blind nasal intubation of the child under spontaneous ventilation. On the day of surgery in the operation theatre, after establishing intravenous access, child was premedicated with injection ondansetron 1.5mg, injection glycopyrrolate 0.1mg, injection midazolam

1mg intravenously. Anticipating airway manipulation, we administered 50mg of hydrocortisone also intravenously. Anaesthesia plane was deepened with incremental doses of ketamine with oxygen being administered by mask. Finally to relax the airway muscles, child was given titrated doses of injection propofol intravenously and oxygen-nitrous was administered via face mask to blunt the airway reflexes, but keep intact the spontaneous respiration. Blind nasal intubation with 4.0mm endotracheal tube was tried, but was unsuccessful. After many failed attempts, we decided to try oral intubation. Child was again given propofol and inhalational agents including isoflurane. When a deep plane of anaesthesia was reached, oral intubation attempt was made using Miller straight blade laryngoscope, negotiating the tongue flap to reach epiglottis. Epiglottis was lifted, though only posterior commissure could be visualized and uncuffed endotracheal tube no 4.0mm was successfully passed through the vocal cords. Following confirmation of tracheal placement of the endotracheal tube, injection vecuronium (1.5mg) was given intravenously with inhalational administration of oxygen, nitrous oxide and isoflurane. (Fig. 1) Throat was also packed using the similar approach as intubation. Surgeons took an hour and a half to dissect the tongue flap and to stitch the wound, before the child could be extubated (Fig. 2). Rest of the postoperative course was uneventful and child was discharged after initiation of satisfactory oral intake.

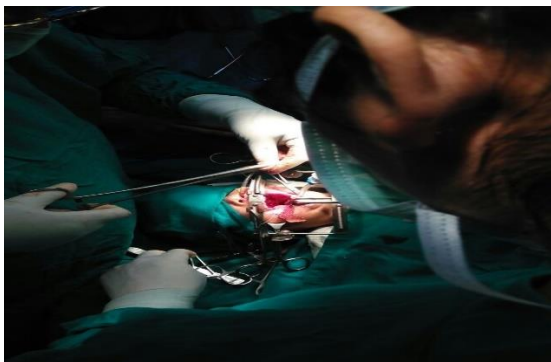


Fig. 1: Picture showing orally inserted endotracheal tube with tongue flap in place

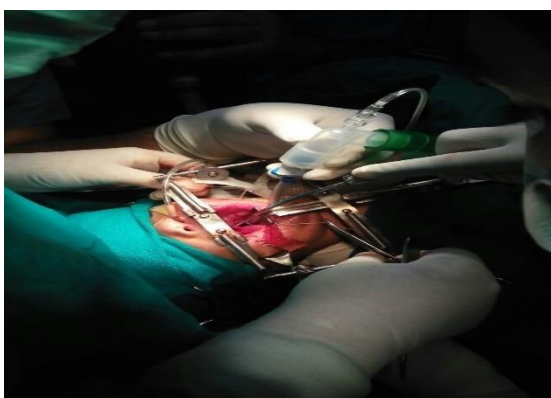

Fig. 2: Picture showing surgery in progress

We will be discussing the anaesthetic management of such difficult airway cases under ideal conditions and also in places which function on limited resources.

Discussion

Anterior palatal fistula or oronasal fistula is the most common complication of cleft palate repair, the incidence ranging from 4–35%.⁽²⁾ Tongue flaps, constructed from the dorsum of tongue, are widely used for closing these residual palatal fistulae.^(3,4) This flap surgery for cleft palate involves two separate operations. In the 1st, tongue flap is created to close the palatal defect. In the second, flap is divided. Flap division is done by various authors varying from 20-21 days.⁽²⁾ These airways are readily managed for the initial flap construction surgery using nasal intubation.^(3,4,5) Nasotracheal intubation and subsequent anaesthesia course was uneventful in this 1st stage surgery. However various complications resulting from nasal passage of the tube, such as turbinectomy or retropharyngeal dissection, have been reported. The most common complication is epistaxis, which occurs with an incidence of 18-66%.⁽⁶⁾

Airway management of 2nd operation is complicated by the flap between tongue and the palate. Besides occupying the oral space, tongue flap causes restricted mouth opening. Securing the airway for

tongue flap division surgery during 2nd operation is more challenging.^(3,5)

Although tongue flaps have been successfully divided under anaesthesia and iv sedation by various authors, this requires patient co-operation, and bleeding and aspiration into an unsecured airway may occur.⁽³⁾ Tongue flap can be divided under local anaesthesia followed by induction of general anaesthesia (GA).⁽⁴⁾ Sherry Peter et al tied two silk threads towards the tongue end of flap, and the flap was divided between them. This technique prevents bleeding. If bleeding occurs it is immediately cauterized with bipolar cautery. Once the flap was divided, conventional induction of GA and orotracheal intubation was done.⁽⁷⁾ Naveen Eipe had used sedation with ketamine to divide the flap, followed by orotracheal intubation in one of their patients, while in another retromolar intubation was done before flap division.⁽⁵⁾

Sahoo et al described the use of right molar approach with a straight Miller blade to achieve orotracheal intubation under GA in a patient for tongue flap release. Throat pack was inserted from left molar approach. The advantage of right molar approach was that the bulging of tongue over the blade was prevented unlike the midline approach.⁽⁴⁾ In our present case, we had also used Miller no. 3 blade for intubation. We gently negotiated through the flap under deep plane of anaesthesia, without using relaxant and were able to pass a relatively smaller sized endotracheal tube.

Airway management is a major factor responsible for morbidity and mortality in pediatric anaesthesia.⁽⁸⁾ Because of increased oxygen consumption and decreased oxygen reserve, hypoxemia occurs rapidly in infants and children as compared to the adults.⁽⁹⁾ The principle of managing the difficult airway in this age group is to maintain spontaneous ventilation until the airway is secure. A spontaneous ventilation technique retains some muscle tone in the upper airway and allows the anaesthesiologist to use the alternate equipments to gain view of the structures and intubate the patient. Use of muscle relaxant to take over ventilation in the difficult airway can potentially result in difficulty in ventilation and hypoxia in a patient who cannot be intubated. The use of an inhalational technique or intravenous induction agents in very small doses can allow loss of consciousness but preserve the spontaneous respiration. Whatever technique is chosen, maintenance of spontaneous respiration is critical to the safety and success of airway management.^(10,11)

Any approach can be used, though Miller straight blade is preferred.⁽⁴⁾ Sahoo and Eipe concluded that orotracheal fiberoptic intubation is the preferred method for securing the airway.^(4,5) It is advisable to avoid nasal intubation after any palatoplasty, as the palatal flap may be damaged, and use of fiberoptic intubation may be difficult and may disrupt or damage the flap.^(3,4,5)

Conclusion

Orotracheal intubation using fiberoptic scope remains preferred option in such challenging cases. But it may not be always available. Therefore familiarity with different laryngoscopic blades and different approaches to intubation are essential.⁽⁴⁾

References

1. Hagberg CA, Artime CA. Airway management in the adult. In: Miller RD, Cohen NH, Eriksson LI, Fleisher LA, Wiener-Kronish JP, Young WL, editors. Miller's Anesthesia. Eighth edition. Philadelphia. Elsevier Saunders 2015. Page 1647-83.
2. Mahajan RK, Chhajlani R, Ghildiyal HC. Role of tongue flap in palatal fistula repair: A series of 41 cases. *Indian J Plast Surg* 2014;47:210-5.
3. Ayeko MO, Mohan G, Basha AA. Successful awake nasal fiberoptic intubation in a patient with restricted mouth opening due to a large tongue flap. *Saudi J Anaesth* 2015;9:100-1.
4. Sahoo TK, Ambardekar M, Patel RD, Pandya SH. Airway management in a case of tongue flap division surgery: A Case Report. *Indian J Anaesth* 2009;53:75-8.
5. Eipe N, Pillai AD, Choudhrie A, Choudhrie R. The Tongue Flap: An Iatrogenic Difficult Airway. *Anesth Analg* 2006;102:971-3.
6. Delgado AV, Sanders JC. A Simple Technique to Reduce Epistaxis and Nasopharyngeal Trauma during Nasotracheal Intubation in a Child with Factor IX Deficiency Having Dental Restoration. *Anesth Analg* 2004;99:1056-7.
7. Peter S, Subash P, Paul J. Airway management during second-stage tongue flap procedure. *Anesth Analg* 2007;104:217.
8. Bloch EC, Ossey K, Ginsberg B. Tracheal intubation in Children: A New Method for Assuring Correct Depth of Tube Placement. *Anesth Analg* 1988;67:590-2.
9. Frie FJ, Ummenhofer W. Difficult intubation in paediatrics. *Pediatr Anesth* 1996;6:251-63.
10. Walker RWM, Ellwood J. The management of difficult intubation in children. *Pediatr Anesth* 2009;19:77-82.
11. Paterson NA. Management of an unusual pediatric difficult airway using ketamine as a sole agent. *Pediatr Anesth* 2008;18:785-8.