



## Case Report

# Anesthetic management in a rare case of clark-baraitser syndrome: Insights and challenges

Madhu Madhu<sup>1\*</sup>, Teena Bansal<sup>1</sup>, Nisha Yadav<sup>1</sup>

<sup>1</sup>Dept. of Anaesthesiology, Pandit Bhagwat Dayal Sharma Post Graduate Institute of Medical Sciences, Rohtak, Haryana, India



### ARTICLE INFO

#### Article history:

Received 24-02-2024

Accepted 05-08-2024

Available online 30-08-2024

#### Keywords:

Clark baraitser syndrome

High arch palate

Hypotonia

Seizures

### ABSTRACT

Clark Baraitser syndrome is a rare autosomal dominant genetic disorder characterized by multiple congenital anomalies and distinctive facial features. These features, including a high arched palate, can complicate airway management. Anaesthetizing an intellectually disabled patient is a challenging task due to lack of communication and understanding, which makes perioperative evaluation difficult. The perioperative management of antiepileptic drug therapy is important for seizure control in these patients. This case report describes the anaesthetic management of 10-year-old child with Clark Baraitser syndrome with bilateral undescended testis posted for orchiopexy.

This is an Open Access (OA) journal, and articles are distributed under the terms of the [Creative Commons Attribution-NonCommercial-ShareAlike 4.0 License](https://creativecommons.org/licenses/by-nc-sa/4.0/), which allows others to remix, tweak, and build upon the work non-commercially, as long as appropriate credit is given and the new creations are licensed under the identical terms.

For reprints contact: [reprint@ipinnovative.com](mailto:reprint@ipinnovative.com)

## 1. Introduction

Clark Baraitser syndrome is a rare autosomal dominant genetic syndrome caused by a missense variation in exon 18 of the TRIP 12 gene (chr2:g.229805753T>C;depth:80x), which results in the amino acid substitution of serine for asparagine at codon 876.<sup>1</sup> This disorder features obesity, macrocephaly, dysmorphic facial features (e.g. large forehead, long philtrum) and various other anomalies.<sup>2-4</sup> Facial dysmorphism and a high arched palate complicate airway management. Additionally, intellectual disability poses challenges in perioperative evaluation. The perioperative management of antiepileptic drug therapy is important for seizure control in these patients. Here we report anaesthetic management in the case of Clark Baraitser syndrome posted for orchiopexy.

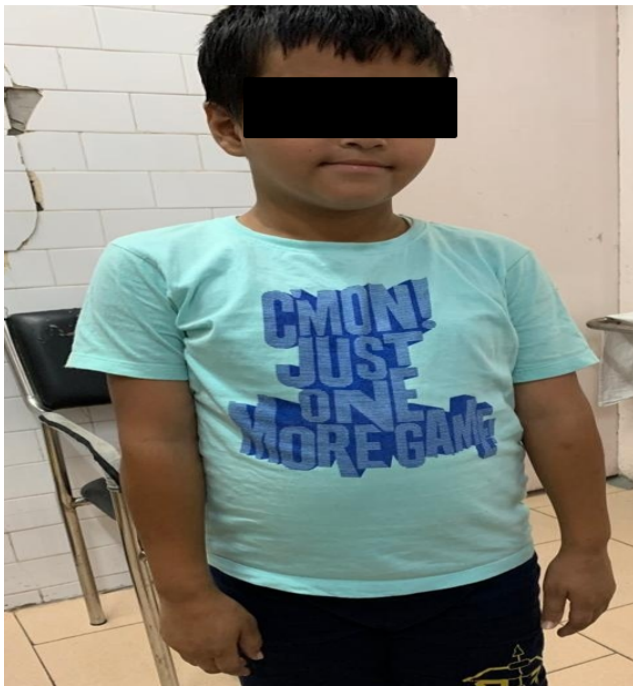## 2. Case Report

A 10-year-old male, weighing 36 kg and measuring 130 cm in height, was scheduled for orchidopexy due to an undescended testis present since birth. His medical history includes being born at term via lower segment caesarean section (LSCS) due to breech presentation and experiencing hypoglycaemia at birth. At 2.5 months, he began having generalized tonic-clonic seizures, which are currently managed with clobazam 10 mg once daily, levetiracetam 500 mg twice daily, and sodium valproate 500 mg twice daily. He has no history of previous surgeries, cyanosis, jaundice, known cardiac disease, drug allergies, or recent upper respiratory tract infections.

Upon examination, the patient displayed facial dysmorphism, including a prominent forehead, telecanthus, malar hypoplasia, mild prognathism, and exotropia. His systemic examination revealed a clear chest and normal heart sounds. Airway evaluation indicated a Modified Mallampati Grade II, with a high-arched palate, small upper lateral incisors, and normal neck movements and spine alignment.

\* Corresponding author.

E-mail address: [madhuahlawat27@gmail.com](mailto:madhuahlawat27@gmail.com) (M. Madhu).



**Figure 1:** Picture of the child with Clark-Baraitser syndrome

Investigations included a two-dimensional echocardiogram that showed normal left ventricular systolic function with an ejection fraction of 60%. Haematological and biochemical tests were within normal limits. Abdominal ultrasound revealed fatty liver changes. MRI of the brain showed bilateral ventricular dilation, absence of the septum pellucidum, right medial temporal sclerosis, bilateral frontal atrophy, and a partial empty sella.

### 2.1. Anaesthetic management

A written and informed consent was taken from the parents following the discussion on the possibility of a difficult airway. The child was kept fasted for 6 hours for solids and 2 hours for liquids prior to surgery. With an anticipated difficult airway, a difficult airway cart was kept ready. General anaesthesia with a supraglottic airway device was planned for the procedure. Standard ASA monitoring was done. Baseline vital parameters were heart rate, which was regular and ranging from 75-80 beats per minute, blood pressure of 104/66 mmHg and oxygen saturation of 99% on room air. Intravenous access was secured in the right hand with a 20G cannula and ringer lactate was used as maintenance fluid. Anaesthesia was induced with glycopyrrolate 0.2 mg, fentanyl 80 mcg and propofol 80 mg. Adequate ventilation with a bag and mask was confirmed before inj rocuronium 20 mg was administered. A size 3 i-gel was inserted, and IPPV was established. A size 12 Fr suction catheter was inserted through the gastric port of the i-gel and aspirated. Anaesthesia was maintained with

sevoflurane 1% in 40% oxygen and 60% nitrous oxide. Neuromuscular block was antagonised at the end of surgery, and the i-gel was removed with a suction catheter after spontaneous breathing had returned. The patient had an uncomplicated recovery from anaesthesia.

### 3. Discussion

CBS is rare, and patient may present when they require surgery for cryptorchidism and exotropia, which is part of the syndrome. We found no reports of anaesthetic management of children with Clark Baraitser syndrome, and additional case reports will allow better characterization of anaesthesia practices and outcomes.

Anaesthetic management in CBS is challenging, from preoperative evaluation to postoperative management. Preoperatively, thorough airway assessment should be performed in patient with CBS. The characteristic facial features and high arched palate can make airway management difficult. These patients can also have an intellectual disability, impulsive and aggressive behaviour, due to which they have problems with cognition and cooperation, and airway assessment becomes difficult. Due to uncooperative nature, awake fiberoptic intubation will also not be possible. These patients should also be considered at risk of epilepsy during the perioperative period. The epileptic attacks frequency and its control must be evaluated in perioperative period. Here, the patient took his regular antiepileptic medication on the day of surgery. Although thiopentone has anticonvulsant properties but propofol was used as induction agent due to its rapid onset and favourable profile in managing difficult airways. Ongoing intraoperative and postoperative dosing of anticonvulsant medication is suggested with an alternate route of delivery or alternate medication if enteral administration is not feasible.

For the diagnosis of intraoperative seizures, Bispectral Index (BIS) monitoring can be useful as seizures often lead to abnormal fluctuations or decreases in BIS values due to epileptiform EEG activity.<sup>5</sup> Additionally, patients with a history of seizures may present with hypotonia, making them more sensitive to non-depolarizing neuromuscular blocking agents. This increased sensitivity can lead to an intensified response to muscle relaxants, warranting the use of neuromuscular monitoring during the procedure. Rocuronium is an appropriate choice for neuromuscular blockade, as it is reversible with sugammadex.<sup>6,7</sup>

In this case, the patient was scheduled for orchidopexy, a procedure that did not involve airway manipulation. Given the anticipated difficult airway, we opted for supraglottic airway devices instead of endotracheal intubation to manage the patient's airway effectively.<sup>8</sup>

#### 4. Conclusion

Anesthetic management of patients with rare and unknown syndromes can present significant challenges, necessitating thorough preparation for various potential complications, including difficult airway management and delayed recovery. To date, there are no case reports in the English literature highlighting the perioperative care of patients with Clark-Baraitser syndrome (CBS). Effective anesthetic management for CBS requires meticulous planning, encompassing strategies for difficult airway scenarios, seizure control, and the possibility of prolonged recovery. In our case, the successful use of an i-gel supraglottic airway device emphasizes its suitability and effectiveness in managing such complex cases.

#### 5. Sources of Funding

None.

#### 6. Conflict of Interest

None.


#### References

- Louie RJ, Friez MJ, Skinner C, Baraitser M, Clark RD, Schwartz CE, et al. Clark-Baraitser syndrome is associated with a nonsense alteration in the autosomal gene TRIP12. *Am J Med Genet A*. 2020;182(3):595–6.
- Brunet M, Vargas C, Larrieu D, Torrisani J, Dufresne M. E3 Ubiquitin Ligase TRIP12: Regulation, Structure, and Physiopathological Functions. *Int J Mol Sci*. 2020;21(22):8515.
- Zhang J, Gambin T, Yuan B, Szafranski P, Rosenfeld JA, Balwi MA, et al. Erratum to: Haploinsufficiency of the E3 ubiquitin-protein ligase gene TRIP12 causes intellectual disability with or without autism spectrum disorders, speech delay, and dysmorphic features. *Hum Genet*. 2017;136:1009–11.
- Mendicino A, Sabbadini G, Pergola MS. Clark-Baraitser syndrome: Report of a new case and review of the literature. *Clin Dysmorphol*. 2005;14(3):133–5.
- Tallach RE, Ball DR, Jefferson P. Monitoring seizures with the Bispectral index. *Anaesthesia*. 2004;59:535–9.
- Martyn JA, Richtsfeld M. Succinylcholine-induced hyperkalemia in acquired pathologic states: etiologic factors and molecular mechanisms. *Anesthesiology*. 2006;104(1):158–69.
- Tobias JD. Current evidence for the use of sugammadex in children. *Paediatr Anaesth*. 2017;27(2):118–25.
- Raj D, Luginbuehl I. Managing the difficult airway in the syndromic child. *Contin Educ Anaesth Crit Care Pain*. 2015;15(1):7–13.

#### Author biography

**Madhu** **Madhu,** Senior Resident  
 <https://orcid.org/search?searchQuery=0009-0004-7883-5515>

**Teena Bansal,** Professor  <https://orcid.org/0000-0002-7277-4262>

**Nisha Yadav,** Junior Resident  <https://orcid.org/0009-0000-8241-9945>

**Cite this article:** Madhu M, Bansal T, Yadav N. Anesthetic management in a rare case of clark-baraitser syndrome: Insights and challenges. *Indian J Clin Anaesth* 2024;11(3):434-436.