

Content available at: <https://www.ipinnovative.com/open-access-journals>

Indian Journal of Clinical Anaesthesia

Journal homepage: [www.ijca.in](http://www.ijca.in)

## Case Series

## Parasacral ischial plane block for lower limb surgeries: A case series

Parth Pandya<sup>1\*</sup>, Sudha Shah<sup>1</sup>, Yatin Bharad<sup>1</sup><sup>1</sup>Dept. of Anesthesiology, Parul Institute of Medical Sciences & Research, Parul University, Vadodara, Gujarat, India

## ARTICLE INFO

## Article history:

Received 27-05-2024

Accepted 15-06-2024

Available online 30-08-2024

## Keywords:

PIP block

Sacral plexus

ultrasound

Sacrum

Fascial plane

Nerve block

Lower limb surgeries

## ABSTRACT

**Background:** The para-sacral ischial plane block (PIP block) is a novel fascial plane approach targeting the sacral plexus. This technique simplifies the process as direct visualization of the sacral plexus or sciatic nerve is unnecessary.

**Materials and Methods:** This retrospective case series includes ten patients with American Society of Anesthesiologists (ASA) physical status II-IV, aged over 18 years, undergoing elective or emergency lower limb surgeries such as debridement and below-knee amputation between May 2023 and November 2023.

**Results:** The block was performed in  $\leq 6$  minutes for all patients. Onset of subjective analgesia was almost immediate in those presenting with pain. Sensory loss occurred within 9 to 12 minutes. Motor block in the sciatic nerve distribution did not reach Grade 2 in any patient. Hemodynamic stability was notably maintained in all high-risk cases. Intraoperative supplementation with ketamine was required for one patient.

**Conclusion:** The PIP block is a quick, easy-to-perform technique that offers satisfactory surgical conditions and hemodynamic stability in high-risk patients undergoing lower limb surgeries. It also provides prolonged postoperative analgesia and early resumption of oral intake with minimal procedural discomfort.

This is an Open Access (OA) journal, and articles are distributed under the terms of the [Creative Commons Attribution-NonCommercial-ShareAlike 4.0 License](https://creativecommons.org/licenses/by-nc-sa/4.0/), which allows others to remix, tweak, and build upon the work non-commercially, as long as appropriate credit is given and the new creations are licensed under the identical terms.

For reprints contact: [reprint@ipinnovative.com](mailto:reprint@ipinnovative.com)

## 1. Introduction

Peripheral nerve blocks are gaining increasing popularity for lower limb surgeries, thanks to the development of new techniques such as ultrasound guidance and peripheral nerve stimulators. These blocks provide stable hemodynamics, good intraoperative working conditions, and prolonged postoperative analgesia.

The first description of the Parasacral Sciatic Nerve block is attributed to Mansour, who also described it as a Sacral plexus block.<sup>1</sup>

The para-sacral ischial plane (PIP) block is a novel fascial plane approach to the sacral plexus. It is a relatively simple technique that does not require visualization of the sacral plexus or sciatic nerve. Several studies and case

series have demonstrated its effectiveness. In 2022, Khaja M. Sharefudeen et al. concluded in a case series that the PIP block can be successfully used for lower limb wound debridement surgeries. It is technically easy, less time-consuming, and provides adequate analgesia for below-knee surgeries.<sup>2</sup>

In 2020, Venkatraju A. et al. found that the para-sacral ischial plane approach to the sacral plexus is easier and safer. They noted that the parasacral sciatic nerve block, considered an advanced block, uses bony landmarks as signposts to locate the plexus rather than endpoints on their own. This approach eliminates the need to sonographically visualize the plexus to achieve a successful sacral plexus block.<sup>3</sup>

In 2016, Bansal et al. used ropivacaine with fentanyl for a combined femoral and sciatic nerve block, concluding

\* Corresponding author.

E-mail address: [pandya.parth17@yahoo.com](mailto:pandya.parth17@yahoo.com) (P. Pandya).

that this technique has minimal hemodynamic instability. It can be used in patients with valvular cardiac diseases, fixed cardiac output, diabetes, and even those on anticoagulants. The technique offers prolonged analgesia with negligible toxicity compared to traditional techniques and drugs.<sup>4</sup> Therefore, the PIP block, with femoral nerve block, if necessary, can be a better alternative to general anesthesia, central neuraxial blockade, and blocks with multiple injections in high-risk patients with cardiopulmonary comorbidities, a fact which has also been validated by Tantry TP et al in their study.<sup>5</sup>

Here, we present a retrospective case series of ten high-risk cases of below-knee surgeries, including below-knee amputation and debridement, performed under the PIP block ( $\pm$  femoral nerve block) between May 2023 and November 2023.

## 2. Case Presentation

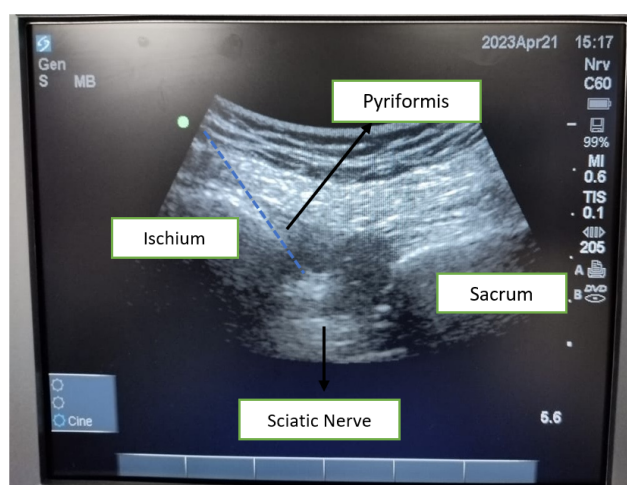
This retrospective case series included ten patients with American Society of Anesthesiologists (ASA) physical status II-IV, aged over 18 years, scheduled for elective or emergency lower limb surgeries such as debridement and below-knee amputation, between May 2023 and November 2023. Approval for the study was obtained from the Scientific Research Committee and Ethical Committee for Human Research at our institute. All patients underwent a thorough preoperative examination, were informed about the procedure, and provided written informed consent. In the preoperative holding area, baseline monitoring included pulse, non-invasive blood pressure, oxygen saturation, and electrocardiography. Five minutes before the procedure, patients received intravenous injections of 4 mg ondansetron, 0.2 mg glycopyrrolate, and 1 mg midazolam.

Patients were positioned in the Sim's position, with the operative limb placed on the upper side. A curvilinear ultrasound (US) probe of 2-5 MHz frequency was used. It was initially placed along the line joining the greater trochanter and the posterior superior iliac spine (PSIS), with the medial edge of the probe placed directly on the PSIS. The probe was then gradually moved inferomedially with the para-sacral parallel shift (PSPS)<sup>6</sup> until the posteromedial border of the ischium, with the overlying piriformis muscle, was identified. A 100 to 150 mm, 23-gauge needle was inserted in an in-plane approach from lateral to medial direction, targeting the posteromedial border of the ischium (Image 1). Upon contact with the bone, the needle tip was slightly withdrawn, and following negative aspiration for blood, 25 mL of 0.5% bupivacaine was injected. The spread of the local anesthetic under the piriformis towards the sacral plexus was confirmed via ultrasound.

The time from placement of the US probe to the end of the local anesthetic injection and needle withdrawal was  $\leq$  6 minutes for all patients. The onset of sensory

block, measured from the completion of the local anesthetic injection until the patient reported no pain from a pinprick, ranged from 9 to 12 minutes. The onset of motor block, measured from the completion of the injection until a loss of power grade  $\geq$ 1, did not reach Grade 2 in any patient. During the surgeries, hemodynamic stability was notably maintained in all high-risk cases. If patients experienced mild pain (numerical rating scale [NRS]  $\leq$ 3), 0.5 mg/kg of intravenous ketamine was administered, which could be repeated at 10-minute intervals up to two times. If further pain relief was needed, the block was considered failed, and the patient was excluded from the study. Postoperative pain was assessed using the Visual Analog Scale (VAS). At a VAS score of 5 or more, patients received 50 mg of intravenous tramadol, concluding the study at that point.

For some procedures performed in the femoral nerve sensory distribution area, an ultrasound-guided femoral nerve block was also performed. This involved the use of 5 mL of 0.5% bupivacaine and 10 mL of 2% lignocaine with adrenaline, for a total of 15 mL of local anesthetic in the adductor canal. Patients were turned supine and assessed every minute for sensory onset using the pinprick method on the dorsal and plantar aspects of the foot. Sensory block was categorized as 0 (sharp pain), 1 (dull pain), or 2 (no pain). Motor power was graded by evaluating plantar and dorsiflexion of the ankle joint as 0 (normal motor power), 1 (reduced motor power), or 2 (complete block). The final motor block was assessed at the end of 30 minutes. If the patient still experienced pain to pinprick on the dorsal aspect of the foot, the block was considered failed. Surgeon satisfaction was assessed on a scale of 1 (not satisfied, needs another type of anesthesia), 2 (partial satisfaction, needs some improvement), or 3 (complete satisfaction).



**Figure 1:** Sono anatomy of structures

Table 1:

Case	Age (years)/gender	ASA Gr.	Comorbidities	Type of Surgery	Type of block	Time to give block (min)	Sensory onset (min)	Motor block at 30 min	Need to give Inj. Ketamine	Duration of Surgery (Hrs)	Time to rescue analgesia (hrs)	Surgeon's satisfaction
1	45/F	III	Uncontrolled HTN + DM	RT BK Amputation	PIP + FEMORAL	5	9	1	No	2	10	3
2	58/M	II	HTN	Debridement	PIP	3	11	1	No	1	8	3
3	70/M	III	Uncontrolled HTN + 2D Echo changes	RT BK Amputation	PIP + FEMORAL	4	8	2	No	1.5	8	3
4	51/M	III	Uncontrolled DM	LT BK Amputation	PIP + FEMORAL	6	13	1	No	2	7	3
5	60/M	IV	Uncontrolled HTN + DM + Anemia	Debridement	PIP	4	14	1	No	1	12	2
6	75/M	III	Uncontrolled DM	RT BK Amputation	PIP + FEMORAL	5	12	1	No	1	10	3
7	58/M	IV	Uncontrolled HTN + DM	LT BK Amputation	PIP + FEMORAL	3	10	2	No	2	11	3
8	32/M	III	CKD + Anemia	Debridement	PIP	5	9	1	1 time	1.5	9	2
9	60/M	IV	DM + CKD + Anemia	Debridement	PIP	4	11	1	No	1	11	3
10	34/M	III	Sepsis + Anemia	Debridement	PIP	6	10	1	No	1	10	3

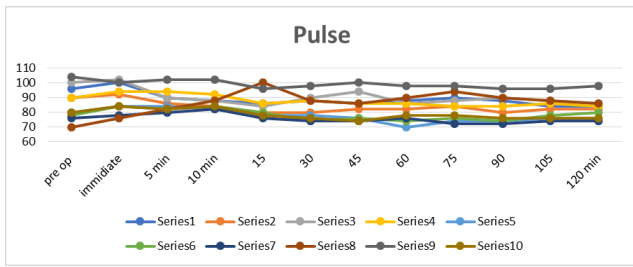


Figure 2: Heart rate

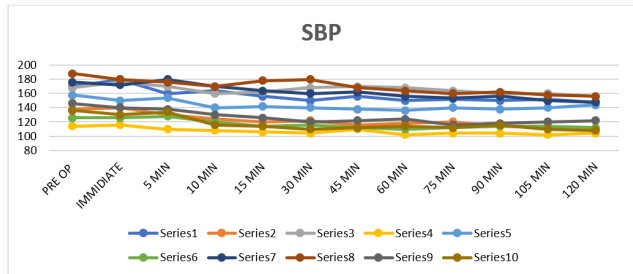


Figure 3: SBP

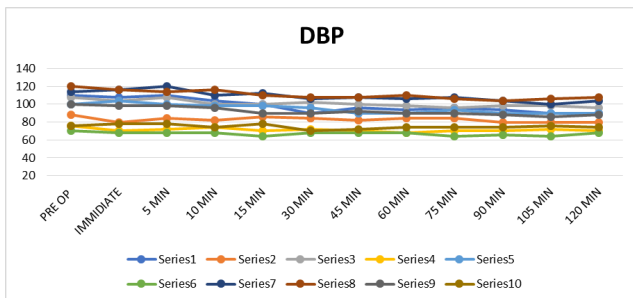


Figure 4: DBP

### 3. Results

We successfully performed the para-sacral ischial plane (PIP) block in all patients. The average time taken to perform the block was between 4 and 6 minutes (Table 1). Subjectively, the onset of analgesia was noted to be within 3 to 5 minutes. The onset of sensory block, measured by the pinprick method, was observed between 9 and 14 minutes. The onset of motor block, assessed by plantar and dorsiflexion of the ankle joint, reached a grade of 1-2 at the end of 30 minutes. The duration of surgery varied from 1 to 2 hours. The duration of the block in our study was between 8 and 12 hours. Surgeon satisfaction was reported as complete in 8 patients and partial in 2 patients.

As demonstrated in Images (2-4), there were no significant changes in hemodynamic parameters such as pulse, systolic blood pressure (SBP), and diastolic blood pressure (DBP).

### 4. Discussion

The para-sacral ischial plane (PIP) block involves the injection of a local anesthetic into a fascial plane where the sacral plexus is located. This plane is bounded anteriorly by the pelvic fascia, medially by the sacrum, laterally by the ischium, and posteriorly by the piriformis muscle. Injecting the anesthetic into the plane between the ischium and the piriformis, which is lateral to the plexus, allows the drug to spread towards and reach the sacral plexus.

This process is easily visualized on ultrasound. Since this technique does not require precise visualization of the plexus or exact needle placement, the risk of damage to neurovascular structures is minimal.<sup>7</sup> The easily visualized ischium bone with the overlying piriformis serves as a reliable endpoint, making the PIP block a technically easier block with low performance time and a high success rate.

We were able to perform the PIP block in all patients within 4-6 minutes. Compared to other blocks, it is less time-consuming, which has been confirmed by studies conducted by K M Sherfudeen et al. and Venkatraju et al.<sup>2,3</sup> We found that the onset of subjective analgesia was almost immediate in patients presenting with pain. The time to achieve sensory block was 9 to 12 minutes, comparable to the study conducted by Bansal et al.<sup>4</sup> Motor block, assessed in the sciatic nerve distribution, did not reach Grade 2 in any patient. However, since the procedures did not require muscle relaxation, the surgeries could be carried out successfully. Similar findings were observed by KM Shafudeen, where motor power was preserved in 4 out of 10 patients.<sup>2</sup>

Remarkable hemodynamic stability was observed in all our high-risk cases, as demonstrated in Images 2, 3, and 4. Intraoperative supplementation with Inj. Ketamine was needed in only one patient, a young patient with chronic kidney disease (CKD). The subsequent surgery proceeded smoothly without pain-related movement, despite the motor block being Grade 1. This technique can be used as the sole anesthetic technique for below-knee surgeries. However, since some of our procedures encroached on the femoral nerve distribution, a femoral nerve block via the adductor canal block was also needed in 5 of our patients.

None of our patients experienced any other complications intraoperatively. Postoperative recovery from the block was assessed by the time of the first analgesia request, when Inj Tramadol 50 mg was administered intravenously. The time to rescue analgesia ranged from 8 to 12 hours in our study. K M Sharfudeen, who used ropivacaine in their study, reported durations up to 24 hours in some patients.<sup>2</sup> In the rest, the findings were comparable to our study. This is a fascial plane block with surrounding structures easily identifiable on ultrasound. There is minimal likelihood of damage to neurovascular structures due to the distant needle tip placement. It can also be used in patients who have undergone below-knee

amputations, where neuromuscular stimulation may not be useful, a fact validated by Narayan et al. in their cadaveric study.<sup>8</sup>

As a secondary outcome, we sought the opinions of our surgical colleagues regarding this technique. Overall, all expressed complete satisfaction with the working conditions provided. The PIP block effectively manages tourniquet-related pain, although this was not requested by our surgeons in any patient.

### 5. Risk and Benefits

As it is a fascial plane block, there is a lesser risk of direct damage to the sciatic nerve. Since direct visualization or particular needle placement is not needed, it can be offered to obese individuals<sup>9</sup> or patients with tissue edema. Due to its associated hemodynamic stability, this block can be administered for lower limb surgeries in very high-risk cardio and respiratory-compromised patients, who may not be suitable for general anesthesia, central neuraxial techniques, or blocks with multiple injections. The prolonged postoperative analgesia significantly reduces the need for additional analgesics in these patients. Early postoperative resumption of oral intake is particularly beneficial for diabetic patients.

### 6. Conclusion

We conclude that the PIP block can be a highly valuable addition to the anesthesiologist's repertoire for use in high-risk patients undergoing lower limb surgical procedures. It is quick and easy to perform, provides satisfactory working conditions, ensures good hemodynamic stability, and offers prolonged postoperative analgesia with minimal procedural discomfort. Further evaluation of its feasibility for above-knee surgeries, including the use of other local anesthetics and adjuvants, is warranted.

### 7. Sources of Funding

None.

### 8. Conflict of Interest

None.

### References

1. Mansour NY. Reevaluating the sciatic nerve block: another landmark for consideration. *Reg Anesth.* 1993;18(5):322–3.
2. Sherfudeen KM, Sankarlal NK, Jayapal I, Kaliannan SK. Parasacral ischial plane block for lower limb wound debridement surgeries - A case series. *Indian J Anaesth.* 2022;66(12):861–4.
3. Venkataraju A, Narayanan M, Phillips S. Parasacral ischial plane (PIP) block: An easy approach to sacral plexus. *J Clin Anesth.* 2020;59:103–5.
4. Bansal L, Attri JP, Verma P. Lower limb surgeries under combined femoral and sciatic nerve block. *Anesth Essays Res.* 2016;10(3):432–6.
5. Tantry TP, Kadam D, Shetty P, Bhandary S. Combined femoral and sciatic nerve blocks for lower limb anaesthesia in anticoagulated patients with severe cardiac valvular lesions. *Indian J Anaesth.* 2010;54(3):235–8.
6. Bendtsen TF, Lönnqvist PA, Jepsen KV, Petersen M, Knudsen L, Børglum J. Preliminary results of a new ultrasound-guided approach to block the sacral plexus: The parasacral parallel shift. *Br J Anaesth.* 2011;107:278–80.
7. Cassai AD, Costa F. Editorial: Interfascial Plane Blocks. *Front Med (Lausanne).* 2022;9:962487. doi:10.3389/fmed.2022.962487.
8. Narayanan M, Phillips S, Venkataraju A, Bhoi S, Roy TS. Parasacral ischial plane (PIP) block: Cadaveric validation. *J Clin Anesth.* 2020;60:68–9.
9. Robert MS. The Parasacral Sciatic Nerve Block. *J Reg Anaesth.* 2018;p. 1–41.

### Author biography

**Parth Pandya**, Assistant Professor  <https://orcid.org/0000-0003-2269-4376>

**Sudha Shah**, Professor  <https://orcid.org/0009-0007-6002-8629>

**Yatin Bharad**, 2nd Year PG Resident  <https://orcid.org/0009-0004-0275-5367>

**Cite this article:** Pandya P, Shah S, Bharad Y. Parasacral ischial plane block for lower limb surgeries: A case series. *Indian J Clin Anaesth* 2024;11(3):426-430.