

Content available at: <https://www.ipinnovative.com/open-access-journals>

Indian Journal of Clinical Anaesthesia

Journal homepage: www.ijca.in

Case Report

Anaesthetic management of a case of Takayasu arteritis: A case report

Rachna Wadhwa^{1*}, Ehtesham Naqvi², Suman Keshav¹, Sanjula Virmani¹

¹Dept. of Cardiac Anesthesia, GIPMER- GB Pant Hospital, New Delhi, India

²Dept. of Cardiothoracic Surgery, GIPMER- GB Pant Hospital, New Delhi, India



ARTICLE INFO

Article history:

Received 25-01-2024

Accepted 08-02-2024

Available online 26-03-2024

Keywords:

Takayasu arteritis

Anaesthesia

Aorto carotid graft

ABSTRACT

Takayasu's arteritis (TA) is a rare disease characterized by chronic progressive pan-endarteritis involving large blood vessels with resultant feeble pulsations in involved arteries. Therefore, it is also referred as pulseless disease. The challenges for anaesthesia management includes uncontrolled hypertension, invasive arterial monitoring, central nervous system monitoring and end-organ dysfunction. We present successful management of a middle-aged female diagnosed with TA posted for aorto-carotid graft. The anaesthesia management and complications encountered are highlighted.

This is an Open Access (OA) journal, and articles are distributed under the terms of the [Creative Commons Attribution-NonCommercial-ShareAlike 4.0 License](https://creativecommons.org/licenses/by-nc-sa/4.0/), which allows others to remix, tweak, and build upon the work non-commercially, as long as appropriate credit is given and the new creations are licensed under the identical terms.

For reprints contact: reprint@ipinnovative.com

1. Introduction

Takayasu arteritis is a rare chronic inflammatory disease of aorta and its branches. The diffuse disease causes ischemia in multiple vital organ systems. Hallmark of this disease is the absence of pulses in the upper limbs and neck.

Anaesthesia management in these set of patients is complicated by uncontrolled hypertension, difficult IV access and monitoring and ischemia in multiple vascular beds. Along with associated comorbidities, Takayasu arteritis poses higher anaesthetic risk in these patients.

This case report discusses the perioperative anaesthetic management of a case of Takayasu arteritis posted for aorto-carotid graft surgery.

2. Case History

A 46year old female presented with complaints of headache, pre-syncope, postural giddiness on sitting position and multiple seizure episodes. Patient gave past history of eclampsia and was on anti-epileptic medications since then.

MRI Brain revealed dolichoectasia of both vertebral arteries and basilar artery with compression over medulla and 4th ventricle with resultant dilatation of both lateral and 3rd ventricles. There was prominent flow voids in left cerebellar hemisphere. She was a known case of type 2 diabetes mellitus and hypothyroid since 7-8years on medications.

On physical examination, she was overweight with weight of 73kg, 160cm height and BMI of 28.5kg/m². Upper limb pulsations were absent with only femoral artery and posterior tibial artery pulsations palpable. Left carotid bruit was present. Gaze evoked nystagmus was noted. There was decreased power of grade 4/5 in all four limbs. Airway examination showed anticipated difficult intubation with short neck, heavy jaw and Mallampati class II.

MSCT angiography of brain and neck circumferential thickening with near total occlusion of right brachiocephalic artery, >90% occlusion of left internal carotid artery and about 50% occlusion of left subclavian artery proximal to origin of vertebral artery. Takayasu arteritis was diagnosed on the basis of multiple arteries involvement clinically¹ and radiologically.²

* Corresponding author.

E-mail address: drrachnawadhwa@gmail.com (R. Wadhwa).

Her blood investigations including hemogram, renal and liver function, and serum electrolytes were normal. HbA1c was 7.5%. ESR was 25mm/hr and CRP was negative. Thyroid function test was within normal limits. ECG and Chest X-ray were normal. Patient was on oral prednisolone 60mg OD, thyroxin 50mcg OD, levetiracetam 500mg BD, inj. LMWH 0.4mg s.c OD and human mixtard insulin.

Patient was posted for aorto-carotid bypass graft surgery. Patient was premedicated with inj. Morphine 10mg and inj. Promethazine 25mg IM 1hour prior to surgery. A 22G IV cannula was secured over right forearm and ASA standard monitors attached. Her BP was recordable over left brachial artery non-invasively which was 140/78mmHg. BIS electrodes were placed with a baseline value of 70. General anaesthesia was induced with inj. Propofol 1mg/kg and inj. Fentanyl 1mcg/kg IV. Inj. Vecuronium 0.1mg/kg relaxant was used. Endotracheal intubation was achieved via McGrath video-laryngoscope with a 7.5 cuffed ET tube. Left femoral arterial line and right femoral venous lines were secured. IV line extensions were used for easy accessibility. Nasopharyngeal temperature probe was inserted. Patient was given supine position with neck extension and head rotated to right. An episode of bradycardia upto 45beats/min was noted during neck positioning which responded to atropine. Anaesthesia was maintained on oxygen (FiO₂ 0.5), nitrous oxide, sevoflurane (0.9MAC) with intermittent bolus of propofol and vecuronium to maintain BIS between 40-60, normocarbida and mean arterial pressure above 60mmHg. Warm air blower was used to maintain normothermia. Her blood pressure was noted to be labile with episodes of hypertension which was controlled using titrated sevoflurane. Surgically, due to small caliber left internal carotid artery, left saphenous vein graft was harvested and bypass was created between left internal carotid artery and arch of aorta via subcutaneous tunnel at neck. (Figure 1) Intra-operative course was otherwise uneventful and patient was shifted to post-operative intensive care unit on mechanical ventilation.

Post-operatively, patient was gradually weaned off of ventilator and extubated on postoperative day 1. She developed left LMN facial nerve and hypoglossal nerve palsy after about 24 hours in the post-operative period. All vitals were normal and clinical recovery was good. So, she was discharged on post-op day 5. Follow up showed good nerve recovery and functional improvement after 2 weeks.

3. Discussion

Takayasu or pulseless arteritis is a rare disease with an incidence of only 2-3 cases/year/million population worldwide. It affects young (<40years) and has female preponderance of about 80-90%(F:M 9:1). It is relatively more common in Asian women.³ It is chronic granulomatous inflammatory disease of thoracic aorta

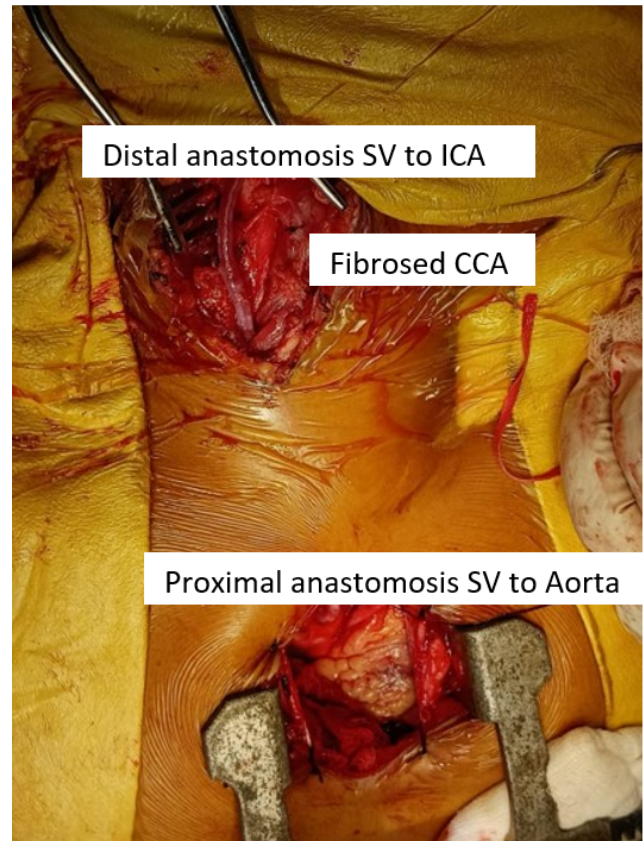


Figure 1: Image depicting ministernotomy and anastomosis in neck

and its branches, and may also involve pulmonary artery. Symptoms occur due to large vessel vasculitis such as hypertension (renal artery stenosis), aortic regurgitation (aortitis), stroke (carotid artery occlusion), claudication of the extremities and loss of peripheral pulses.³ In our case, patient presented with neurological symptoms inherent to cerebral ischemia. Although headache is a common symptom seen in 50-70% cases, convulsions are seen in only 0-20% cases.⁴ Five types have been described-Type I (only the branches of the aortic arch), type IIa (ascending aorta, aortic arch and its branches), type IIb (ascending aorta, aortic arch and its branches, and thoracic descending aorta), type III (descending thoracic aorta, the abdominal aorta and/or the renal arteries), type IV (only the abdominal aorta and/or renal arteries) and type V (combined features of Type IIb and IV).²

Our patient presented with type I Takayasu arteritis with involvement of brachiocephalic, common carotid and subclavian arteries. Diagnosis is commonly confirmed by MRI, USG and Angiography. Patients are generally on high dose steroid as in our case and at times on immunosuppressants to delay progression of the disease and help control symptoms. Other treatment modalities used are anti-tumor necrosis factor agents like infliximab, etanercept

and adalimumab, and anti-IL-6 therapy, tocilizumab.⁵ Though these agents may show clinical improvements but complete remissions are not seen. The major problems arise with dreaded complications like retinopathy, renovascular hypertension, aortic regurgitation and aneurysm.

The patients generally present to operating room for the sequel of complications. As the disease affects young females, caesarean section is other common indication.^{6,7} The challenges with respect to anaesthesia management include blood pressure measurement at various sites, monitoring organ perfusion under anaesthesia, acid-base electrolyte balance and temperature regulation. Pre-operative counseling of the patient and taking informed consent about all invasive monitoring is essential. Anaesthesia induction is usually well tolerated, but drugs should be used to avoid hypertensive response to laryngoscopy.⁸ Intra-arterial pressure monitoring is preferable and NIBP measurement in contra-lateral limb if possible. Internal jugular cannulation should be performed with ultra-sound guidance in case CVP monitoring is required. NIRS, BIS or cerebral oximetry measurement should be done if possible, especially in patients undergoing cardiac surgery with cardio-pulmonary bypass.⁹ Vascular bypass procedures and valve replacement surgeries are generally deferred till the disease becomes inactive. Once the surgical procedure is over, extubation should be slow, smooth and controlled event.

For females undergoing Caesarean section with takayasu arteritis, epidural and spinal anaesthesia are well accepted options. The essential pre-requisites are monitoring organ perfusion in such patients. Awake patients under regional anaesthesia obviates the need of NIRS and BIS monitoring.

4. Conclusion

Takayasu arteritis, is a rare disease affecting mostly young females and usually present with feeble or no pulses in upper limbs. Focused investigations are required to clinch the diagnosis. Pre-anaesthetic work-up and planning are mandatory for smooth conduct of surgical procedure. Intra-operative careful monitoring and post-operative intensive care is crux for successful outcomes after surgery.

5. Abbreviations

SV: Saphenous vein; CCA: Common carotid artery; ICA: Internal carotid artery.

6. Source of Funding

None.


7. Conflict of Interest

The patient gave written consent that her case can be sent for publication and she does not have any objection.

References

1. Arend WP, Michel BA, Bloch DA, Hunder GG, Calabrese LH, Edworthy SM, et al. The American College of Rheumatology 1990 criteria for the classification of Takayasu arteritis. *Arthritis Rheum.* 1990;33(8):1129–34.
2. Zhu FP, Luo S, Wang ZJ, Jin ZY, Zhang LJ, Lu GM. Takayasu arteritis: Imaging spectrum at multidetector CT angiography. *Br J Radiol.* 1020;85(1020):1282–92.
3. Dan K, Takahashi K, Lefor AK. Measuring and maintaining organ perfusion in a patient with Takayasu's arteritis undergoing cardiac surgery. *Anaesth Rep.* 2023;11(2):e12236.
4. Bishnoi RK, Devi S, Rai S, Gunjot. Takayasu arteritis: a comprehensive review of literature. *Int J Res Med Sci.* 2020;8(9):3418–25.
5. Rivera M. Novel Pathogenesis and Treatments for Cardiovascular Disease. [Internet]. IntechOpen; 2023. Available from: <http://dx.doi.org/10.5772/intechopen.105907>.
6. Ioscovich A, Gislason R, Fadeev A, Grisaru-Granovsky S, Halpern S. Peripartum anesthetic management of patients with Takayasu's arteritis: case series and review. *Int J Obstet Anesth.* 2008;17(4):18691876–18691876.
7. Watanabe Y, Miyata T, Tanemoto K. Current Clinical Features of New Patients With Takayasu Arteritis Observed From Cross-Country Research in Japan: Age and Sex Specificity. *Circulation.* 2015;132(18):1701–9.
8. Yoshida M, Yamamoto T, Shiiba S, Harano N, Sago T, Nunomaki M, et al. Anesthetic Management of a Patient With Takayasu Arteritis. *Anesth Prog.* 2016;63(1):31–3.
9. Han HS, Yoon KW, Heo SH, Park YJ, Kim YW, Kim DI. Aorto-carotid bypass in patients with Takayasu arteritis. *Ann Surg Treat Res.* 2017;93(3):143–51.

Author biography

Rachna Wadhwa, Associate Professor  <https://orcid.org/0000-0001-5353-0855>

Ehtesham Naqvi, Associate Professor

Suman Keshav, Senior Resident

Sanjula Virmani, Director, Professor

Cite this article: Wadhwa R, Naqvi E, Keshav S, Virmani S. Anaesthetic management of a case of Takayasu arteritis: A case report. *Indian J Clin Anaesth* 2024;11(1):112–114.