

Content available at: <https://www.ipinnovative.com/open-access-journals>

Indian Journal of Clinical Anaesthesia

Journal homepage: [www.ijca.in](http://www.ijca.in)

## Case Report

# Intra-operative neurophysiological monitoring (IONM) & its role in neurosurgeries: An exceedingly essential monitoring technique

Praveen Ramasamy<sup>1\*</sup>, Sathya Narayanan K<sup>1</sup>, Premkumar Damodaran<sup>1</sup>

<sup>1</sup>Dept. of Anaesthesiology, ESIC Medical College and Hospital, Chennai, Tamil Nadu, India



### ARTICLE INFO

#### Article history:

Received 12-05-2023

Accepted 30-12-2023

Available online 26-03-2024

#### Keywords:

Anaesthesia

Neurosurgery

Evoked potentials

Laminectomy

Neurophysiological Monitoring

Neurosurgery

### ABSTRACT

Balanced anaesthesia with intra-operative neuro monitoring (IONM) is an ideal choice for neurosurgeries wherein the functionalities of nerve has to be ascertained. The optimum goals during neurosurgeries include maintaining normothermia, hemodynamic parameters and blood loss. Neurophysiological monitoring consisting but not limited to evoked potentials originating from motor, somatosensory areas has become an indispensable tool in neurosurgeries to prevent nerve injuries and paralysis. This case describes the anaesthesia considerations in a case of laminectomy where IONM was used. The anaesthesiologist must have adequate knowledge regarding IONM to avoid interference and signal alteration due to anaesthesia. Hence, a proper teamwork is required between the anaesthesiologist, surgeon and neurophysiologist in order to provide a high-quality perioperative care and to detect and prevent neurological injuries.

This is an Open Access (OA) journal, and articles are distributed under the terms of the [Creative Commons Attribution-NonCommercial-ShareAlike 4.0 License](https://creativecommons.org/licenses/by-nc-sa/4.0/), which allows others to remix, tweak, and build upon the work non-commercially, as long as appropriate credit is given and the new creations are licensed under the identical terms.

For reprints contact: [reprint@ipinnovative.com](mailto:reprint@ipinnovative.com)

## 1. Introduction

The use of intraoperative neurophysiological monitoring (IONM) has now become the preferred method for monitoring intra-operative neurological function during surgical procedures to reduce the likelihood of nerve pathway damage.<sup>1,2</sup> The implementation of IONM has notably reduced the incidence of motor paralysis following spine and brain surgeries.<sup>3</sup> The primary objective of monitoring is to promptly alert the surgical and anaesthesia teams to potential nerve injuries, allowing for timely adjustments in management to prevent permanent neuronal damage. Three popular methods that assess different parts of the brain include electromyography studies (EMGs), somatosensory evoked potentials (SSEPs), and motor evoked potentials (MEPs).<sup>4-6</sup> The focus of treatment and individual patient characteristics, including any preexisting impairments, dictate the method of therapy. For the best

possible results, it is essential that the anaesthesiologist and the rest of the surgical team understand the basics of neuromonitoring and how it relates to anaesthesia.

## 2. Case Report

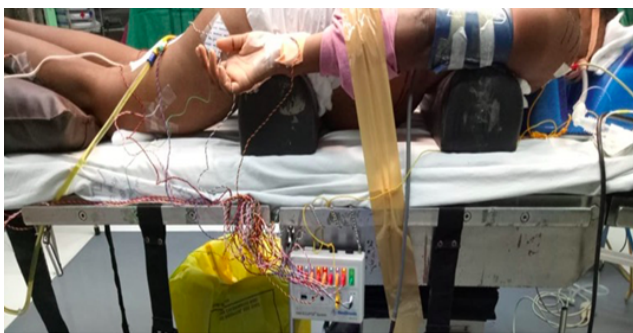A 33 years old woman came in complaining of three months of upper back pain and trouble moving both legs. A space occupying lesion affecting the spinal cord from T4 to T12 was discovered during an MRI, however routine blood checks were normal. She was posted for laminectomy and lesion excision under intra-operative neuromonitoring. A combination of intravenous and inhalational anaesthesia was used to achieve a balanced anaesthesia. After a 6-hour fasting, the patient was taken to the operating room. Standard monitors were attached, and IV glycopyrrolate 0.2 mg was administered. She was preoxygenated with 100% oxygen and induction was done with IV fentanyl 2 mg/kg, propofol 2 mg/kg and atracurium 0.5 mg/kg. Oro-tracheal intubation with a 7.0 cuffed reinforced endotracheal tube

\* Corresponding author.

E-mail address: [drpraveenramasamy@gmail.com](mailto:drpraveenramasamy@gmail.com) (P. Ramasamy).

(ETT) was done, and the patient was positioned prone for surgery. Anaesthesia was maintained with a O<sub>2</sub> and Air combination (1:1), isoflurane at 0.5 MAC, along with propofol infusion at 100 mg/kg/min, and dexmedetomidine infusion at 0.5 mg /kg/hr.

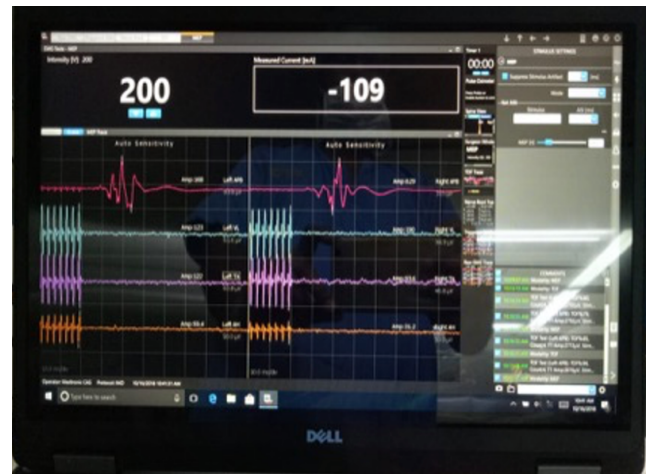Neurophysiological measurements involved monitoring SSEP using electrodes positioned over the primary somatosensory cortex. Stimulation was administered through subdermal needle electrodes placed over the posterior tibial nerve at the medial malleolus and the median nerve at the wrist. Transcranial MEPs were elicited by stimulating the motor cortex area, and compound muscle action potentials were recorded from the bilateral abductor digiti minimi (ADM), tibialis anterior, and flexor hallucis brevis as shown in Figure 1. In the supine position, intraoperative baseline sensory and motor evoked potentials were detected. MEPs exhibited favourable morphology and reproducibility as shown in Figure 2. Bilateral reproducible responses were also observed in posterior tibial and median nerves SSEPs. Following the supine recordings, the patient was repositioned prone for the surgical procedure, and baseline responses remained stable during this transition. During serial dissection, as the lesion was encountered and excision commenced, potentials were stimulated, and any variations from the baseline were examined. MEPs and SSEP responses consistently remained present and reliable in all extremities throughout the excision process. After lesion excision and achieving haemostasis, infusions were gradually weaned off and anaesthesia plane was maintained using isoflurane at 1 MAC and atracurium boluses at 0.1 mg/kg. The patient was made supine position post-surgery, and neuromuscular blockade was reversed with IV neostigmine 0.05 mg/kg and glycopyrrolate 0.1 mg/kg. She was extubated and remained hemodynamically stable. Postoperatively, she had no neurologic deficits.



**Figure 1:** SSEP and MEP monitoring being done using subdermal needle electrodes placement

### 3. Discussion

For intraoperative neuromonitoring, inhalational anaesthetic agents can have a less but still noticeable impact on



**Figure 2:** Baseline sensory and motor evoked potentials were elicited with good amplitude and morphology

waveform amplitude and latency compared to intravenous drugs. Optimal protocols for intraoperative neuromonitoring are still up for discussion. Although both intravenous and inhalational drugs reduce signal attainment, at the same MAC doses, inhalational medicines produce a more marked depression.<sup>7,8</sup> Total Intravenous Anaesthesia (TIVA) is commonly used for these procedures, either on its own or in conjunction with inhalational drugs, to create Balanced Anaesthesia (BA). Since depth of anaesthesia monitoring is important in such cases to prevent awareness, it is better to use Bispectral Index (BIS) monitoring. However, since BIS monitoring was unavailable at our institution we were not able to use it. Avoiding muscle relaxants that can impair neuromonitoring is crucial while administering anaesthesia, along with sustaining a normal core temperature, normocapnia, and hemodynamic stability (MAP 65-75 mmHg).<sup>9,10</sup> There is a window of opportunity for metabolism before neuromonitoring starts, even though neuromuscular blockers (NMBs) can be employed during intubation. Once neuromonitoring is no longer necessary, inhalational drugs like nitrous oxide (N<sub>2</sub>O) can be administered sparingly in the latter stages of operation.<sup>11</sup> To guarantee the patient's safety before and after surgery, the neuromonitoring team, anaesthesiologist, and surgeon must work together as a cohesive unit.

### 4. Conclusion

In conclusion, the case study presented highlights the pivotal role of intraoperative neurophysiological monitoring (IONM) in safeguarding neurological function during intricate surgeries. The synergy among the neuromonitoring team, anaesthesiologist, and surgeon showcased the significance of real-time collaboration. As we navigate the complexities of anaesthetic protocols, maintaining a delicate equilibrium between intravenous and inhalational agents

remains a key consideration. The evolving landscape of IONM promises continuous improvements, emphasizing the collective responsibility of the healthcare team in refining practices for enhanced patient safety. Moving forward, the integration of cutting-edge technologies and interdisciplinary collaboration will undoubtedly shape a future where neurosurgical interventions are marked by precision, safety, and improved patient outcomes.

## 5. Conflict of Interest

Nil.


## 6. Source of Funding


Nil.

## References

- Martin WH, Stecker MM. ASNM position statement: intraoperative monitoring of auditory evoked potentials. *J Clin Monit Comput.* 2008;22(1):75-85.
- Leppanen RE. Intraoperative monitoring of segmental spinal nerve root function with free-run and electrically-triggered electromyography and spinal cord function with reflexes and F-responses: a position statement by the American Society of Neurophysiological Monitoring. *J Clin Monit Comput.* 2005;19(6):437-61.
- Macdonald DB. Safety of intraoperative transcranial electrical stimulation motor evoked potential monitoring. *J Clin Neurophysiol.* 2002;19(5):416-29.
- Skinner S, Holdefer R, Mcauliffe JJ, Sala F. Medical error avoidance in intraoperative neurophysiological monitoring: the communication imperative. *J Clin Neurophysiol.* 2017;34(6):477-83.
- Vitale MG, Skaggs DL, Pace GI, Wright ML, Matsumoto H, Anderson RCE, et al. Best practices in intraoperative neuromonitoring in spine deformity surgery: development of an intraoperative checklist to optimise response. *Spine Deform.* 2014;2(5):333-9.
- Ali Z, Bithal PK. Intraoperative neurophysiological monitoring. *J Neuroanaesthesiol Crit Care.* 2015;2:179-92.
- Holdefer RN, Macdonald DB, Skinner SA. Somatosensory and motor-evoked potentials as biomarkers for postoperative neurological status. *Clin Neurophysiol.* 2015;126(5):857-65.
- Sloan TB. Anesthesia management and intraoperative electrophysiologic monitoring. In: Koht A, Sloan TB, Toleikis JR, editors. *Monitoring the Nervous System for Anesthesiologists and Other Health Care Professionals.* Switzerland: Springer; 2017. p. 317-22.
- Vaughan DJ, Thornton C, Wright DR, Fernandes JR, Robbins P, Doré C. Effects of different concentrations of sevoflurane and desflurane on subcortical somatosensory evoked responses in anesthetized, non-stimulated patients. *Br J Anaesth.* 2001;86(1):59-62.
- Pathak KS, Amaddio MD, Scoles PV, Shaffer JW, Mackay W. Effects of halothane, enflurane, and isoflurane in nitrous oxide on multilevel somatosensory evoked potentials. *Anesthesiology.* 1989;70(2):207-12.
- Peterson DO, Drummond JC, Todd MM. Effects of halothane, enflurane, isoflurane, and nitrous oxide on somatosensory evoked potentials in humans. *Anesthesiology.* 1986;65(1):35-40.

## Author biography

**Praveen Ramasamy**, Assistant Professor  <https://orcid.org/0009-0003-9924-301X>

**Sathya Narayanan K**, Assistant Professor  <https://orcid.org/0000-0002-9348-7190>

**Premkumar Damodaran**, Assistant Professor

**Cite this article:** Ramasamy P, Narayanan K S, Damodaran P. Intra-operative neurophysiological monitoring (IONM) & its role in neurosurgeries: An exceedingly essential monitoring technique. *Indian J Clin Anaesth* 2024;11(1):92-94.