



Case Report

Pneumothorax during laparoscopic plication of diaphragmatic eventration: A case report

Shrishanth Murali Kallat^{1*}, Manish Aggarwal², John M K¹

¹Dept. of Anaesthesiology, Armed Forces Medical College, Pune, Maharashtra, India

²Fortis Escorts Hospital, Faridabad, Haryana, India



ARTICLE INFO

Article history:

Received 18-05-2023

Accepted 13-09-2023

Available online 28-11-2023

Keywords:

Diaphragmatic eventration

Intra- op pneumothorax

Pneumothorax

Laparoscopy

ABSTRACT

Background: Diaphragmatic eventration is the abnormal elevation of the hemidiaphragm or part of it caused due to the lack of muscle or nerve function with normal anatomical attachments. Pneumothorax is a common occurrence during thoracoscopic approaches of diaphragmatic plication but a very rare complication in laparoscopic approaches.

Presentation of Case: A 56-year-old male presented with complaints of pain in the left upper abdomen, bloating, and difficulty in breathing. He was diagnosed with idiopathic diaphragmatic eventration and was taken up for laparoscopic plication under American society of anaesthesiologists – physical status 1. Intra-op, he developed sudden onset increase in peak pressures with poor tidal volumes and desaturation. Examination revealed reduced breath sounds and movement of left side of chest, possibly a left sided pneumothorax. The placement of a left-sided intercostal chest drain led to improvements in ventilatory parameters.

The patient was successfully extubated following the completion of surgery.

Discussion: Pneumothorax is an established complication of laparoscopic surgery, with a reported incidence of 0.01%-0.4%. But early detection and diagnosis of a pneumothorax intraoperatively is difficult and often missed because of controlled ventilation and pneumoperitoneum. A high index of suspicion should be maintained for early diagnosis and management of such conditions.

Conclusion: Intraoperative tension pneumothorax and its progression can have devastating consequences. A high index of suspicion, prompt recognition of the condition despite many factors that may mask the condition and prompt remediation leads to an effective management of such cases.

This is an Open Access (OA) journal, and articles are distributed under the terms of the [Creative Commons Attribution-NonCommercial-ShareAlike 4.0 License](https://creativecommons.org/licenses/by-nc-sa/4.0/), which allows others to remix, tweak, and build upon the work non-commercially, as long as appropriate credit is given and the new creations are licensed under the identical terms.

For reprints contact: reprint@ipinnovative.com

1. Introduction

Diaphragmatic eventration (DE) in adults is a very rare and uncommon disorder. DE is the abnormal elevation of the hemidiaphragm or part of it caused due to the lack of muscle or nerve function with normal anatomical attachments. It can be both acquired or congenital, present in both adult and pediatric age groups and may cause reduced function due to thinning of the diaphragm. In adults, it

is mostly asymptomatic and involves left diaphragm with right mediastinal shift.¹ Surgical plication is the accepted modality in symptomatic patients.

Pneumothorax is a common occurrence during thoracoscopic approach of diaphragmatic plication but a very rare complication in laparoscopic approach.² Patient-related risk factors of intraoperative pneumothorax are similar to those of spontaneous pneumothorax and include the presence of emphysematous bullae or blebs that may rupture with positive pressure ventilation.³ There is always a risk of developing pneumothorax when

* Corresponding author.

E-mail address: shrishanthmuralik@gmail.com (S. M. Kallat).

surgical manipulation involves areas close to parietal pleura, including intrathoracic surgeries, as well as central venous line placement.^{4,5} Also, pneumothorax is an established complication of laparoscopic surgery, with a reported incidence of 0.01%-0.4%.⁶ But early detection and diagnosis of a pneumothorax intraoperatively is difficult and often missed because of controlled ventilation and pneumoperitoneum.

This case report presents the anesthetic management of an adult male, a case of diaphragmatic eventration who underwent laparoscopic plication of the left hemidiaphragm and developed left pneumothorax intra-operatively.

2. Case Report

A 56-year old male presented with complaints of pain in left upper abdomen, bloating and difficulty in breathing. On examination, patient had reduced breath sounds in left infra-scapular region. On further evaluation, chest X-ray showed displacement of bowel loops with Rt mediastinal shift (Figure 1). HRCT and CECT thorax showed left diaphragmatic eventration with right trachea-mediastinal shift with displacement of part of the stomach and bowel loop in left hemithorax. 2D ECHO revealed situs solitus with levocardia with displacement to the right side.

It was diagnosed as idiopathic diaphragmatic eventration as no known cause could be identified. Patient was planned for laparoscopic plication as treatment modality. During pre-anaesthetic evaluation, he was accepted in ASA-PS I with accepted risks involved under general anaesthesia for the surgery.

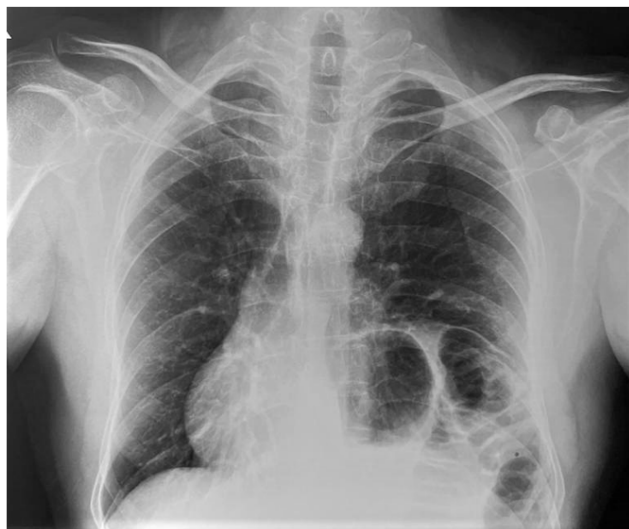

Figure 1: X-ray chest showing eventration of diaphragm with bowel loops in Lt hemithorax with Rt mediastinal shift

Standard ASA monitors were applied, and recorded baseline blood pressure was 124/78 mmHg with pulse rate 68 beats per minute. Anaesthesia was induced after pre-

oxygenation, with Inj Fentanyl 2 mcg/kg, Inj Propofol 2 mg/kg and Inj Atracurium 0.5 mg/kg. Trachea was intubated with 8.5 mm internal diameter cuffed endotracheal tube and placed on volume control mode of ventilation (VCV -tidal volume -500 ml, rate-12/min). Anaesthesia was maintained with sevoflurane, 1.2 minimum alveolar concentration and oxygen-air mixture of ratio 1:1.

Intraoperative course remained stable and uneventful until around 40 minutes into the surgery, when patient developed sudden onset reduction in tidal volume to 280-360 ml associated with raised peak pressures to limit of 35 cmH₂O, followed by mild desaturation and increased end tidal CO₂ (ETCO₂) in few minutes. FiO₂ was increased to 100%, circuit was checked for any leaks, tube position was reconfirmed and in the mean time patient was shifted to pressure control ventilation to deliver the tidal volume (Pressure support-18, Rate-20, PEEP-4). However, patient continued to generate poor tidal volumes (340-370ml) at higher peak pressures. Arterial blood gas analysis revealed pH-7.24, pCO₂-54.6mm Hg, pO₂-259.9 mm Hg, HCO₃-23 mmol/litre.

Surgery was stopped, and chest drapes were removed for auscultation. It was noted that breath sounds and movement on the left side of chest were reduced in comparison to the right side. A probable diagnosis of left pneumothorax was made, and patient was ventilated with low tidal volume and high respiratory rate. As after discussion with surgeon, it was decided to complete the surgery as it was about to finish and then place an intercostal chest drain to correct the pneumothorax.

On completion of the primary procedure, a 28 Fr chest tube was inserted into the left 4th intercostal space and connected to an underwater seal, followed by gush of air after connection. Tidal volumes improved considerably (500-560 ml) and peak airway pressures settled. An arterial blood gas analysis was repeated, which showed considerable improvement in pCO₂ and pH. Post op chest x-ray was normal (Figure 2).

Neuromuscular blockade was reversed with Inj Neostigmine 3.5mg and Inj Glycopyrolate 0.6mg. Patient was successfully extubated on being fully awake. Patient was closely observed for 15 minutes in the post operative care unit and was uneventful.

3. Discussion

Pneumothorax during general anaesthesia is a rare event, but can be potentially life threatening, especially if it develops into tension pneumothorax.⁶ In adult surgical patients, the most common aetiologies of pneumothorax include thoracic trauma or iatrogenic injuries, such as central line placement, regional block or mechanical ventilation.⁷ The tension pneumothorax during general anaesthesia manifests as changes in pulmonary compliance, increase in airway pressures, arterial hypotension, arrhythmia and hypoxia.⁸

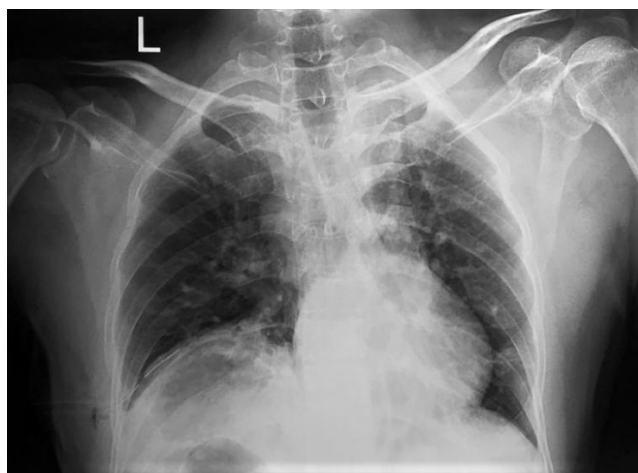


Figure 2: Chest X ray post ICD insertion with ICD in situ

Our patient being a known case of diaphragmatic eventration undergoing surgical manipulation of the diaphragm was already at a higher risk for development of such complications. Pre-operative chest X-ray did not reveal any bullae or blebs. Intubation in this case was smooth and patient was immediately placed on positive pressure ventilation. No change in lung compliance or peak pressures was noted during positive pressure ventilation or during the formation of pneumoperitoneum. Although a high index of suspicion was present, the initial tachycardia was attributed to nociceptive reflexes but the changes in peak pressure and tidal volume further gravitated towards a diagnosis of pneumothorax. However, it is uncertain whether surgical manipulation of the diaphragm or positive pressure ventilation resulted in the development of intraoperative pneumothorax.

Anaesthetic management of a case of diaphragmatic eventration is not clearly described in literature due to rarity of such cases, and due to most cases being asymptomatic.

It is known that sudden rupture of the weakened diaphragm may result from any event that leads to an increase in intra-abdominal pressure, such as coughing, straining during light anaesthesia or extubation.⁹ Thus, adequate depth of anaesthesia should be maintained in these cases to prevent any such event. Insufflation of the abdomen to create a pneumo-peritoneum for laparoscopic surgeries or surgical manipulation of the diaphragmatic eventration may lead to development of a pneumothorax.

In this case, it is rather unclear as to what may have led to the development of the pneumothorax; however, a high index of suspicion and the readiness to act quickly in the presence of such complications should be kept in cases of diaphragmatic eventration undergoing surgical procedures under general anaesthesia.

In our case, the prompt diagnosis of intraoperative pneumothorax and definitive lifesaving intra-operative

management of the condition prevented a loss of life.

4. Conclusion

Intraoperative tension pneumothorax and its progression can have devastating consequences. A high index of suspicion, prompt recognition of the condition despite many factors that may mask the condition and rapid remediation of the condition leads to an effective management of such cases.

5. Source of Funding

None.

6. Conflict of Interest


None.


References

- Chin EF, Lynn RB. Surgery of eventration of the diaphragm. *J Thorac Surg.* 1956;32(1):6–14.
- Groth SS, Rueth NM, Kast TRN, D’Cunha J, Kelly RF, Maddaus M, et al. Laparoscopic diaphragmatic plication for diaphragmatic paralysis and eventration: An objective evaluation of short-term and midterm results. *J Thorac Cardiovasc Surg.* 2010;139(6):1452–6.
- Amaniti E, Provitsaki C, Papakonstantinou P, Tagarakis G, Sapolidis K, Dalakakis I, et al. Unexpected Tension Pneumothorax-Hemothorax during Induction of General Anaesthesia. *Case Rep Anesthesiol.* 2019;2019:5017082. doi:10.1155/2019/5017082.
- Phillips S, Falk GL. Surgical tension pneumothorax during laparoscopic repair of massive hiatus hernia: a different situation requiring different management. *Anaesth Intensive Care.* 2011;39(6):1120–3.
- Parianti JJ, Mongardon N, Mégarbane B, Mira JP, Kalfon P, Gros A, et al. Intravascular Complications of Central Venous Catheterization by Insertion Site. *N Engl J Med.* 2015;373(13):1220–9.
- Cheney FW, Posner KL, Caplan RA. Adverse respiratory events infrequently leading to malpractice suits. A closed claims analysis. *Anesthesiology.* 1991;75(6):932–9.
- Hsu CW, Sun SF. Iatrogenic pneumothorax related to mechanical ventilation. *World J Crit Care Med.* 2014;3(1):8–14.
- Chen YL, Chen CY, Cheng JK. Delayed tension pneumothorax during surgery. *J Chin Med Assoc.* 2005;68(10):491–4.
- Dawson R, Ferguson CJ. Life-threatening tension pneumothorax during laparoscopic cholecystectomy. *Surg Laparosc Endosc.* 1997;7(3):271–2.

Author biography

Shrishanth Murali Kallat, Resident Anaesthesiology  <https://orcid.org/0000-0002-8964-494X>

Manish Aggarwal, Associate Consultant  <https://orcid.org/0000-0001-8497-8193>

John M K, Assistant Professor  <https://orcid.org/0000-0003-0036-3672>

Cite this article: Kallat SM, Aggarwal M, John M K. Pneumothorax during laparoscopic plication of diaphragmatic eventration: A case report. *Indian J Clin Anaesth* 2023;10(4):404–406.