



## Original Research Article

## Efficacy and safety of segmental spinal anaesthesia in laparoscopic cholecystectomy: A prospective study

Geetanjali Singhal<sup>1,\*</sup>, B. L Mathur<sup>1</sup>, A K Mathur<sup>1</sup><sup>1</sup>Dept. of Anaesthesia, JNU Medical College, Jaipur, Rajasthan, India

## ARTICLE INFO

## Article history:

Received 19-09-2022

Accepted 08-10-2022

Available online 09-03-2023

## Keywords:

Anaesthesia

Segmental

Spinal

Thoracic

Laparoscopic

Cholecystectomy

## ABSTRACT

**Background:** Laparoscopic cholecystectomy is usually conducted under general anaesthesia(GA) which has its own limitations and may be associated with certain complications. This single-arm prospective interventional study was done to assess the safety and efficacy of thoracic segmental spinal anaesthesia(TSSA) as a sole anaesthetic procedure in patients undergoing laparoscopic cholecystectomy.

**Materials and Methods:** TSSA was administered to 50 patients of the American Society of Anaesthesiologists physical status 1, 2, 3, who were scheduled for elective laparoscopic cholecystectomy (1.5 ml of 0.75% ropivacaine with dexmedetomidine 6 µg as an adjuvant was injected in one of the intervertebral spaces between T7- T12). The primary objective of the study was to evaluate the efficacy and safety of TSSA to provide complete surgical anaesthesia in terms of the total number of cases converted to GA. The data was analysed using SciPy(version 1.3.1), a statistical analysis package, in Python programming language (version 3.7.4).

**Results:** Our study revealed that TSSA provided complete surgical anaesthesia in 48 patients and in two patients there was a failure to achieve adequate sensory block and GA had to be administered. The median time for full sensory regression was 90 min and the median time for complete motor regression was 60 min. No major intraop or postop adverse event was noted.

**Conclusion:** TSSA offers safe and satisfying operating conditions for elective laparoscopic cholecystectomy. This technique practised with caution can provide a useful alternative to GA, especially in conditions where GA may have limitations.

This is an Open Access (OA) journal, and articles are distributed under the terms of the [Creative Commons Attribution-NonCommercial-ShareAlike 4.0 License](https://creativecommons.org/licenses/by-nc-sa/4.0/), which allows others to remix, tweak, and build upon the work non-commercially, as long as appropriate credit is given and the new creations are licensed under the identical terms.

For reprints contact: [reprint@ipinnovative.com](mailto:reprint@ipinnovative.com)

## 1. Introduction

Laparoscopic cholecystectomy(LC) is among the most frequent general surgical procedures. General anaesthesia (GA) has usually been considered the gold standard technique for conducting it. The associated set of problems of GA like endotracheal intubation, artificial ventilation, raised blood pressure due to the stress of pneumoperitoneum make cardio-respiratory fitness a mandatory feature.<sup>1</sup> A preliminary study on Thoracic Segmental Spinal Anaesthesia (TSSA) for LC was conducted by Van Zundert

et al. and was found successful and effective.<sup>2</sup> TSSA, with a minimal dose of local anaesthetic (isobaric), just sufficient to block the dermatomes required for a particular surgery alleviates the drawback of blocking the unwanted spinal segments causing extra sympathetic, motor, and sensory blockade.<sup>2</sup>

The primary outcome measure of the present prospective study was to evaluate the efficacy and safety of single-shot TSSA to provide complete surgical anaesthesia without GA in patients undergoing laparoscopic cholecystectomy. Efficacy was determined by the number of cases that were required to be converted to GA and safety was assessed by intraoperative and postoperative adverse effects. The

\* Corresponding author.

E-mail address: [singhalgeetanjali@yahoo.com](mailto:singhalgeetanjali@yahoo.com) (G. Singhal).

secondary outcome measures were the time of rescue analgesia, surgeon satisfaction score and patient satisfaction score.

## 2. Materials and Methods

After obtaining approval from the Institutional Ethics Committee, the study was prospectively registered with the Clinical Trials Registry of India (CTRI/2021/09/036907) and was conducted at our tertiary care centre in accordance with principles of the Declaration of Helsinki.

This single-centre, prospective, interventional study was conducted on 50 patients undergoing elective laparoscopic surgery, in the general surgery operation theatre, after obtaining written informed consent. Patients who were ASA grade 1, 2 and 3, Age 18-75 years were included in the study. Patients with BMI >37 Kg/m<sup>2</sup>, active cholecystitis, choledocholithiasis, electrocardiographic changes like sinus bradycardia and heart block, contra-indications to spinal anaesthesia like bleeding diathesis and local infection, vertebral column deformity, on  $\alpha$ -adrenergic blockers, psychiatric disorders or neurological diseases were excluded from the study. A sample size of 50 was taken to ensure that the expected number of observations per category throughout our analysis was well over the minimum data required for reliable chi-squared tests and to increase generalizability of our results.

The pre-anaesthetic check-up was done, written informed consent was taken and patients were counselled about the procedure one day prior to surgery. They were reassured that their discomfort or anxiety would be managed by the administration of systemic medication or GA if the need arose. Similarly, surgeons were reassured that they could ask for GA if at any point during the surgery they felt that the anaesthetic technique was posing technical difficulty.

Patients were kept fasting as per standard guidelines. After establishing monitoring (electrocardiogram, pulse oximetry, non-invasive blood pressure, respiratory rate and end-tidal carbon dioxide), baseline vitals were noted and an intravenous line was secured with a 20 gauge cannula. Pre-loading was started at this juncture with Ringer lactate (10 ml/kg in approximately 15 minutes). Premedication with glycopyrrolate 0.2 mg, ondansetron 4 mg, fentanyl 50  $\mu$ g and midazolam 1 mg was given systemically. Under all aseptic precautions, TSSA was given by midline approach in one of the intervertebral spaces between T7 to T12 spines, with the patient in a sitting position. If the midline approach posed a difficulty, then paramedian approach was tried. The spinal was given very cautiously, with a 25 G Quincke spinal needle, until loss of resistance was felt. Once the flow of clear CSF was established, injection ropivacaine 0.75% (isobaric), 1.5 ml, along with injection dexmedetomidine 6  $\mu$ g, (as adjuvant), was injected into the subarachnoid space. The patient was subsequently made to lie supine. Maximum

3 attempts at dural puncture were taken in a patient due to ethical concerns, after which it was decided that the procedure would be carried out under GA.

All patients received oxygen via Hudson's mask at the flow rate of 5 l/min. Time of anaesthesia was recorded. Vital parameters were recorded every minute for 15 minutes and every 5 minutes thereafter. Upper and lower levels of sensory block were assessed by pinprick every 1-2 min until minimum block levels between T7 to L1 were achieved. This was noted as the time of onset. At this point in time, the motor block was evaluated according to the modified Bromage scale. (0-able to lift extended leg, 1- just able to flex knee, 2-no knee movement and some ankle movement, 3- complete lower limb paralysis). Once the onset of block was established surgery was commenced using carbon dioxide insufflation. Injection ketamine 30 mg intravenously(iv) was administered at this juncture to ease the sensory discomfort of abdominal distension to the central part of the diaphragm. The pressure limit of intra-abdominal pressure(IAP) was kept at 12 mm Hg. Injection ketamine was repeated in aliquots of 20 mg iv when slight head turning/hand movement was observed. Intraoperative adverse events(bradycardia, hypotension etc) were recorded and managed. Bradycardia (HR<55) was treated with injection atropine 0.6mg (iv) and hypotension (Systolic BP<80 mm Hg) was managed with 6mg boluses of Injection mephentermine and fast (iv) fluids. Drugs and fluids administered were noted. The intraoperative fluid used was ringer lactate at the rate of approximately 25ml/min. The rate of infusion was increased during hypotension. In the end, the duration of surgery was noted.

In the recovery room, vital parameters, sensory and motor block were noted every 15 min until the block regressed completely. Pain scoring was done as per the Visual Analogue Scale(VAS). Time of onset of postoperative pain (at VAS 3) was recorded. Injection Diclofenac 75 mg was administered in the infusion at this point.

Postoperative side-effects in the form of shoulder pain, nausea, vomiting, urinary retention, headache, backache were noted and managed on day 0, day 1 and day 2. Patients were discharged on Day 2 as per the hospital protocol. An overall procedure satisfaction score was established individually for surgeon and patient based on 5 robust scoring criteria to evaluate the success of the procedure.

Patient Satisfaction Score (Absence of each of the following complaints was given 1 point):

1. Postoperative pain
2. Awareness during surgery
3. Postoperative nausea vomiting
4. Postoperative urinary retention
5. Headache/backache

Surgeon Satisfaction Score (Presence of each of the following was given 1 point):

1. Adequate relaxation during surgery
2. Absence of intraoperative movements
3. Absence of conversion to GA
4. No postoperative side-effects
5. Timely discharge from hospital

The data was analyzed using SciPy (version 1.3.1), a statistical analyses package, in Python programming language (version 3.7.4). The description of continuous variables is provided as median with range(min, max) since means are more sensitive to outliers. The qualitative data is expressed in absolute numbers and percentages. The hypothesis testing was performed on qualitative data and for this purpose, Chi-squared tests and Fischer's exact tests were used as per requirements and a P-value <0.05 was considered significant.

### 3. Results

A total number of 50 patients were included in the study. All 50 patients were allocated to intervention with TSSA. No patients were excluded in the follow-up period. The intervention was successful in 48 patients as two patients showed inadequate sensory blockade. Hence, 48 patients were subjected to further analysis as shown in the consort diagram (Figure 1).

Laparoscopic cholecystectomy was performed by eight different surgeons. The demographic details of all study patients were comparable. (Figure 2)

The detailed data about the spinal procedure (puncture site, number of patients) is shown in Figure 3.

The median time of onset of action of adequate sensory block was 5 min (range 1-12 min). The median duration of surgery was 50 min (range 30-120 min). One surgery lasted for 120 min and GA had to be administered after 90 min. One laparoscopic cholecystectomy had to be converted to open surgery but was continued in segmental spinal anaesthesia very smoothly.

Figure 4 shows the upper and lower dermatomal block levels achieved with various levels of dural puncture.

The motor blockade achieved as per the modified Bromage scale of 2:1:0 was noted in 19:24:5 number of patients. The median time for full sensory regression was 90 min (range 60-110min). The median time for complete motor regression was 60 min (range 0-90 min).

An initial dip (at 5 min) in systolic blood pressure (SBP), diastolic blood pressure (DBP) and heart rate (HR) were noted in all 48 patients (Figure 5).

Intra- op hypotension was noted in 16 patients and was easily managed by giving small boluses (6 mg) of mephentermine and increasing the fluid infusion rate. A median 1200 ml of intraoperative Ringer (range 1000ml – 2000 ml) was infused during surgery to every patient. Bradycardia was noted in three patients and was managed easily with intravenous 0.6mg of Atropine.

All patients maintained a respiratory rate >12/min at all times. The oxygen saturation of all the patients was maintained >95%, except one patient who desaturated to 91% due to a hypotensive episode and recovered with oxygenation and fast fluids. It is noteworthy that this particular patient had two episodes of intraoperative hypotension and was on beta-blocker + amlodipine combination for his pre-existing hypertension. Besides this, no other patient showed any evidence of untoward respiratory events.

In conclusion of intraoperative adverse events, hypotension was observed in 16 patients, bradycardia in three patients, and desaturation in one patient. (Figure 6)

Injection ketamine (30mg), systemically, was given to all 48 patients at the time of pneumoperitoneum. A second dose of ketamine (20mg) was used in 24 patients as mild head/hand movements were observed in them.

Median time of rescue analgesia (VAS 3) was 300min (range 180—540 min). In 40 patients, the location of pain was the right subcostal region. Diffuse pain all over the abdomen was experienced by 10 patients. Three patients also complained of pain in the right shoulder region.

Postoperative side-effects (Figure 6) were of minor degree and manifested as PONV, urinary retention, shoulder pain, backache, and headache in a small number of patients.

Out of the 50 patients that received intervention, one patient had PDPH for which he was advised bed rest, increased fluid intake and analgesics and was discharged on Day 4 (after 24 hours of observation) and another patient was delayed for surgical reasons (a day later) while the remaining 48 patients were discharged on day 2 which was as per the hospital protocol. The patient with PDPH was completely pain-free on his first follow-up visit.

For the 48 patients evaluated, the patient satisfaction score was 4/5 in 12 and 5/5 in 36 patients. The surgeon satisfaction score was 4/5 in eight patients and 5/5 in 40 patients.

### 4. Discussion

In this prospective trial, TSSA, in the appropriate thoracic segment, produced sufficient sensory and motor block to allow laparoscopic cholecystectomy. The onset of action was immediate. Since only the required segments were blocked, there were limited haemodynamic fluctuations. After an initial dip in systolic and diastolic blood pressure and the heart rate, the haemodynamics remained mostly stable. There were no major intraoperative adverse events. No neurological complications or any other major postoperative side-effects were noted. There was no delay in the functional recovery and most patients could be discharged on time. Hence, our study demonstrated the safety and efficacy of TSSA in laparoscopic cholecystectomy.

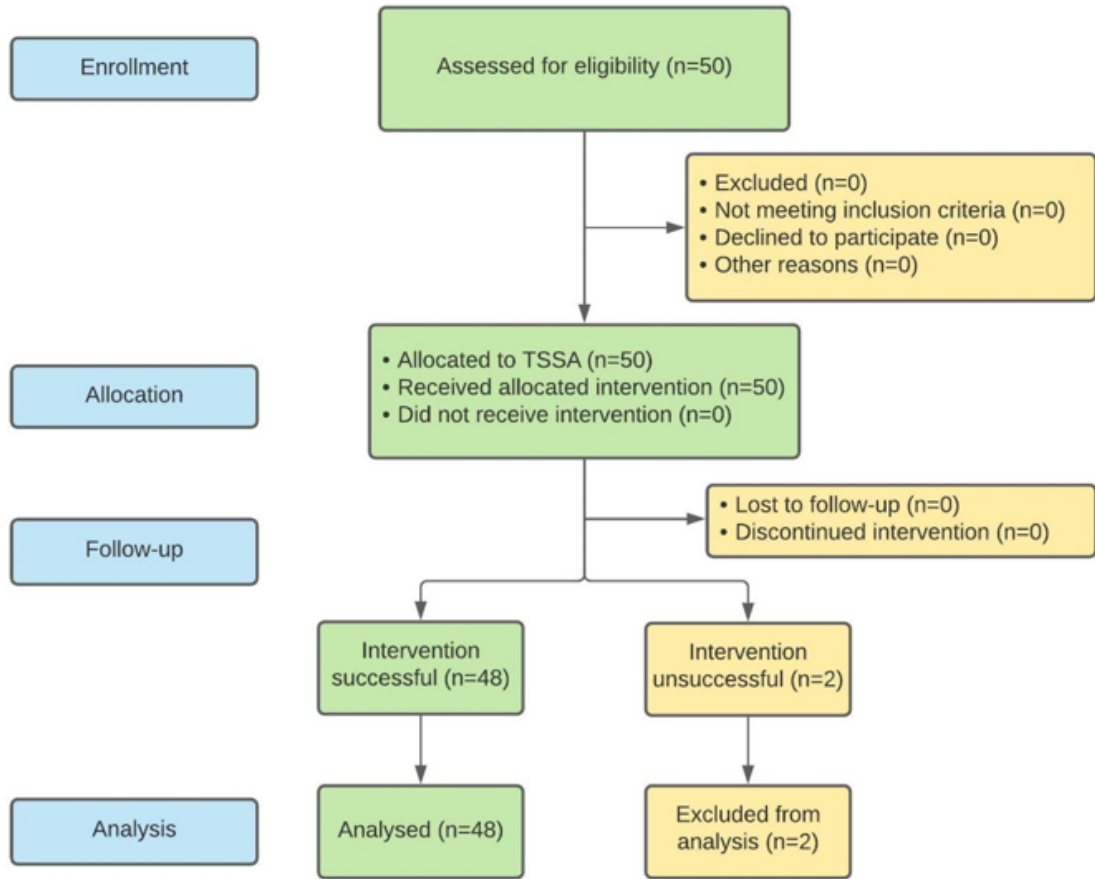


Fig. 1: Consort flow diagram thoracic segmental spinal anaesthesia

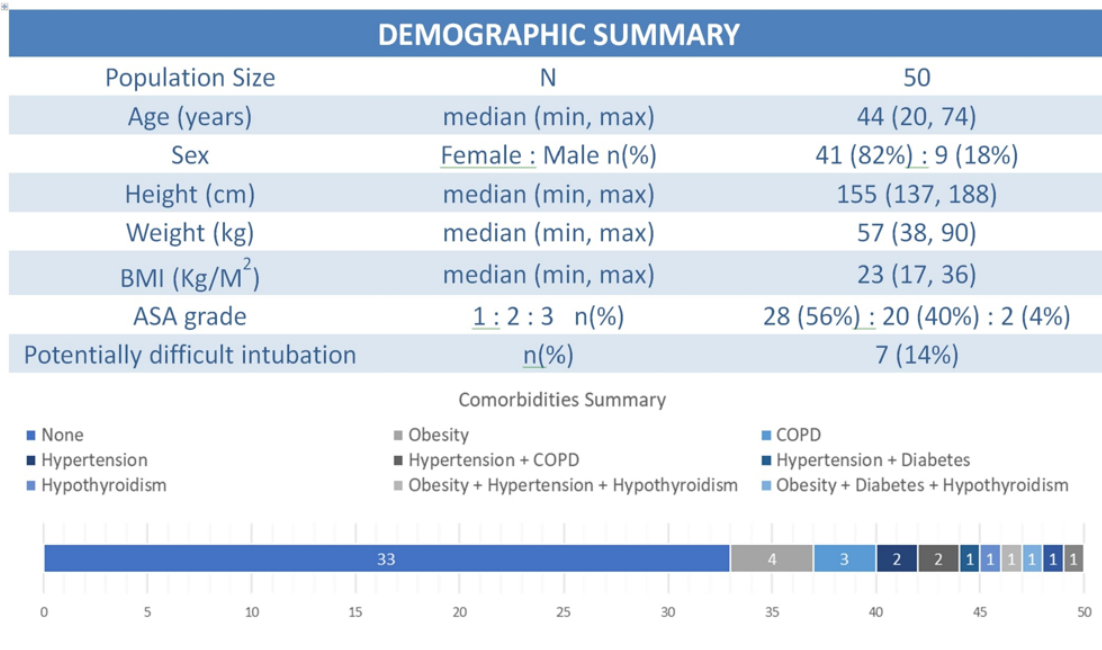
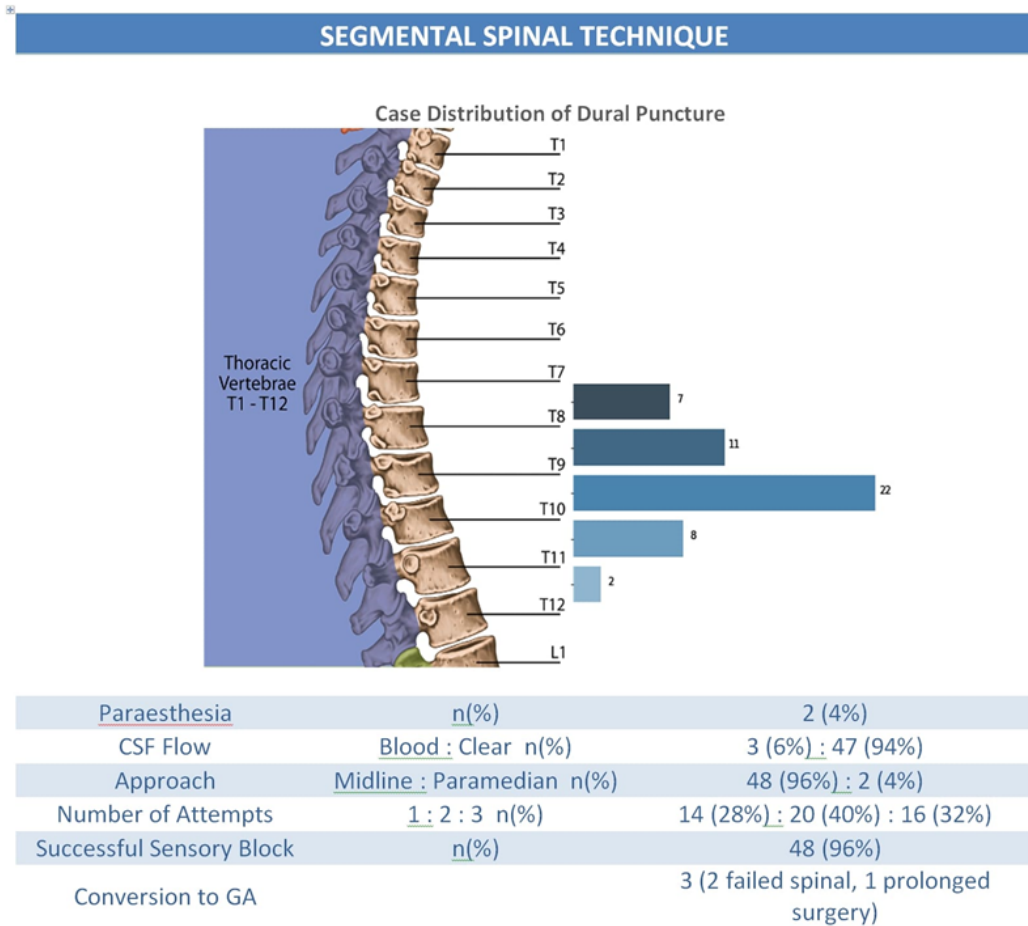


Fig. 2: Demographic data and comorbidities summary of the study patients



**Fig. 3:** Case distribution of dural puncture and procedure data

		Upper Block Level					
		T3	T4	T5	T6	T7	T8
Dural Puncture Level	T 7-8	1	0	6	0	0	0
	T 8-9	2	2	6	1	0	0
	T 9-10	1	9	7	3	0	1
	T 10-11	0	3	3	1	0	0
	T 11-12	0	0	0	1	1	0

		Lower Block Level				
		L1	L2	L3	L4	L5
Dural Puncture Level	T 7-8	0	5	2	0	0
	T 8-9	0	5	2	3	1
	T 9-10	3	7	8	3	0
	T 10-11	1	5	0	1	0
	T 11-12	0	0	2	0	0

**Fig. 4:** Level of dural puncture against the level of dermatomal block

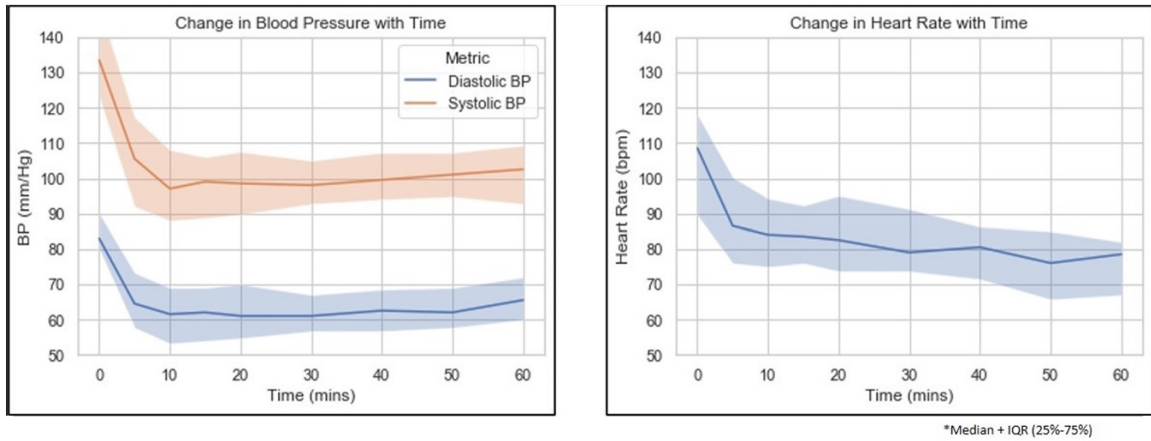


Fig. 5: Intra-operative hemodynamic changes

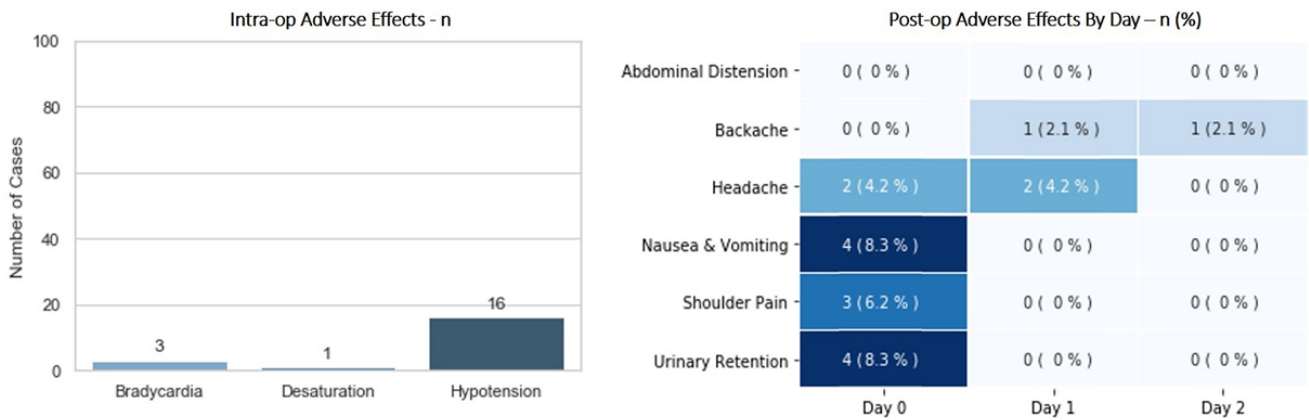


Fig. 6: Intra-operative and post-operative side effects

There have been reports of successful use of TSSA for LC. Zundert et al. were the first to conduct a feasibility study of TSSA for LC.<sup>2</sup> This study was solely confined to TSSA in healthy patients of ASA grades 1 and 2. However, TSSA has been successfully administered in the past in patients with severe lung disease.<sup>3,4</sup> In the present study, the patients belonged to ASA grading 1,2 and 3 and 17 patients had comorbidities like diabetes mellitus, hypertension, COPD, hypothyroidism, obesity and anaemia. Seven patients fell in the category of anticipated difficult intubation. The present study showed that with TSSA, one could bypass the complications of GA.

Laparoscopic cholecystectomy under GA has its own limitations, especially in cardio-respiratory unfit patients and in patients presenting with intubation difficulty. Previous studies compared TSSA and GA and concluded that TSSA provides better hemodynamic stability without much vasopressor use, early ambulation and discharge and increased patient satisfaction.<sup>5,6</sup>

There have also been studies of laparoscopic cholecystectomy under lumbar spinal anaesthesia using hyperbaric local anaesthetic drugs. This entails extensive sympathetic blockade leading to dangerous hypotension as opposed to TSSA in which only targeted spinal segments are blocked with isobaric local anaesthetic drugs and there is minimal haemodynamic fluctuation.<sup>7</sup>

The studies on TSSA have reported the absence of neurological complications. This can be attributed to the results based on MRI studies which revealed that the distance between the spinal cord and duramater at T2 level was 5.19mm, at T5 level was 7.75mm and at T10 level was 5.88mm. MRI studies also show that at thoracic level the spinal cord lies more anteriorly than at cervical and lumbar levels, giving a larger space. Furthermore, the angled spinous processes of thoracic vertebra allow the entry of the spinal needle at an acute angle, giving the advantage of increased distance between the posterior dura and spinal cord.<sup>8-10</sup>

Another major concern with TSSA is that a high thoracic blockade could block the intercostal nerves which innervate the intercostal muscles that assist breathing. This concern is laid to rest by the fact that the diaphragm, which is the key muscle of inspiration, is spared as it derives its complete motor nerve supply from C3, C4, C5 segments. Hence, the respiration is not affected and the patient can breathe comfortably. The intercostal muscles, which are the muscles mainly used in forced expiration, are not affected much because the motor blockade in TSSA is very minimal and transient.<sup>6,11</sup>

The third point of concern is the fact that the cardio accelerator nerve fibres arise from T1-T4 segments and a high neuraxial block could lead to serious bradycardia due to vagal preponderance. This however does not happen as the lumbosacral nerves are spared and there is no pooling of blood in the lower limbs. Because of this, the right atrial filling is maintained and the chronotropic stretch receptors located in the right atrium and great veins maintain the heart rate.<sup>2</sup>

It has been found that approximately 1 ml of isobaric drug spreads about 3–4 segments above and below the site of injection.<sup>12</sup> Studies reveal that the total amount of CSF in thoracic segments is lesser than in lumbar and cervical segments and the thoracic nerve roots are much thinner. Therefore, there is less dilution of local anaesthetic per segment and the thinner nerve rootlets are easily blocked. This reduces the latency and the onset of action is almost immediate as seen in the present study. Also, TSSA can be achieved with half the dose of LA used in the lumbar region.<sup>13,14</sup> The lower dose of local anaesthetic in segmental spinal gives the advantage of minimal haemodynamic fluctuations, minimal thoracic motor block and a transient lumbar motor block. The minor lumbar motor block is due to the little diffusion of the isobaric drug into the lumbar canal. The limited motor block allows early recovery and early voiding after surgery. Since laparoscopic surgeries do not require much relaxation, and a dense block is not needed, isobaric drugs are preferred in low doses. Lower doses usually block sensory nerves in preference to motor nerves. Moreover, since the spread is not affected by gravity, table tilts during laparoscopic surgery do not affect its spread.<sup>15</sup>

The lower lipophilicity of ropivacaine limits its penetration into the larger myelinated motor fibres. This results in a reduced motor blockade and a preferential sensory blockade.<sup>16,17</sup> This property makes it a useful drug in surgeries like laparoscopic cholecystectomy, where muscle relaxation is not so important. The addition of an adjuvant, dexmedetomidine, a highly selective alpha 2 adrenergic receptor agonist, prolonged the duration of postop analgesia considerably.<sup>18–20</sup> Studies have revealed that the addition of dexmedetomidine to ropivacaine could extend the duration and improve the quality of analgesia.<sup>21,22</sup>

Besides the small sample size, limitations of our study included the fact that a fixed dose of local anaesthetic was used in all patients. The correlations of dose with age, sex, height and BMI needs more evaluation. Also, the ideal level of dural puncture for LC needs further evaluation.

## 5. Conclusions

The efficacy and safety of TSSA for laparoscopic cholecystectomy was established by uneventful surgery and timely functional recovery leading to the timely discharge of patients from the hospital, greater patient-surgeon satisfaction scores, and a reduced chance of acquiring infections.

### 1. What is known

- (a) Laparoscopic cholecystectomy can be performed under segmental spinal anaesthesia in patients who may be unfit for GA.

### 2. What is new

- (a) There are negligible intraoperative and postoperative side-effects of laparoscopic cholecystectomy under segmental spinal anaesthesia.
- (b) Caution is to be observed in patients taking two or more anti-hypertensive drugs as they may have episode of prolonged hypotension with need for vasopressor support.

## 6. Source of Funding

None.

## 7. Conflict of Interest

None.


## References

1. Yu G, Wen Q, Qiu L, Bo L, Yu J. Laparoscopic cholecystectomy under spinal anaesthesia vs. general anaesthesia: a meta-analysis of randomized controlled trials. *BMC Anesthesiol.* 2015;15:176.
2. Zundert AAV, Stultiens G, Jakimowicz JJ, Peek D, Ham W, Korsten HHM, et al. Laparoscopic cholecystectomy under segmental thoracic spinal anaesthesia: a feasibility study. *Br J Anaesth.* 2007;98(5):682–6.
3. Zundert A, Stultiens G, Jakimowicz JJ, van den Borne B, van der Ham W. Segmental spinal anaesthesia for cholecystectomy in a patient with severe lung disease. *Br J Anaesth.* 2006;96(4):464–6.
4. Hobaika ABS. Thoracic spinal anaesthesia for gastrostomy in a patient with severe lung disease. *Acta Anaesthesiol Scand.* 2007;51:783.
5. Ellakany M. Comparative study between general and thoracic spinal anaesthesia for laparoscopic cholecystectomy. *Egypt J Anaesth.* 2013;29(4):375–81.
6. Paliwal NW, Ingle J, Lawhale S, Dhakulkar A. Segmental spinal vs general anaesthesia in patients undergoing laparoscopic cholecystectomy: A comparative study. *MedPulse Int J Anesthesiol.* 2020;14:77–81.
7. Imbelloni LE. Spinal anaesthesia for laparoscopic cholecystectomy: Thoracic vs. Lumbar Technique. *Saudi J Anaesth.* 2014;8(4):477–83.



8. Imbelloni LE, Gouveia MA. Low Incidence of neurologic complications during thoracic epidurals: anatomic explanation. *AJNR Am J Neuroradiol*. 2010;31(10):E84.
9. Lee RA, Zundert AAV, Botha CP, Lataster LM, Zundert TCV, Ham W, et al. The anatomy of the thoracic spinal canal in different postures: a magnetic resonance imaging investigation. *Reg Anesth Pain Med*. 2010;35(4):364–9.
10. Imbelloni LE, Pitombo PF, Ganem EM. The Incidence of Paresthesia and Neurologic Complications after Lower Spinal Thoracic Puncture with Cut Needle Compared to Pencil Point Needle. Study in 300 Patients. *J Anesth Clin Res*. 2010;1:106.
11. Sinha R, Gurwara AK, Gupta SC. Laparoscopic surgery using spinal anesthesia. *JSLs*. 2008;12(2):133–8.
12. Imbelloni LE, Gouveia MA. A comparison of thoracic spinal anesthesia with low-dose isobaric and low-dose hyperbaric bupivacaine for orthopedic surgery: A randomized controlled trial. *Anesth Essays Res*. 2014;8(1):26–31.
13. Hogan QH, Prost R, Kulier A, Taylor ML, Liu S, Mark L. Magnetic resonance imaging of cerebrospinal fluid volume and the influence of body habitus and abdominal pressure. *Anesthesiology*. 1996;84(6):1341–9.
14. Hogan Q. Size of human lower thoracic and lumbosacral nerve roots. *Anesthesiology*. 1996;85(1):37–42.
15. Uppal V, Retter S, Shanthanna H, Prabhakar C, Mckeen DM. Hyperbaric Versus Isobaric Bupivacaine for Spinal Anesthesia: Systematic Review and Meta-analysis for Adult Patients Undergoing Noncesarean Delivery Surgery. *Anesth Analg*. 2017;125(5):1627–37.
16. Kuthiala G, Chaudhary G. Ropivacaine: A review of its pharmacology and clinical use. *Indian J Anaesth*. 2011;55(2):104–10.
17. Krishnadas A, Suvarna K, Hema VR, Taznim M. A comparison of ropivacaine, ropivacaine with tramadol and ropivacaine with midazolam for post-operative caudal epidural analgesia. *Indian J Anaesth*. 2016;60(11):827–32.
18. Anand VG, Kannan M, Thavamani A, Bridgit MJ. Effects of dexmedetomidine added to caudal ropivacaine in paediatric lower abdominal surgeries. *Indian J Anaesth*. 2011;55(4):340–6.
19. Nayagam HA, Singh NR, Singh HS. A prospective randomised double blind study of intrathecal fentanyl and dexmedetomidine added to low dose bupivacaine for spinal anesthesia for lower abdominal surgeries. *Indian J Anaesth*. 2014;58(4):430–5.
20. Gurajala I, Thippampall AK, Durga P, Gopinath R. Effect of perineural dexmedetomidine on the quality of supraclavicular brachial plexus block with 0.5% ropivacaine and its interaction with general anaesthesia. *Indian J Anaesth*. 2015;59(2):89–95.
21. Gupta R, Bogra J, Verma R, Kohli M, Kushwaha JK, Kumar S. Dexmedetomidine as an intrathecal adjuvant for postoperative analgesia. *Indian J Anaesth*. 2011;55(4):347–51.
22. Sharma B, Rupal S, Swami AC, Lata S. Effect of addition of dexmedetomidine to ropivacaine 0.2% for femoral nerve block in patients undergoing unilateral total knee replacement: A randomised double-blind study. *Indian J Anaesth*. 2016;60(6):403–8.

### Author biography

**Geetanjali Singhal**, Associate Professor  <https://orcid.org/0000-0003-4598-6427>

**B. L Mathur**, Professor

**A K Mathur**, Professor

**Cite this article:** Singhal G, Mathur BL, Mathur AK. Efficacy and safety of segmental spinal anaesthesia in laparoscopic cholecystectomy: A prospective study. *Indian J Clin Anaesth* 2023;10(1):3-10.