



Original Research Article

A prospective, randomised, double blind study comparing dexamethasone and dexmedetomidine as adjuvants to 0.2% ropivacaine for post-operative analgesia in ultrasound guided brachial plexus block

Ishita Garg¹, Niti Gulati^{2,*}, Divesh Arora³¹Asian Institute of Medical Sciences, Faridabad, Haryana, India²Amrita Hospital, Faridabad, Haryana, India³Dept. of Anaesthesia & OT Services, Asian Institute of Medical Sciences, Faridabad, Haryana, India

ARTICLE INFO

Article history:

Received 09-09-2022

Accepted 15-09-2022

Available online 15-11-2022

Keywords:

Ultrasound guided

Brachial plexus block

Adjuvants

Post-operative analgesia

Dexamethasone

Dexmedetomidine

ABSTRACT

Background and Aims: The Adjuvants added to local anaesthetic increases the duration of post-operative analgesia and decreases the analgesic requirement in post-operative period. The study was conducted with the intent of comparing post-operative analgesic effect of Dexamethasone and Dexmedetomidine in ultrasound guided Brachial Plexus Block.

Materials and Methods: A prospective, randomised, double blind study to compare post-operative analgesic effect of Dexamethasone and Dexmedetomidine as adjuvant to 0.2% Ropivacaine in Ultrasound Guided Brachial Plexus Block. 60 patients belonging to ASA I and ASA II scheduled for upper limb surgeries were included in the study after taking informed consent. Group A received 20ml of 0.2% Ropivacaine with 8mg of Dexamethasone. Group B received 20ml of 0.2% Ropivacaine with 50 µg of Dexmedetomidine. Our primary objective was to compare the time to first request for analgesia in both the groups. Secondary objective was to compare duration of sensory and motor block in post-operative period and to compare overall requirement for analgesia in 24 hours in both the groups.

Results: The mean duration of motor block in Dexamethasone group was 635.47 ± 26.29 minutes and in Dexmedetomidine group was 827.47 ± 54.62 minutes. Similarly, mean duration of sensory block was 681.5 ± 27.19 minutes in Dexamethasone group and 877.17 ± 52.85 minutes in Dexmedetomidine group. The mean duration of time to first rescue analgesic was 709.67±18.47 minutes in dexamethasone group and 910.2 ± 51.66 minutes in Dexmedetomidine group. Total analgesia given had significant statistical difference of 0.004 between the two groups, with mean of 1.23 ± 1.17 in Dexamethasone group and 0.4 ± 0.56 in Dexmedetomidine. However, at 2hr, 4hr, 8hr, 12hr, 18hr and 24 hr the difference in VAS scores was significant (p value <0.0001).

Conclusion: Dexmedetomidine is better than Dexamethasone in prolonging duration of analgesia of the Brachial plexus block.

This is an Open Access (OA) journal, and articles are distributed under the terms of the [Creative Commons Attribution-NonCommercial-ShareAlike 4.0 License](https://creativecommons.org/licenses/by-nc-sa/4.0/), which allows others to remix, tweak, and build upon the work non-commercially, as long as appropriate credit is given and the new creations are licensed under the identical terms.

For reprints contact: reprint@ipinnovative.com

1. Introduction

The Adjuvants added to local anaesthetics increase the duration of local anaesthetic effect; with use of adjuvants,

one can extend patient care in the form of extended post-operative analgesia, ensure compliance of patient with physiotherapy and early mobilization of patient with stable hemodynamic variables. Brachial Plexus Blocks with adjuvants have widened the scope of anaesthesia care for painful upper limb surgeries. Ultrasound guided

* Corresponding author.

E-mail address: adinonu2212@gmail.com (N. Gulati).

peripheral nerve blocks techniques have made things easier, safer and better with real time visualisation of peripheral nerves, the block needle, and local anaesthetic distribution. This eventually leads to long term analgesia with reduced number of complications. We chose Dexamethasone and Dexmedetomidine as adjuvants to Ropivacaine for Ultrasound Guided brachial plexus block.

2. Materials and Methods

After ethical committee approval and written informed consent, a double-blind randomized prospective clinical study was carried out on 60 (30 patient each) ASA I and II patients of either sex, aged 18–60 years, undergoing orthopaedic surgeries on the upper limb under general anaesthesia with ultrasound guided brachial plexus block for post-operative analgesia. The patients were randomly assigned using sealed envelope system to one of the following groups

2.1. DEXA group

8ml of 0.5% Ropivacaine +8 mg Dexamethasone (2ml +10 ml normal saline (DEXA).

2.2. DEX group

8ml of 0.5% Ropivacaine+50 mcg Dexmedetomidine (0.5 ml Dexmedetomidine+ 1.5ml of Normal Saline) + 10ml Normal Saline (DEX).

2.3. Exclusion criteria

Patient refusal, patient with history of bleeding disorder or on anticoagulant therapy, patient with local infection at site of block, patient with known allergy to local anaesthetic drugs, ASA Grade III and IV patients, pregnant females.

After the patient was wheeled inside the operation theatre, pulse oximeter, ECG, non-invasive blood pressure monitors were connected, and intravenous fluid started. Pre-medication was done with injection Fentanyl 2 mcg/kg i.v. and injection Ondansetron 4mg i.v. Induction done by using injection Propofol 2 mg/kg i.v. and 0.08 mg/kg i.v. Vecuronium. After jaw relaxation I-Gel of adequate size was inserted. Maintenance was done using 50% Oxygen and 50% Air with Desflurane titrated to a MAC value of 0.8. Ultrasound guided brachial block was given after conclusion of surgery and before reversal of anaesthesia.

Interscalene brachial block- Patient was positioned supine with head slightly elevated and turned towards opposite side of the block. The operator is on the side of operative limb with ultrasound machine on opposite side of the patient. A High frequency linear probe (8-13 MHz) was used to scan the neck transversely between the level of cricoid cartilage and supraclavicular fossa. At the interscalene level, the brachial plexus roots often appear as

hypochoic nodules arranged like peas in a pod between the anterior and middle scalene muscles.

Supraclavicular brachial block- A linear ultrasound high-frequency probe was kept above the clavicle to scan the supraclavicular fossa in a coronal-oblique plane, to obtain the relevant short-axis view of the subclavian artery, first rib, pleura, and closely packed nerve plexus, which were typically seen as a bunch of grapes lying cephalo-dorsally to the subclavian artery. Block needle was inserted using an in-plane technique and desired volume was injected.¹

Post-operative pain assessment was done by using Visual Analogue Scale. In our study, rescue analgesic was given on first request for analgesia (VAS score>3) Inj Diclofenac 75 mg iv was given and if there was no relief in 30 minutes then Inj Paracetamol 1gm iv was given. Post-operative Heart Rate, Systolic and Diastolic Blood Pressure, Visual Analog Scale score and analgesia administered were recorded by independent anaesthesiologist at 0- hour, 2-hour, 4-hour, 8-hour, 12-hour, 18-hour, 24-hours. 24-hour analgesia consumption was recorded. The duration of analgesia was taken as time for first request by the patient for analgesic (when VAS >3) and rescue analgesia was given. The duration of sensory block was taken as time of appearance of skin sensation to pin prick. Motor block was taken as time to complete reversal of motor functions. Total analgesia given was calculated with reference to number of times there was need for analgesia in post-operative 24 hours. Overall analgesic received in first 24 hours was also assessed.

The data was entered in MS EXCEL spreadsheet and analysis was done using Statistical Package for Social Sciences (SPSS) version 21.0. Quantitative variables were compared using unpaired t-test/Mann-Whitney Test. Qualitative variable were compared using Chi-square test /Fisher's exact test. A p value of <0.05 was considered statistically significant.

3. Results

Table 1: Demographic data

Parameters	Mean ± S D		P Value
	Dexamethasone	Dexmedetomidine	
Age(yrs)	36.3 ± 9.69	35.27 ± 7.11	0.639
Height(cm)	159.17 ± 5.19	159.5 ± 5.35	0.858
Weight(kg)	56.23 ± 7.25	59.4 ± 8.30	0.121
BMI (kg/m ²)	22.16 ± 2.28	23.27 ± 2.29	0.064

The differences in age, sex, height, weight, BMI between the two groups were insignificant (Table 1). We calculated heart rate, systolic blood pressure, diastolic blood pressure at 0-hours, 2-hours, 4-hours, 8-hours, 12-hours, 18-hours, 24-hours. There was no significant difference in haemodynamic parameters in both groups till 10 hours and

Table 2: Various parameters assessed

Parameters	Mean + S D		P value
	Dexamethasone	Dexmedetomidine	
Time to first rescue analgesia (minutes)	709.67 ± 18.47	910.2 ± 51.66	<0.0001
Total analgesia given in 24 hours	1.23 ± 1.17	0.4 ± 0.56	0.004
Duration of motor block (minutes)	635.47 ± 26.29	827.47 ± 54.62	<0.0001
Duration of sensory block (minutes)	681.5 ± 27.19	877.17 ± 52.85	<0.0001

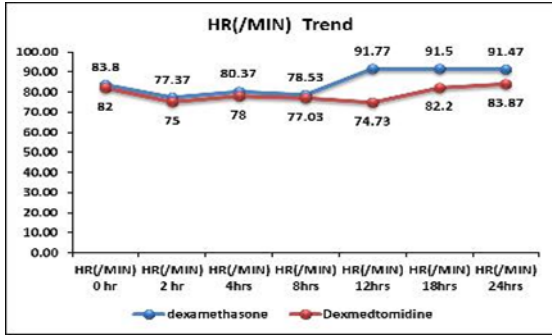


Fig. 1: Heart rate trend

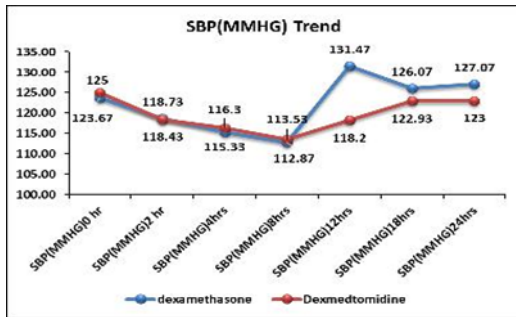


Fig. 2: Systolic blood pressure trend

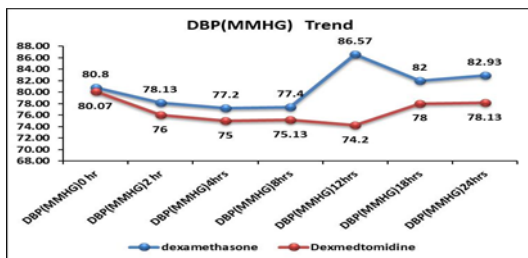


Fig. 3: Diastolic blood pressure trend

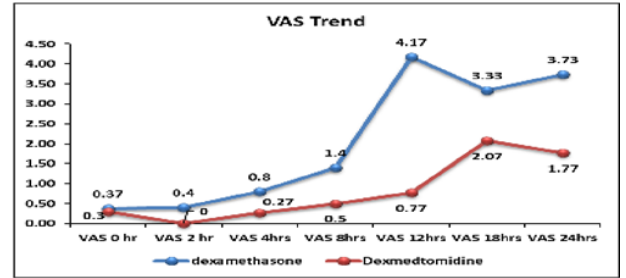


Fig. 4: VAS trend

in Dexamethasone group and 877.17 ± 52.85 minutes in Dexmedetomidine group.

The mean duration of time to first rescue analgesic was 709.67±18.47 minutes in dexamethasone group and 910.2 ± 51.66 minutes in Dexmedetomidine group (Table 2). The difference was highly significant (p value < 0.0001). Injection diclofenac 75 mg iv was given at first request for analgesia, followed by injection paracetamol 1gm iv after half hour if there was no relief. There was significant statistical difference of 0.004 between the two groups, with mean of 1.23 ± 1.17 in Dexamethasone group and 0.4 ± 0.56 in Dexmedetomidine. This clearly shows that Dexmedetomidine group required less number of analgesics in 24 hours post-operatively.

Thus, both drugs were found to be effective for post-operative analgesia, but Dexmedetomidine was found to be better. VAS score between the two groups was non-significant only at 0 hours (0.587). However, 2-hr, 4-hr, 8-hr, 12- hr, 18 -hr, 24 -hr it was significant (p value <0.0001).

4. Discussion

Adjuvants like Dexamethasone and Dexmedetomidine are effective in prolonging the duration of analgesia without much side effects. The reason for significant difference in the haemodynamic variables is because sensory block started to wane off around this time (Mean duration -681.5 minutes) in dexamethasone group. There was significant difference in duration of motor and sensory block in Dexamethasone and Dexmedetomidine group of p value <0.0001. Adequate grading according to Bromage Scale could not be done due to bandaging of the operated arm.

thereafter it was significant (Figures 1, 2 and 3). There was significant difference in duration of motor and sensory block in Dexamethasone and Dexmedetomidine group of p value <0.0001. The mean duration of motor block in Dexamethasone group was 635.47 ± 26.29 minutes and in Dexmedetomidine group was 827.47 ± 54.62 minutes. The mean duration of sensory block was 681.5 ± 27.19 minutes

The difference in mean duration of time to first rescue analgesic was highly significant (p value < 0.0001). Total analgesia given was calculated with reference to number of times there was need for analgesia in post-operative 24 hours. There was significant statistical difference of 0.004 between the two groups, which clearly shows that Dexmedetomidine group required less number of analgesics in 24 hours post operatively. VAS score between the two groups was non-significant only at 0 hours (0.587). However, at 2-hr, 4-hr, 8-hr, 12-hr, 18-hr, 24-hr was significant (p value < 0.0001). Even though, the patients in Dexamethasone group were pain free for 709 minutes, there was significant difference between the VAS scores of two groups till that hour. This is because dexmedetomidine caused sedation that kept patient calm, tranquil and co-operative without any prolongation in PACU stay. This effect could not be achieved by Dexamethasone group.

Dexmedetomidine is an α_2 -adrenoceptor agonist.² It is sympatholytic and has hemodynamic stabilizing properties, without respiratory depression. One of the highest densities of α_2 receptors have been located in the locus coeruleus. The hypnotic and sedative effects of α_2 adrenoceptor activation have been attributed to this site in the CNS. It is also the site of origin of the descending medullo-spinal noradrenergic pathway, known to be an important modulator of nociceptive neurotransmission. In the region of the brain, α_2 -adrenergic and opioid system have common effector mechanisms, indicating that Dexmedetomidine has a supraspinal site of action.

Dexamethasone is a synthetic glucocorticoid and has potent anti-inflammatory activity. Dexamethasone alone does not have analgesic effects but when added to local anaesthetics prolong the duration of analgesia.³ Dexamethasone prolongs the duration of action of Bupivacaine in perineural blocks.^{4,5} The possible mechanism of analgesia and antiemetic actions are due to the anti-inflammatory property of dexamethasone.^{6,7}

Krishna et al⁸ in their study comparing Dexamethasone and Dexmedetomidine as adjuvant to 0.375% Ropivacaine observed that difference in haemodynamic parameters was insignificant between the two groups. The Duration of Analgesia was highly significant in Dexmedetomidine group (899.5 ± 61.9) as compared to Dexamethasone group (734 ± 23.4) ($p < 0.0001$). As seen in this study too that Dexmedetomidine provide longer duration of analgesia.

N K Verma et al⁹ found that haemodynamic parameters at 10, 15, 30, 45, 60, 90, 120 and 150 minutes were statistically insignificant between the two groups ($p > 0.05$). The sensory and motor block onset times and duration was earlier in Dexmedetomidine group as compared to Dexamethasone group. They also found that 24 hours visual analog scale was more in group Dexamethasone and from the 6th hour onwards, patients of group Dexmedetomidine showed a significant lower VAS.

Mandeep Kaur et al¹⁰ conducted a study with the intent of comparing onset, duration of sensory and motor block along with duration of analgesia when an α_2 agonist Dexmedetomidine or a steroid Dexamethasone was added to a mixture of 2% lignocaine with adrenaline and 0.5% bupivacaine. The duration of sensory block and motor block was longer with Dexmedetomidine. Another study conducted between Dexmedetomidine, Dexamethasone and Ropivacaine in Axillary Brachial Plexus Blocks. The duration of the sensory block was extended in group Dexamethasone and group Dexmedetomidine compared with Ropivacaine group ($P < 0.05$), but there was no significant difference between Dexamethasone and Dexmedetomidine group.¹¹ Another study done to assess the effect of Dexamethasone as adjuvant to Ropivacaine found the onset of sensory block, motor block and surgical anaesthesia were early and duration of analgesia was significantly prolonged in Dexamethasone group compared with Ropivacaine group.¹²

These studies used 0.5% Ropivacaine; 0.375% Ropivacaine and Peripheral nerve stimulator technique with Ultrasound guided block respectively. But the major requirement of peripheral nerve block given for post-operative analgesia with or without adjuvants is prolonged analgesia without much adverse effects, local anaesthetic toxicity and minimal motor analgesia. But with addition of adjuvants there is prolonged analgesia, sensory block and motor block too.

5. Conclusion

Ultrasound guided Brachial Plexus Block with adjuvants is an effective technique to reduce post-operative pain with minimal adverse effects. Dexamethasone and Dexmedetomidine adjuvants are effective in prolonging the duration of post-operative analgesia. However, Dexmedetomidine is better than Dexamethasone in prolonging the duration of analgesia and overall requirement of analgesic.

6. Source of Funding

None.

7. Conflict of Interest

None.


References


1. Gupta KK, Attri JP, Singh A. Ultrasound guided brachial plexus block. *Anaesth Pain Intensive Care*. 2016;20(2):187-92.
2. Raimo V, Juha M, Veijo S, Leena N, Virtanen R. Characterisation of selectivity, specificity and potency of dexmedetomidine as α_2 adrenoceptor agonist. *Eur J Pharmacol*. 1988;150(1-2):9-14.
3. Liu K, Hsu CC, Chia YY. Effect of dexamethasone on postoperative pain and emesis. *Br J Anaesth*. 1998;80(1):85-6.
4. Estebe JP, LeCorre P, Clément R, DuPlessis L, Chevanne F, LeVerge R, et al. Effect of dexamethasone on motor brachial plexus block

- with bupivacaine and with bupivacaine-loaded microspheres in a sheep model. *Eur J Anaesthesiol.* 2003;20(4):305–10.
5. Holte K, Werner MU, Lacouture PG, Kehlet H. Dexamethasone prolongs local analgesia after subcutaneous infiltration of bupivacaine microcapsules in human volunteers. *Anesthesiology.* 2002;96(6):1331–5.
 6. El-Hakim M, Ali NM, Rashed I, Riad MK, Refat M. Dexamethasone reduces postoperative vomiting and pain after pediatric tonsillectomy. *Can J Anaesth.* 2003;50(4):392–7.
 7. Golwala MP, Swadia VN, Dhimar AA, Sridhar NV. Pain relief by dexamethasone as an adjuvant to local anaesthetic in supraclavicular brachial plexus block. *J Anesth Clin Pharmacol.* 2009;25(3):285–8.
 8. Chaithanya K, Reddy AN, Sangamithra. A comparative study between 0.375% ropivacaine with 50mcg of dexmedetomidine and 0.375% ropivacaine with 8mg of dexamethasone for ultrasound guided supraclavicular brachial plexus block. *Indian J Clin Anaesth.* 2017;4(1):69–73.
 9. Verma NK, Ranjan A. A clinical comparison of Dexmedetomidine and Dexamethasone as adjuvant to Ropivacaine in Supraclavicular brachial plexus blocks for upper arm surgeries. *Int J Adv Res Biol Sci.* 2016;3(7):56–61.
 10. Kaur M, Lakhani A, Hashia AM. Comparative study between dexamethasone and dexmedetomidine in supraclavicular block. *Int J Adv Med.* 2018;5(1):57–61.
 11. Lee MJ, Koo DJ, Choi YS, Lee KC, Kim HY. Dexamethasone or Dexmedetomidine as Local Anesthetic Adjuvants for Ultrasound-guided Axillary Brachial Plexus Blocks with Nerve Stimulation. *Korean J Pain.* 2016;29(1):29–33.
 12. Jadon A, Dixit S, Kedia SK, Chakraborty S, Agrawal A, Sinha N, et al. Interscalene brachial plexus block for shoulder arthroscopic surgery: Prospective randomised controlled study of effects of 0.5% ropivacaine and 0.5% ropivacaine with dexamethasone. *Indian J Anaesth.* 2015;59(3):171–6.

Author biography

Ishita Garg, AORA Fellow  <https://orcid.org/0000-0002-1703-3154>

Niti Gulati, Senior Consultant, Assistant Professor  <https://orcid.org/0000-0002-9943-2916>

Divesh Arora, Director & HOD  <https://orcid.org/0000-0002-3336-3575>

Cite this article: Garg I, Gulati N, Arora D. A prospective, randomised, double blind study comparing dexamethasone and dexmedetomidine as adjuvants to 0.2% ropivacaine for post-operative analgesia in ultrasound guided brachial plexus block. *Indian J Clin Anaesth* 2022;9(4):485-489.