



Letter to Editor

Anaesthetic challenges in a rare case of paraduodenal hernia complicating pregnancy

Satyajit Majhi¹, Kritika Agrawal^{2,*}, Rashmi Salhotra³

¹Dept. of Anaesthesiology and Critical Care, Max Super Speciality Hospital, Patparganj, Delhi, India

²Dept. of Anaesthesiology and Critical Care, IGESI Hospital, Jhilmil, Delhi, India

³Dept. of Anaesthesiology and Critical Care, UCMS and GTP Hospital, Delhi, India



ARTICLE INFO

Article history:

Received 30-06-2021

Accepted 15-01-2022

Available online 22-04-2022

This is an Open Access (OA) journal, and articles are distributed under the terms of the [Creative Commons Attribution-NonCommercial-ShareAlike 4.0 License](https://creativecommons.org/licenses/by-nc-sa/4.0/), which allows others to remix, tweak, and build upon the work non-commercially, as long as appropriate credit is given and the new creations are licensed under the identical terms.

For reprints contact: reprint@ipinnovative.com

Paraduodenal hernia (PDH) is a rare congenital anomaly occurring due to malrotation of the midgut. This type of internal hernia has varied and non-specific symptoms. Despite its rarity, it is a life-threatening surgical emergency with high mortality rate. Only two cases of left-sided PDH and one case of right-sided PDH associated with pregnancy have been reported.¹⁻³ However, none of these cases have discussed the anaesthetic challenges of such a case. Here we report the anaesthetic management of a case of right-sided paraduodenal hernia discovered as a coincidental finding during emergency laparotomy in a seven months antenatal patient with acute abdomen.

A 24-year-old female with seven months gestational period presented to the emergency department with history of abdominal pain and distension for 2 days. Ultrasonography (USG) of abdomen suggested either hollow viscus perforation or intestinal obstruction. The obstetric USG revealed presence of cardiac activity. After obtaining written informed consent for surgery, decision of emergency laparotomy was taken.

A multi-disciplinary team of anaesthetists, surgeons, obstetricians, and paediatrician was involved for optimal management of the case. General anaesthesia (GA) was induced with rapid sequence induction and tracheal

intubation was done with 7mm cuffed endotracheal tube. Exploration of the cavity demonstrated a massively dilated stomach and duodenum along with presence of a right-sided paraduodenal hernia. Due to distorted anatomy, uterus could not be accessed immediately for caesarean section (CS) (Fig 1). On nasogastric aspiration, massive volume (almost seven liters) of gastric fluid was aspirated. In addition, two liters of fluid was aspirated through gastrostomy. Only after relieving the gastric distension, CS could be done and a fresh still born male baby was delivered.

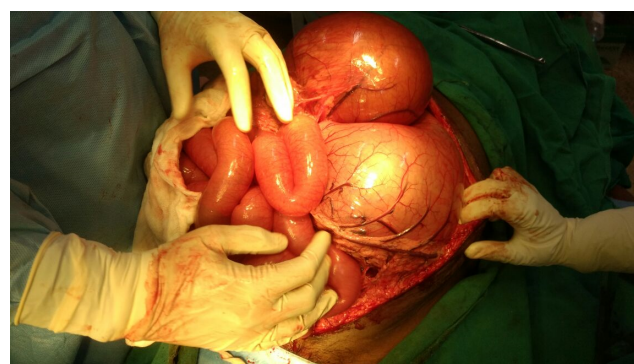


Fig. 1:

Intraoperatively, intravascular volume was maintained with four liters crystalloid, one liter colloid and

* Corresponding author.

E-mail address: kritika.agrawal.4@gmail.com (K. Agrawal).

one unit whole blood. Blood gas analysis depicted metabolic acidosis which was corrected with injection sodium bicarbonate. Surgery lasted for four hours with approximately one liter of blood loss. Postoperative recovery was uneventful and patient was discharged on 26th postoperative day.

In such a case of pregnancy complicated with PDH, anaesthetic challenges would pertain to an obstetric patient undergoing both CS as well as emergency non-obstetric surgery. The routine anaesthetic management should be adapted to the physiological changes of pregnancy; which peak in third trimester. Intrauterine hypoxia is the biggest risk for the fetus during non-obstetric surgery. Intraoperatively, aggressive measures are needed for prevention and management of maternal hypotension, hypoxia, hypercarbia and hypocarbia, if any, in order to maintain uteroplacental circulation. Dose of anaesthetic drugs should be tailored according to potential fetal effects. Intraoperative fetal heart rate monitoring using transabdominal or transvaginal doppler probe can be useful.

Another important anaesthetic challenge in this case was the fluid management as massive volume of fluid was sequestered in the intragastric space. Traditional teachings advocated liberal fluid therapy in such major abdominal surgeries; assuming that a significant volume of fluid is sequestered into the “third space”.⁴ On the other hand, current recommendations favour restrictive or goal-directed fluid therapy.⁵ This regimen, however, requires advanced haemodynamic monitoring e.g. oesophageal Doppler monitoring, arterial pressure waveform (pulse pressure variation, stroke volume variation), pulse contour

analysis (LidCo or PiCCO) etc. Since these modalities were not available in our institute, we followed the traditional method of fluid therapy.

References

1. Ali S, Saxena B, Meena RG, Vijay A, Tanwar RK. Pregnancy complicated by acute intestinal obstruction secondary to left paraduodenal hernia- An unusual case report. *J Evol Med Dent Sci.* 2017;6(4):340–2.
2. Ramakrishnaiah SB, Giridhar-Boggaram S, and MPS. Small bowel obstruction due to internal herniation of jejunum through a congenital defect in the falciform ligament in a primigravida. *Arch Int Surg.* 2015;5(1):46–8.
3. Kumari R, Malik R, Meena P. Right Paraduodenal Hernia Complicating Pregnancy. *Int J Sci Res.* 2019;8:33–33.
4. Brandstrup B, Svensen C, Engquist A. Hemorrhage and operation cause a contraction of the extracellular space needing replacement—evidence and implications? A systematic review. *Surgery.* 2006;139(3):419–32.
5. Doherty M, Buggy DJ. Intraoperative fluids: how much is too much? *Br J Anaesth.* 2012;109(1):69–79.

Author biography

Satyajit Majhi, Associate Consultant

Kritika Agrawal, Junior Specialist  <https://orcid.org/0000-0002-7474-0488>

Rashmi Salhotra, Professor

Cite this article: Majhi S, Agrawal K, Salhotra R. Anaesthetic challenges in a rare case of paraduodenal hernia complicating pregnancy. *Indian J Clin Anaesth* 2022;9(2):281-282.