



## Case Report

# Ultrasound-guided posterior tibial artery cannulation as a rescue for intraoperative accidental arterial line displacement in the prone position: A case report

Mamta Sinha<sup>1</sup>, Mayank Kumar<sup>1,\*</sup>

<sup>1</sup>All India Institute of Medical Sciences, Raipur, Chhattisgarh, India



## ARTICLE INFO

### Article history:

Received 02-11-2021

Accepted 29-12-2021

Available online 22-04-2022

### Keywords:

Ultrasound

Arterial cannulation

Prone position

## ABSTRACT

Arterial cannulation for patients in prone position poses a great challenge for the anaesthesiologists because of restricted anatomical access and technical difficulty in needle advancement. In such a problematic scenario, ultrasound might be hugely helpful. We report a case of a 42-year-old male who underwent Atlanto-occipital fusion in prone position. Intraoperatively the left radial arterial cannula got dislodged accidentally. The right posterior tibial artery was cannulated under ultrasound guidance by long-axis in-plane approach as a rescue technique for continued management without disturbing the procedure and inconvenience to the team. The procedure was successful on the first attempt.

This is an Open Access (OA) journal, and articles are distributed under the terms of the [Creative Commons Attribution-NonCommercial-ShareAlike 4.0 License](https://creativecommons.org/licenses/by-nc-sa/4.0/), which allows others to remix, tweak, and build upon the work non-commercially, as long as appropriate credit is given and the new creations are licensed under the identical terms.

For reprints contact: [reprint@ipinnovative.com](mailto:reprint@ipinnovative.com)

## 1. Introduction

Arterial cannulation enables beat-to-beat blood pressure monitoring, assessment of fluid responsiveness, and frequent blood sampling for arterial blood gas analysis intraoperatively as well as in the post-operative period.<sup>1</sup> It is also helpful in hemodynamic monitoring and interpretation of blood pressure variation in neuro surgeries (especially near the brain stem) and spine surgeries. In clinical practice, radial artery, femoral artery, ulnar artery, dorsalis pedis artery are frequently used; the radial artery is the most common owing to having multiple advantages.<sup>2</sup> However, most of these sites are not easily accessible intraoperatively in patients being positioned prone. In such a scenario, the posterior tibial artery, which is a superficial and easily palpable artery, can provide an alternative site for cannulation. However, anatomical variations and restrictions due to positioning, limb edema can lead to failures in cannulation by the

landmark technique. Ultrasound is especially useful for vascular access in patients with low perfusion, arrhythmias, obesity, and previously unsuccessful attempts with the palpation technique. We present such a case to highlight the importance of ultrasound in posterior tibial artery cannulation as a rescue method for intraoperative accidental radial arterial line displacement in the prone position.

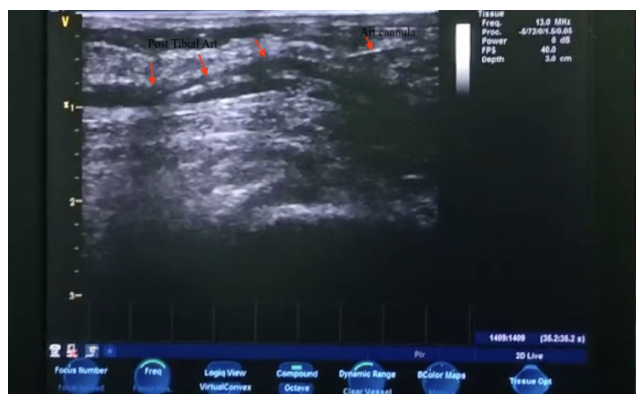
## 2. Case Report

A 42-year-old male patient, 60 Kg, American Society of Anesthesiologists (ASA) physical status-2, was undergoing Atlanto-occipital fusion. He had a history of progressive quadriplegia with shortness of breath for two months. He was also on Anti-tubercular multi-drug therapy for pulmonary tuberculosis for two months. Pre-operative Haemoglobin was 12.3 gm/dl, Platelets 3.67 lakhs/microliter. Computed Tomography scan spine revealed Atlanto-axial subluxation with basilar indentation of odontoid process with severe compression of the cortico-medullary junction. Under general anaesthesia,

\* Corresponding author.

E-mail address: [mayanksonupmch@gmail.com](mailto:mayanksonupmch@gmail.com) (M. Kumar).

with a cervical collar in place, the patient was intubated using a videolaryngoscope. Intra-arterial cannulation for monitoring was planned in view of the risk of hemodynamic variation, and the left radial arterial cannula was inserted by the conventional palpatory method. After turning the patient prone, it was realised that the arterial cannula had got dislodged during positioning. It was difficult to access and re-cannulate the radial or dorsalis pedis arteries in the prone position. So, posterior tibial artery cannulation was attempted but difficulties in getting a position for cannula insertion by the conventional palpatory method was faced. After that, the posterior tibial artery was located using a short axis view; then probe was rotated 90° to view the course of the artery in the long axis. An arterial line was secured with 20 G arterial cannula (BD, USA) in the right posterior tibial artery using ultrasound (Linear probe 7–11 MHz, GE, vivid S5) by long-axis in-plane approach (Figure 1) in the first attempt. The surgery went for four hours, was uneventful, and the patient was extubated on the table. Patient was shifted to ICU for post-operative hemodynamic monitoring. No hematoma, thrombosis, nerve injury, or spasm was noted, and the arterial cannula was removed after 24 hrs.



**Fig. 1:** Post tibial

### 3. Discussion

The prone position provides optimal exposure for spine surgery,<sup>3</sup> however, arterial and other vascular cannulations become difficult after the patient is positioned prone. Ultrasound-guided vascular cannulations can be very useful in such situations, and central venous cannulation using long-axis in-plane approach in prone position has been described.<sup>4</sup>

Traditionally, arterial cannulation is done using the landmark technique by palpating the arterial pulse with various first-attempt success rates. Multiple attempts can cause arterial spasms and hematoma. Rawal P. has described cannulation of the posterior tibial artery in prone patients

using a landmark guided approach.<sup>3</sup> Various studies have shown that the rate of successful cannulation increases significantly under ultrasound guidance.<sup>1,5,6</sup> The earliest reports on USG-guided arterial cannulation go back to 1989, where the application of continuous-wave Doppler to aid in cannulation was described.<sup>7</sup> Real-time ultrasound provides the operator the benefit of visualizing the pulsating artery and the surrounding anatomic structures prior to and during catheter insertion, thereby minimizing complications and increasing success rate. This is especially useful in abnormal patient positions.

It is now well-perceived that ultrasound is helpful in vascular access. Recommendations for the use of ultrasound in central vein cannulation<sup>8</sup> have come; and real time arterial cannulation has also been recommended in many RCTs. Our case highlights the use of ultrasound guided posterior tibial artery cannulation during accidental arterial dislodgement in the prone position.

### 4. Conclusion

Use of ultrasound as an adjunct to arterial cannulations should be considered a good practice. We believe that with continuous improvement of ultrasound-guided vascular techniques and availability of ultrasound machines, real-time ultrasound-guided arterial cannulations should become the standard of care.

### 5. Source of Funding

None.

### 6. Conflict of Interest


None.

### References

1. Scheer B, Perel A, Pfeiffer UJ. Clinical review: Complications and risk factors of peripheral arterial catheters used for haemodynamic monitoring in anaesthesia and intensive care medicine. *Crit Care*. 2002;6(3):199–204.
2. Sandhu NS, Patel B. Use of ultrasonography as a rescue technique for failed radial artery cannulation. *J Clin Anesth*. 2006;18(2):138–41.
3. Edgcombe H, Carter K, Yarrow S. Anaesthesia in the prone position. *Br J Anaesth*. 2008;100(2):165–83.
4. Sofi K, Arab S. Ultrasound-guided central venous catheterization in prone position. *Saudi J Anaesth*. 2010;4(1):28–30.
5. Nuttall G, Burckhardt J, Hadley A, Kane S, Kor D, Marienau MS, et al. Surgical and patient risk factors for severe arterial line complications in adults. *Anesthesiology*. 2016;124(3):590–7.
6. Tang L, Wang F, Li Y, Zhao L, Xi H, Guo Z, et al. Ultrasound guidance for radial artery catheterization: an updated meta-analysis of randomized controlled trials. *PLoS one*. 2014;9(11):e111527.
7. Maher JJ, Dougherty JM. Radial artery cannulation guided by Doppler ultrasound. *Am J Emerg Med*. 1989;7(3):260–2.
8. Rupp SM, Apfelbaum JL, Blitt C, Caplan RA, Connis RT, Domino KB. Practice guidelines for central venous access: a report by the American Society of Anesthesiologists Task Force on Central Venous Access. *Anesthesiology*. 2012;116(3):539–73.

### Author biography

**Mamta Sinha**, Assistant Professor  <https://orcid.org/0000-0001-9053-2059>

**Mayank Kumar**, Associate Professor  <https://orcid.org/0000-0003-0823-2124>

**Cite this article:** Sinha M, Kumar M. Ultrasound-guided posterior tibial artery cannulation as a rescue for intraoperative accidental arterial line displacement in the prone position: A case report. *Indian J Clin Anaesth* 2022;9(2):273-275.