



## Original Research Article

# Comparative study of bupivacaine-lignocaine to bupivacaine-lignocaine-dexamethasone in providing postoperative analgesia in interscalene block for shoulder arthroscopy

Isha Parveen S<sup>1</sup>, Mili Rajappan<sup>1,\*</sup>

<sup>1</sup>Dept. of Anaesthesiology, Cosmopolitan Hospital, Post Graduate Institute of Health Science and Research,, Trivandrum, Kerala, India



## ARTICLE INFO

## Article history:

Received 01-08-2021

Accepted 08-10-2021

Available online 12-02-2022

## Keywords:

Brachial plexus block

Dexamethasone

Aalgnesia

Lignocaine

Bupivacaine

## ABSTRACT

**Background and Objectives:** Interscalene brachial plexus block has gained prominence nowadays and has benefits of lesser intraoperative anaesthetic use, lesser analgesic requirement and lesser incidence of postoperative nausea and vomiting. Adjuvants are added to local anaesthetics for prolonging postoperative analgesia with interscalene block. Among the adjuvants, dexamethasone has been used extensively in past decade in neuraxial and peripheral nerve blocks. The aim of the study was to compare the duration of postoperative analgesia with lignocaine- bupivacaine combination and dexamethasone added to lignocaine - bupivacaine in interscalene block for shoulder arthroscopy.

**Materials and Methods:** In this comparative study, 48 patients of ASA grade I and II were selected and divided into 2 groups of 24 each. After obtaining informed written consent, general anaesthesia was given to patients satisfying inclusion criteria and ultrasound guided interscalene block was performed. Time of demand for additional analgesic supplementation by the patient were noted. Hemodynamic and respiratory monitoring were done to assess any side effects and complications.

**Results:** Duration of analgesia was prolonged in group II (10.33±1.45 hours) i.e in lignocaine-bupivacaine-dexamethasone group than Group I(7.17±0.87 hours) i.e in lignocaine-bupivacaine group with p value less than 0.001. There were no significant differences between the two groups in secondary outcomes based on hemodynamic parameters.

**Conclusion:** Dexamethasone at a dose of 8 mg in addition to lignocaine-bupivacaine, given perineurally in interscalene block provided better quality of block and prolonged duration of analgesia by almost 3 hours, without any significant changes in hemodynamic parameters. There were no major adverse effects noted.

This is an Open Access (OA) journal, and articles are distributed under the terms of the [Creative Commons Attribution-NonCommercial-ShareAlike 4.0 License](https://creativecommons.org/licenses/by-nc-sa/4.0/), which allows others to remix, tweak, and build upon the work non-commercially, as long as appropriate credit is given and the new creations are licensed under the identical terms.

For reprints contact: [reprint@ipinnovative.com](mailto:reprint@ipinnovative.com)

## 1. Introduction

Regional anaesthesia for shoulder arthroscopy, especially ultrasound guided interscalene block has now been accepted for controlling the postoperative pain associated with the procedure. Ultrasound guidance resulted in decreased incidence of inadvertent vascular punctures. It also resulted in decreased needle insertion attempts and procedure times.

The use of general anaesthesia with endotracheal intubation ensure adequate airway control when procedures are in lateral and beach chair position, control of vital signs and postoperative pain.<sup>1</sup>

Lignocaine and Bupivacaine are combined to give the best effects of both drugs: i.e the very rapid onset of lignocaine and the prolonged duration of bupivacaine. Adjuvants are added to prolong the duration of sensory and motor block and to limit the dose requirement of local anaesthetics. Opioids are used as adjuvants but adverse

\* Corresponding author.

E-mail address: [mili\\_lal@yahoo.co.in](mailto:mili_lal@yahoo.co.in) (M. Rajappan).

effects like respiratory depression, pruritus, nausea and vomiting have limited their use. in peripheral and neuraxial nerve blocks.

In our attempt to use a drug with better intraoperative hemodynamic profile and prolonged postoperative analgesia with minimal side effects, Dexamethasone was chosen as an adjuvant to lignocaine –bupivacaine combination.

## 2. Materials and Methods

A comparative study was conducted in a tertiary care centre from July 2018 to July 2019 after Institutional ethical committee clearance. Patients with American Society of Anaesthesiologists (ASA) Grade I and II, who belonged to the age group of 20-60 years of either gender, undergoing shoulder arthroscopies under general anaesthesia and interscalene block were included in the study. Patients not consenting for the procedure, those who were allergic to local anesthetics, patients with ASA Grade 3 or more, those with bleeding disorders, severe lung diseases, diaphragmatic palsies, pre-existing neuropathies involving the surgical limb were excluded from the study.

Demographic data were collected. Patient's age, sex, ASA status were noted. After thorough pre anaesthetic assessment, the planned procedure and possible complications were explained to the patients. Informed written consent was obtained.

48 patients of ASA grade I and II were randomly allocated into two groups: Group I received a combination of lignocaine 2% 15ml and bupivacaine 0.5% 15ml with 2ml normal saline. Group II received a combination of lignocaine 2% 15ml and bupivacaine 0.5% 15ml with 2ml dexamethasone.

All patients were given oral pantoprazole 40 mg and alprazolam 0.5 mg on the night before the surgery and were fasting for 8 hours overnight.

On the day of surgery, premedication was given with Intravenous injections of granisetron 1mg, midazolam 1mg and glycopyrrolate 0.2mg. As per our routine, General anaesthesia was induced with intravenous fentanyl 2  $\mu$ g/kg and propofol 2–3 mg/kg. Endotracheal intubation was facilitated by intravenous atracurium 0.5 mg/kg. Anaesthesia was maintained by 1–1.5 MAC sevoflurane in 50% oxygen/nitrous oxide mixture and atracurium 0.1 mg/kg every 20 min. Ventilation parameters [volume control mode, tidal volume 6–10 ml/kg, RR 12–14 b/min, peak airway pressure < 40 mmHg] were set. After giving general anaesthesia, ultrasound guided interscalene block was given to the Group 1 and Group 2 patients who came under inclusion criteria.

The ultrasound technique consisted of in plane posteriorly placed needle approach at the level of cricoid cartilage. Under all aseptic precautions, with the patient in supine position, the affected arm was kept adducted and head turned to contralateral side. The nerve trunks

were identified as 3 to 5 hypoechoic structures between anterior and middle scalene muscles. Internal carotid artery and internal jugular vein could be seen lying anterior to anterior scalene muscle. The needle was positioned in a direction parallel to the beam of the ultrasound transducer. The needle was advanced through the middle scalene muscle till it passed the fascia anteriorly in interscalene groove. The needle tip and shaft were visualised during the entire procedure. Local anesthetic injection was given after negative aspiration and needle position was readjusted as necessary to ensure appropriate spread.

Baseline parameters like Systolic blood pressure(SBP),Diastolic blood pressure (DBP), Mean arterial pressure(MAP), Heart rate(HR) and Oxygen saturation(SpO<sub>2</sub>) were recorded. These parameters were monitored in the first 5, 15, 30 minutes and then hourly till 8 hours in the postoperative ward.

At the end of surgery patients were extubated after reversing with intravenous neostigmine (0.04 mg/kg) and glycopyrrolate (0.01 mg/kg). The patients were monitored in the postoperative critical care unit.

Time of request for additional analgesic supplement by the patient was noted. Post operative analgesia was monitored as per a numerical rating scale score of 0-10 at every hour upto 24 hours. The administration of analgesics was delayed until patients felt that their pain warranted medication. An initial dose of Tramadol 100mg intravenously was given as the first rescue analgesia. Hemodynamic and respiratory monitoring were done to identify any side effects or complications such as nausea, vomiting, convulsions, respiratory problems.

“Effect of dexamethasone on the duration of interscalene nerve blocks with ropivacaine or bupivacaine,” by K. C. Cummings III et al., British journal of anaesthesia, vol. 107, no. 3, pp. 446–453, 2011.<sup>2</sup> was taken as the reference study.  $\delta$  is the difference between mean values of outcome which is worth to detect,  $\alpha$  is the type 1 error; here taken as 1%,  $\beta$  is the type two error; here taken as 10%,  $\sigma$  of 5 hours is the standard deviation of outcome measurement from literature,  $\delta$  of 6 hours is the difference between mean values of outcome which is worth to detect. The sample size was calculated to 21 in each group. We added 10% extra patients to the above number to achieve the power of efficiency. Then the sample size was  $21 + 3 \approx 24$  in each of the arms, so the total sample size was 48.

The SPSS statistical package (version 16.0) was used for the statistical analysis. Numerical data were expressed as mean  $\pm$  standard deviation and categorical data as frequencies. Comparisons of categorical variables between two groups were tested using the Chi-square and Fisher's exact test. Continuous variables were compared using Student's t-test. P value <0.05 was considered as statistically significant. All statistical tests were two sided.

### 3. Results

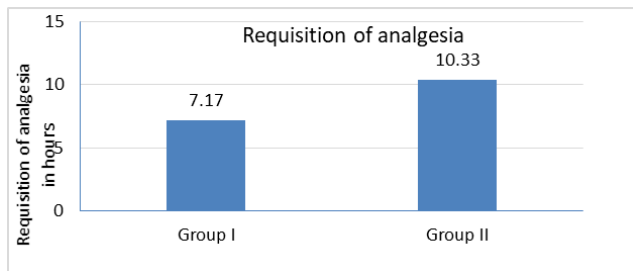
There was no significant difference ( $p > 0.05$ ) between group I (control group) and group II (dexamethasone group) with respect to age, sex or ASA status of the patients. So the two groups were homogenous and hence comparable. Duration of analgesia was more prolonged in group II compared to group I and the results were statistically significant ( $p$  value  $< 0.001$ ) (Table 2). The postoperative duration of analgesia in group I was approximately 7.17 hours and in group II, it was 10.33 hours (Figure 1). Comparison of hemodynamic parameters at baseline and at different time intervals upto a time period of 8 hours indicated that there was no statistically significant difference ( $P$  value  $> 0.05$ ) between the dexamethasone group and the control group (Figures 2, 3 and 4)

**Table 1:** Demographic parameters

	Group I	Group II
Age(years)	43.7+10.9	46.2+10.4
Sex(M:F)	13:11	13:11
ASA grading(I :II)	16:8	15:9

**Table 2:** Comparison of postoperative analgesia

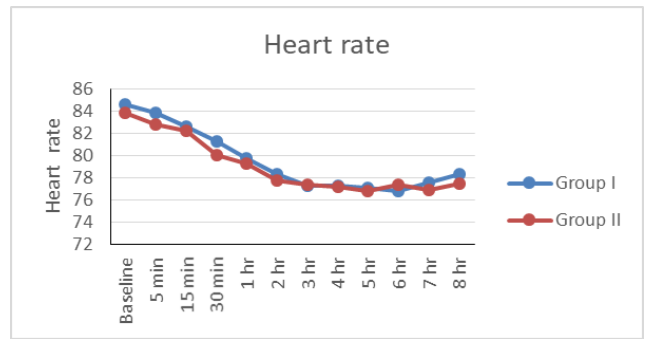
Category	N	Requisition of analgesia in hours		t	P
		Mean	sd		
Group I	24	7.17	0.87	9.181	$< 0.001$
Group II	24	10.33	1.45		



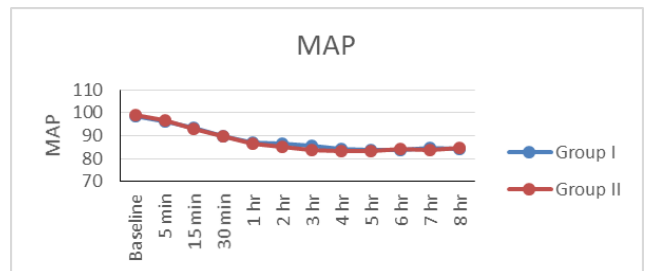
**Fig. 1:** Comparison between Group I and Group II according to postoperative analgesia (unpaired t test)

### 4. Discussion

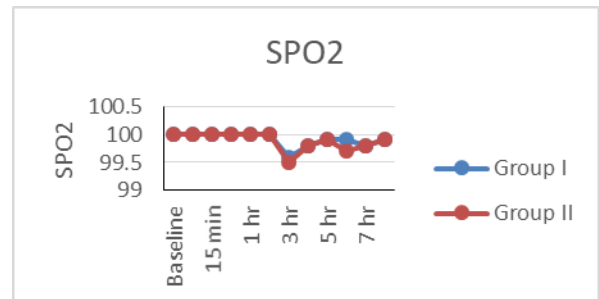Shoulder arthroscopy is a minimally invasive, ambulatory surgery for treating a variety of shoulder pathologies. The incidence of postoperative pain after arthroscopic shoulder surgery is reported to be around 30-70%.<sup>2</sup> The management of severe postoperative pain is a major challenge for anaesthesiologists. There are multimodal approaches for



**Fig. 2:** Comparison between Group I and Group II according to heart rate (unpaired T test)



**Fig. 3:** Comparison between Group I and Group II according to MAP (unpaired t test)



**Fig. 4:** Comparison between Group I and Group II according to  $SP_{O_2}$  (unpaired t test)

controlling the postoperative pain including conventional oral and parenteral analgesia, brachial plexus block with local anaesthetics, suprascapular nerve block combined with local anaesthetic wound infiltration.

Among brachial plexus blocks for shoulder surgery, interscalene block has been proved to provide excellent analgesia, adequate muscle relaxation, earlier mobilization, shortened hospital stay and decreased requirement of opioids. As a result, patient satisfaction and functional outcome improves.

Different adjuvants have been tried along with local anaesthetics in interscalene block to overcome the limited analgesia of single-shot blockade. One among them is dexamethasone synthetic glucocorticoid. Dexamethasone

has been shown to prolong the duration of an interscalene block.<sup>2</sup>

Dexamethasone, a high-potency, long-acting glucocorticoid with little mineralocorticoid effect, has been shown to prolong peripheral nerve blockade in animals<sup>3</sup> and when added to bupivacaine microspheres extended the duration of analgesia in humans.<sup>3</sup> Although incompletely understood, mechanism of action may stem from decreased nociceptive C-fibre activity via a direct effect on glucocorticoid receptors<sup>4</sup> and inhibitory potassium channels.<sup>5</sup> Other authors suggest a local vasoconstrictive effect.<sup>6</sup> Resulting in reduced local anaesthetic absorption or a systemic anti-inflammatory effect<sup>7</sup> following vascular uptake of the drug.

Pre-operative administration of dexamethasone by oral and intravenous routes has been shown to reduce overall pain scores and analgesic requirements in the postoperative period without any adverse effects in various dental and general surgical procedures.<sup>8</sup>

In a prospective randomized study by Yadav R K et al,<sup>9</sup> the effectiveness of addition of dexamethasone versus neostigmine to lignocaine –adrenaline admixture for brachial plexus block in providing perioperative analgesia was compared. The duration of analgesia was found to be better in dexamethasone group (454.2±110.7 minutes) compared to neostigmine group (225.7±53.3 minutes).

In a study by Movafegh, Ali, et al,<sup>10</sup> the effect of dexamethasone added to lignocaine on the onset and duration of axillary brachial plexus block has been noted. The duration of sensory (242±76 versus 98±33min) and motor blockade (310±81 vs 130±31min) were significantly longer in the dexamethasone group than in the control group (P < 0.01).

In a study by Albrecht et al,<sup>11</sup> dexamethasone increased the mean duration of analgesia by 233 (172–295) min when injected with short- or medium-term action local anaesthetics and by 488 (419–557) min when injected with long-term action local anaesthetics.

In a study by Huyn et al,<sup>12</sup> in control group, the median time to first postoperative analgesic administration was 325 min. Dexamethasone significantly increased the duration of analgesia to about 351 min (P < 0.001). This result remained statistically significant when studies using upper extremity nerve blocks were pooled.

In a study by Tandoc et al<sup>13</sup> the effect of different doses of dexamethasone (4mg and 8 mg) with 0.5% bupivacaine in the duration of interscalene block was studied. The duration of analgesia was significantly prolonged in both Group L [dexamethasone 4mg group (21.6 ± 2.4 h)] and Group H [dexamethasone 8 mg group (25.2 ± 1.9 h)] compared with Group C [0.5% bupivacaine only (13.3 ± 1.2 h)] (p < 0.05).

In a study by Cummings et al,<sup>2</sup> duration of analgesia was significantly prolonged in bupivacaine -dexamethasone

group (22.4 hours) vs bupivacaine alone (14.8 hours) (P < 0.001).

In our study, the time of request for first analgesic use in both groups were noted. The mean duration of analgesia was more prolonged in group 2 (10.33±1.45 hours) compared to group 1 (7.17±0.87 hours) and the results were statistically significant (p value < 0.001). So as per the study, the analgesic hours obtained on addition of perineural dexamethasone was more than the combined use of lignocaine and bupivacaine. The difference in the duration of analgesic period could be attributed to dexamethasone as the volume of drug given in both the groups was equal. Also, the same intraoperative premedication drugs were given. Rescue analgesia was demanded by all the patients in both the groups. However, in Group II the demand for the first dose was delayed as compared to Group I patients.

Pain being a subjective sensation, the level of tolerance from patient to patient definitely varies. This could have contributed to the difference in the analgesia obtained between the groups to a certain extent. But with the addition of dexamethasone a significant increase of almost 3 hours was observed in our study.

Corticosteroids cause some vasoconstriction, probably mediated by occupancy of classical glucocorticoid receptors. It can be the reason for the prolongation of analgesia with dexamethasone.

Our study has some limitations. First, we could not assess the duration of the sensory block in our patients using repeated neurological examinations. As all patients were under GA, it was impossible to perform such an assessment. We, therefore, decided to use the duration until first analgesic request as a marker of the sensory block.

There was no case of nerve injury reported but long term adverse events with low frequency are possible. Also our trial did not discover any adverse events like potential damage to nerves due to the addition of perineural dexamethasone, probably because we monitored the patients over a short time window of 24 hours only. Follow up of three to six months would be more appropriate to detect such adverse events.

## 5. Conclusion

Dexamethasone, a glucocorticoid at a dose of 8mg given perineurally in addition to lignocaine and bupivacaine provided better quality of block and prolonged the duration of postoperative analgesia by almost 3 hours.

From the present study, we conclude that dexamethasone, as an adjuvant to lignocaine and bupivacaine in ultrasound guided interscalene blocks in shoulder arthroscopies provides effective intraoperative and early postoperative analgesia without any significant changes in the hemodynamic parameters and does not result in any major adverse effects.

Hence we conclude that dexamethasone is a beneficial addition to be used as an adjuvant to local anaesthetics for interscalene block in shoulder arthroscopies for prolonged postoperative analgesia and reduced postoperative complications such as postoperative nausea, vomiting, sedation and respiratory depression.

## 6. Source of Funding

None.

## 7. Conflict of Interest

There is no conflict of interest present and no external funding for the study.

## Acknowledgments

I would like to thank the patients who enrolled in the study. I would like to express my sincere gratitude to Department of Anaesthesia, Cosmopolitan Hospital and also my biostatistician who helped me analyse the data and reach valuable conclusions.

## References

- Pani N, Routray SS, Pani S, Mallik S, Pattnaik S, Pradhan A. Post-operative analgesia for shoulder arthroscopic surgeries: A comparison between inter-scalene block and shoulder block. *Indian J Anaesth.* 2019;63(5):382–7.
- Cummings KC, Napierkowski DE, Parra-Sanchez I, Kurz A, Dalton JE, Brems JJ, et al. Effect of dexamethasone on the duration of interscalene nerve blocks with ropivacaine or bupivacaine. *Br J Anaesth.* 2011;107(3):446–53.
- Estebe JP, LeCorre P, DuPlessis L, Chevanne F, Verge RL, Ecoffey C, et al. Effect of dexamethasone on motor brachial plexus block with bupivacaine and with bupivacaine-loaded microspheres in a sheep model. *Eur J Anaesthesiol.* 2003;20(4):305–10.
- Curley J, Castillo J, Hotz J, Uezono M, Hernandez S, Lim JO, et al. Prolonged regional nerve blockade. Injectable biodegradable bupivacaine/polyester microspheres. *Anesthesiology.* 1996;84(6):1401–10.
- Johansson A, Hao J, Sjölund B. Local corticosteroid application blocks transmission in normal nociceptive C-fibres. *Acta Anaesthesiol Scand.* 1990;34(5):335–8.
- Marks R, Barlow JW, Funder JW. Steroid-induced vasoconstriction: glucocorticoid antagonist studies. *J Clin Endocrinol Metab.* 1982;54(5):1075–7.
- Barnes PJ, Adcock I. Anti-inflammatory actions of steroids: molecular mechanisms. *Trends Pharmacol Sci.* 1993;14(12):436–41.
- Gupta B. Role of dexamethasone in peri-operative anesthesia management: A review of literature. *Anesthesiol OpenJ.* 2017;2(2):33–9.
- Yadav RK, Sah BP, Kumar P, Singh SN. Effectiveness of addition of neostigmine or dexamethasone to local anaesthetic in providing perioperative analgesia for brachial plexus block: A prospective, randomized, double blinded, controlled study. *Kathmandu Univ Med J (KUMJ).* 2008;6(23):302–9.
- Movafegh A, Razazian M, Hajimaohamadi F, Meysamie A. Dexamethasone added to lidocaine prolongs axillary brachial plexus blockade. *Anesth Analg.* 2006;102(1):263–7.
- Albrecht E, Kern C, Kirkham KR. A systematic review and meta-analysis of perineural dexamethasone for peripheral nerve blocks. *Anaesthesia.* 2015;70(1):71–83.
- Huynh TM, Marret E, Bonnet F. Combination of dexamethasone and local anaesthetic solution in peripheral nerve blocks: A meta-analysis of randomised controlled trials. *Eur J Anaesthesiol.* 2015;32(11):751–8.
- Mn FL, Kolesnikov S, Kruglov A, Nader ND. Adjuvant dexamethasone with bupivacaine prolongs the duration of interscalene block: a prospective randomized trial. *J Anesth.* 2011;25(5):704–9.

## Author biography

**Isha Parveen S**, Junior Resident

**Mili Rajappan**, Senior Consultant

**Cite this article:** Parveen S I, Rajappan M. Comparative study of bupivacaine-lignocaine to bupivacaine-lignocaine-dexamethasone in providing postoperative analgesia in interscalene block for shoulder arthroscopy. *Indian J Clin Anaesth* 2022;9(1):89-93.