



## Original Research Article

## Comparison of the efficacy of ultrasound guided adductor canal block versus intra-articular infiltration in providing post-operative analgesia after arthroscopic anterior cruciate ligament repair surgery

Kedar Bangal<sup>1,\*</sup>, Poonam Ghodki<sup>1</sup><sup>1</sup>Dept. of Anesthesia, Smt. Kashibai Navale Medical College, Pune, Maharashtra, India

## ARTICLE INFO

## Article history:

Received 10-05-2020

Accepted 06-07-2020

Available online 25-11-2020

## Keywords:

Adductor canal block

Intra-articular infiltration

Post-operative analgesia

## ABSTRACT

**Background and Aims:** Ultrasound guided adductor canal block (ACB) is a modality for providing analgesia after arthroscopic anterior cruciate ligament repair surgery. Intra-articular infiltration of analgesics in the knee joint acts on the free nerve endings at the operative site and provides analgesia. We aim to compare the analgesic efficacy and opioid consumption between these two modalities.

**Material and Methods:** Sixty patients were randomized to receive either ACB under ultrasound guidance (group A) or intra-articular infiltration (group B). Post-operatively time of rescue analgesia and opioid consumption were noted. Quality of analgesia was assessed every 2 hours until 6 hours, then every 6 hours until 24 hour post-operative period between the two groups. Data was analysed statistically and P value < 0.05 was considered significant.

**Results:** Time of rescue analgesia was comparable in both the groups (p value 0.4317). NRS scores in ACB group and intra-articular infiltration group were comparable till first 6 hours (p value 0.4519) but increased in intra-articular infiltration group at 12<sup>th</sup> hour (p value <0.0001) and 18<sup>th</sup> hour (p value <0.0117) as compared to group receiving ACB. The opioid consumption was more in intra-articular infiltration group than ACB group although not statistically significant (p value 0.6319).

**Conclusion:** ACB is a better modality for postoperative analgesia after arthroscopic anterior cruciate ligament repair surgery as analgesia of intra-articular infiltration wears off in 12-24 hour period which is crucial for early ambulation and from rehabilitation point of view.

© This is an open access article distributed under the terms of the Creative Commons Attribution License (<https://creativecommons.org/licenses/by/4.0/>) which permits unrestricted use, distribution, and reproduction in any medium, provided the original author and source are credited.

## 1. Introduction

Arthroscopic knee surgery is a commonly done procedure and is accompanied by postoperative pain which is the most important factor in preventing patient rehabilitation. Solheim et al., reported that around 60% of patients may experience moderate to severe pain after knee arthroscopic surgery, that delays rehabilitation and increases the risk of postoperative complications.<sup>1</sup> Therefore, adequate postoperative pain control is essential to improve postoperative recovery.

The success of arthroscopic anterior cruciate ligament (ACL) surgery depends upon post-operative rigorous rehabilitation. There is comparable pain between two methods of ACL repair – bone tendon patellar bone and semitendinosus-gracilis graft.<sup>2</sup>

Although arthroscopic procedures are minimally invasive surgeries, postoperative pain persists from graft implantation into the anterior cruciate ligament. Various analgesic modalities are used by systemic and non-systemic approaches such as local anesthetic infiltration, peripheral nerve block, intra-articular injection, and neuraxial blockade.<sup>3</sup>

Femoral nerve block is commonly used in patients undergoing knee surgery. However, femoral nerve block

\* Corresponding author.

E-mail address: [kedar4xcell@gmail.com](mailto:kedar4xcell@gmail.com) (K. Bangal).

causes weakness of quadriceps muscle, early ambulation is impaired and may increase the risk of falls.<sup>4,5</sup>

Adductor canal block (ACB), blocks the saphenous nerve which is a purely sensory nerve and the nerve to vastus medialis in the adductor canal, and with ultrasonography, drug spread around the femoral artery can be visualized on the ultrasound machine with increased success rate.<sup>4,6</sup>

Intra-articular infiltration studies have been done using local anaesthetics, alpha 2 agonists, non-steroidal anti-inflammatory drugs and magnesium with variable results.<sup>7–11</sup>

We decided to conduct the present study to compare the analgesic efficacy of ultrasound guided adductor canal block versus intra-articular infiltration after arthroscopic anterior cruciate ligament surgeries and also compare the opioid consumption.

## 2. Materials and Methods

The study was approved by the Institutional Ethical Committee. Patients belonging to ASA physical status I and II, age between 15 to 50 years, both genders, undergoing elective arthroscopic anterior cruciate ligament reconstruction surgeries under spinal anaesthesia were included in this study. Selected patients (N = 60) were randomly allocated in two groups (30 patients in each groups). Patients in Group A received Adductor canal block with 20 ml of 0.2% Ropivacaine post-operatively. Group B received intra-articular infiltration in the knee joint of 20 ml of 0.2% Ropivacaine post-operatively after surgical closure of the arthroscopic port sites. P value < 0.05 is considered to be significant.

In the preoperative assessment, the patients were enquired about any history of drug allergy, previous operations, or prolonged drug treatment. General examination, systemic examinations, and assessment of the airway were done. Preoperative fasting of minimum 6 hours was ensured before operation in all day care cases. All patients were clinically examined in the preoperative period, where whole procedure was explained and written consent was obtained. The numerical rating scale (NRS) (0, no pain and 10, worst pain imaginable) was explained to the patients.

The assessment was done in the post-operative care unit every 2 hourly till first 6 hours and then every 6 hourly till 24 hour post-operative period was completed. Whenever demanded, rescue analgesia was given in the form of intravenous tramadol 1mg/kg. The time of rescue analgesia, total analgesia consumption and NRS score in first 24 h was recorded.

### 2.1. Statistical analysis

Using power analysis, it was calculated that 28 patients would be required in each group considering alpha error

0.05 and beta error 0.2. To minimize the effect of dropouts from the study, we made two groups of 30 patients in each group. Patients were allocated by computer generated randomization. Parametric variables such as age, sex, and BMI were analyzed with Student's t-test. While for nonparametric data, Chi-square test was used. P < 0.05 was considered statistically significant and P < 0.001 as highly significant.

## 3. Results

All 60 patients completed the study. The patients were demographically comparable in both groups. The age group 15 to 50 years, both genders (male and female), body mass index falling in normal range and ASA 1 and 2 categories were included.

Table 1 shows distribution of patients with respect to age, male/female ratio, American society of Anaesthesiology (ASA) grading and body mass index is statistically not significant. The study subjects were chosen keeping the inclusion and exclusion criteria in mind.

Figure 1 shows that the NRS was comparable in two groups till 0-2 hours (p value 0.1725), 2-4 hours (p value 0.7023), 4-6 hour (p value 0.4519) and thereafter pain scores in group B rise and are significantly higher in the 12<sup>th</sup> hour (p value <0.0001) and 18<sup>th</sup> hour (p value <0.0117) than group A. Then the NRS scores in group B fall and become comparable with group A by the end of 24<sup>th</sup> hour (p value 0.4835).

Table 2 shows that the opioid consumption in the intra-articular infiltration group was more than adductor canal block group but it didn't prove to be statistically significant (p value 0.6319). The reason behind this is that the NRS score of intra-articular group despite being significantly more than the adductor canal block group during 12 to 24 hours, didn't reach to the extent of 6/10 on NRS scale which was the point where we had provided analgesics. This shows that the analgesia of intra-articular infiltration was suboptimal than adductor canal block group for most of the duration.

Table 3 shows that the period until the demand of rescue analgesia by the patient was comparable (p value 0.4317) in both groups A and B.

## 4. Discussion

We have conducted a comparison of the efficacy of postoperative analgesia and opioid consumption after ultrasound guided adductor canal block versus that after intra-articular infiltration with the same local anaesthetic, Inj. Ropivacaine 0.2% 20ml, used in both the modalities. It was found that both ultrasound guided adductor canal block and intra-articular infiltration groups had comparable NRS scores in the first 6 hours after which there was a rise in pain scores in intra-articular infiltration group till 12 hour

**Table 1:** Demographic profile

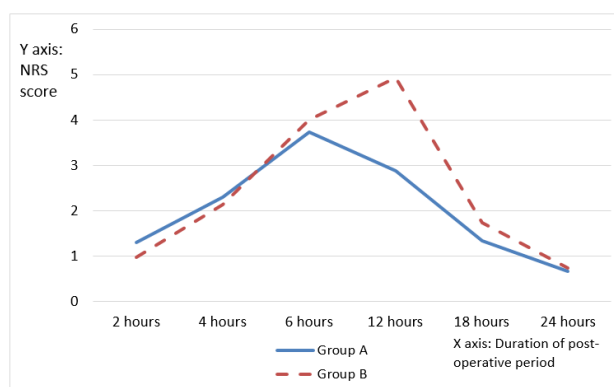
	Group A (n=30)	Group B (n=30)	P value (significant if, <0.05).
Age in years (mean)	30.83	30.63	0.9000
Sex(male/female)	21/9	22/8	1.0000
ASA I & II	25/5	24/6	0.7438
BMI (kg/m <sup>2</sup> )	31.17	32.73	0.3002

**Table 2:** Total analgesic consumption (tramadol in mg)

	Mean opioid consumed (in mg).		P value
	Group A	Group B	
In the 24 hour post-operative period	80.00	85.00	0.6319 (not significant)

**Table 3:** Mean duration of analgesia until rescue analgesic administration in two groups

	Group A	Group B	P value
Mean duration of analgesia (in hours)	9.1	8.57	0.4317 (not significant)

**Fig. 1:** Showing the graphical representation of the NRS scores in both the groups in the first 24 hour period

and continuing till 18 hour period post-operatively. Later on the pain scores were comparable in both groups till the end of 24 hours.

The anterior cruciate ligament guides rotation in the normal knee joint. Its injury hampers stability of the knee joint during rotational, accelerative and decelerative activities.

Arthroscopic knee surgery for anterior cruciate ligament repair involves the process of harvesting the semitendinosus-gracilis tendon graft for anterior cruciate ligament replacement and also bone tunneling for placement of the graft. Pain in the immediate post-operative period, becomes a barrier for starting an early rehabilitation programme after anterior cruciate ligament reconstruction surgery, which delays the recovery of quadriceps contractions and range of motion at the knee joint.<sup>2</sup>

Chisolm et al.<sup>12</sup> found that analgesia between adductor canal block was comparable to femoral nerve block but they didn't assess the quadriceps strength. In a study by

Faraj et al.<sup>13</sup> quadriceps strength was preserved with ACB and noninferior postoperative analgesia was provided for outpatients undergoing ACLR. P S Ghodki et al. found that adductor canal block provided comparable analgesia with femoral nerve block groups with motor sparing effect only in adductor canal block. There was persistent paralysis in femoral nerve block group which delayed the assessment of motor function during the postoperative period.<sup>3</sup>

The intra-articular region of the knee is a complex zone consisting of nerve endings having proprioceptive, mechanoreceptive and nociceptive conduction properties that can be blocked to reduce the level of pain after knee surgery. Free nerve endings are most numerous in the synovial coverings of the cruciate ligaments, patellar ligament, pes anserinus, the popliteal tendon and the medial and lateral retinaculum. The lowest amount was found in the anterior cruciate ligament and more in the bony insertions as compared with the ligament midsubstance.<sup>14–16</sup>

Origin of pain in the knee joint is an orchestration of activity of free nerve endings and certain cytokines.<sup>16</sup>

Our findings are similar to those of Anderson et al, who had demonstrated that local infiltration analgesia is effective for analgesia up to 6-12 hours postoperatively.<sup>17</sup>

W Kampitak et al., found that pain on movement was less in adductor canal block group compared to local infiltration analgesia group and the duration of effect of local infiltration analgesia may be shorter than adductor canal block.<sup>18</sup> The patients in our study had rising trend of NRS scores consistently in the intra-articular group in the 6 to 18 hour period. This may be because, the drug in intra-articular infiltration acts on the free nerve endings of all the regions of the articular surface of the knee where there may not be any nociceptive input, whereas the action on the anterior region of the articular surface is important in anterior cruciate ligament repair surgery from analgesic point of view.

Ultrasound guided adductor canal block provided superior analgesia throughout the 24 hour period which is very crucial for early ambulation and from rehabilitative point of view. However, while adductor canal block requires skill and expertise, the intra-articular infiltration can be performed by surgeon himself after closing the skin sutures.

There are certain limitations to our study. We did not add any adjuvant to local anesthetics in either groups; that probably would have overcome the suboptimal analgesia of intra-articular infiltration. However adjuvants come with their own complications and studying them was not the aim of our study.

Hence, we conclude that the ultrasound guided adductor canal block is superior to the intra-articular infiltration in terms of providing analgesia for arthroscopic ACL repair especially in the period when ambulation is attempted postoperatively aiding better rehabilitation.

## 5. Source of Funding

None.

## 6. Conflict of Interest

The author(s) declare(s) that there is no conflict of interest.

## References

1. Solheim N, Rosslund LA, Stubhaug A. Intra-articular morphine 5 mg after knee arthroscopy does not produce significant pain relief when administered to patients with moderate to severe pain via an intra-articular catheter. *Regional anaesthesia and pain medicine. Regional Anesth Pain Med.* 2006;31(6):506–13.
2. Gupta R, Kapoor D, Kapoor L, Malhotra A, Masih GD, Kapoor A, et al. Immediate post-operative pain in anterior cruciate ligament reconstruction surgery with bone patellar tendon bone graft versus hamstring graft. *J Orthop Surg Res.* 2016;11(1):67–72. doi:10.1186/s13018-016-0399-5.
3. Ghodki PS, Shalu PS, Sardesai SP. Ultrasound-guided adductor canal block versus femoral nerve block for arthroscopic anterior cruciate ligament repair under general anesthesia. *J Anaesthesiol Clin Pharmacol.* 2018;34(2):242–6.

4. Ilfeld BM, Duke KB, Donohue MC. The Association Between Lower Extremity Continuous Peripheral Nerve Blocks and Patient Falls After Knee and Hip Arthroplasty. *Anesth Analg.* 2010;111(6):1552–4. doi:10.1213/ane.0b013e3181fb9507.
5. Kandasami M, Kinninmonth AWG, Sarungi M, Baines J, Scott NB. Femoral nerve block for total knee replacement — A word of caution. *Knee.* 2009;16(2):98–100. doi:10.1016/j.knee.2008.10.007.
6. Manickam B, Perlas A, Duggan E, Brull R, Chan VWS, Ramlogan R. Feasibility and Efficacy of Ultrasound-Guided Block of the Saphenous Nerve in the Adductor Canal. *Reg Anesth and Pain Med.* 2009;34(6):578–80. doi:10.1097/aap.0b013e3181fbf84.
7. Goodwin RC, Amjadi F, Parker RD. Short-term analgesic effects of intra-articular injections after knee arthroscopy. *Arthrosc: J Arthrosc Relat Surg.* 2005;21(3):307–12. doi:10.1016/j.arthro.2004.11.015.
8. Cook TM, Tuckey JP, Nolan JP. Analgesia after day-case knee arthroscopy: double-blind study of intra-articular tenoxicam, intra-articular bupivacaine and placebo. *Br J Anaesth.* 1997;78(2):163. doi:10.1093/bja/78.2.163.
9. Buerkle H, Hüge V, Wolfgart M, Steinbeck J. Intra-articular clonidine analgesia after knee arthroscopy. *Eur J Anaesthesiol.* 2000;17(5):295–9.
10. Paul S, Bhattacharjee DP, Ghosh S, Dawn S, Chatterjee N. Efficacy of intra-articular dexmedetomidine for postoperative analgesia in arthroscopic knee surgery. *Ceylon Med J.* 2010;55(4):111–5. doi:10.4038/cmj.v55i4.2627.
11. Bondok RS, M A. Abd El-Hady. Intra-articular magnesium is effective for postoperative analgesia in arthroscopic knee surgery. *Br J Anaesth.* 2006;97(3):389–92.
12. Chisholm MF, Bang H, Maalouf DB, Lotano MD, Marx MA, Liguori RG, et al. Post operative Analgesia with saphenous nerve block appears equivalent to femoral nerve block in ACLR. *HSS J.* 2014;10(3):245–51.
13. Abdallah F, Whelan DB, Chan VW, Prasad GA, Endersby RV, Theodoropolous J, et al. Adductor canal block provides non inferior analgesia and superior quadriceps muscle strength compared with femoral nerve block in ACLR. *Anesthesiol.* 2016;124(5):1053–64.
14. Biedert RM, Stauffer E, Friederich NF. Occurrence of free nerve endings in the soft tissue of the knee joint. *Am J Sports Med.* 1992;20(4):430–3. doi:10.1177/036354659202000411.
15. Meyer DC, Aguirre JA, Wieser K, Fucentese SF, Wirth S, Gerber C, et al. Intra-osseous local anaesthetic patellar pain catheter suppresses osteoarthritic patello-femoral pain. *Knee.* 2017;24(4):882–9. doi:10.1016/j.knee.2017.04.010.
16. McCarthy MM, Strickland SM. Patellofemoral pain: an update on diagnostic and treatment options. *Curr Rev Musculoskelet Med.* 2013;6(2):188–94. doi:10.1007/s12178-013-9159-x.
17. Andersen LØ, Kehlet H. Analgesic efficacy of local infiltration analgesia in hip and knee arthroplasty: a systematic review. *Br J Anaesth.* 2014;113(3):360–74. doi:10.1093/bja/aeu155.
18. Kampitak W, Tanavalee A, Ngarmukos S, Amarase C, Songthamwat B, Boonshua A, et al. Comparison of Adductor Canal Block Versus Local Infiltration Analgesia on Postoperative Pain and Functional Outcome after Total Knee Arthroplasty: A Randomized Controlled Trial. *Malays Orthop J.* 2018;12(1):7–14.

## Author biography

**Kedar Banal**, Junior Resident

**Poonam Ghodki**, Professor

**Cite this article:** Banal K, Ghodki P. Comparison of the efficacy of ultrasound guided adductor canal block versus intra-articular infiltration in providing post-operative analgesia after arthroscopic anterior cruciate ligament repair surgery. *Indian J Clin Anaesth* 2020;7(4):579-582.