



Case Report

Total intravenous anaesthesia to facilitate bulbocavernous reflex in a 2-year-old child with tethered cord syndrome: A case report

Kavya Mittimanji¹, Deepak Rajappa^{1,*}, Dheeraj Masapu¹, Shishir Chandrashekar¹, Satish Rudrappa²

¹Dept. of Anaesthesia, Sakra World Hospital, Bengaluru, Karnataka, India

²Institute of Neurosciences, Sakra World Hospital, Bengaluru, Karnataka, India



ARTICLE INFO

Article history:

Received 09-06-2020

Accepted 25-07-2020

Available online 15-03-2021

Keywords:

Total intravenous anaesthesia

Paediatric anaesthesia

Paediatric total intravenous

anaesthesia

Tethered cord syndrome

Bulbocavernous reflex

ABSTRACT

Tethered cord syndrome is a neurological disorder caused by tissue attachments that limit the movement of the spinal cord within the spinal canal. Intraoperative neurophysiological monitoring like somatosensory evoked potentials and transcranial motor evoked potentials can preclude surgically induced lesions to the nervous system and has become standard of care for many neurosurgical procedures. Despite the potential advantages of total intravenous anaesthesia, it is not a widely used anaesthetic technique in children. Recently, a few case reports have been published regarding the presence of metabolic acidosis even with a short term infusion of propofol. We present a case report in which total intravenous anaesthesia was used to facilitate BCR in a 2-year-old child, to monitor the functional integrity of the sacral reflex, which enables bladder and bowel function.

© This is an open access article distributed under the terms of the Creative Commons Attribution License (<https://creativecommons.org/licenses/by/4.0/>) which permits unrestricted use, distribution, and reproduction in any medium, provided the original author and source are credited.

1. Introduction

Tethered cord syndrome (TCS) is a neurological disorder caused by tissue attachments that limit the movement of the spinal cord within the spinal canal. The common causes of tethered cord syndrome are closed spinal dysraphisms like spinal lipomas, arachnoid adhesions due to trauma/surgery, dermal sinus tract, and dermoid/epidermoid tumors.¹ Untreated tethered cord can lead to paraplegia and loss of bowel and bladder function particularly in children due to lengthening of the spine. The inappropriate surgical technique can damage the neuronal structures and cause new neurological deficits or exacerbate pre-existing dysfunction. Surgery-related deterioration has been observed in approximately 8% of cases.² Intraoperative neurophysiological Monitoring (IONM) like somatosensory evoked potentials (SSEPs) and transcranial motor evoked potentials (tcMEPs) can preclude surgically induced lesions to the nervous system and has become standard of

care for many neurosurgical procedures.² Bulb cavernous reflex (BCR) being the new entity, monitoring both the afferent and efferent pathway of the anal sphincters and bladder control.³ It's known that inhalational anaesthetics decrease the amplitude and increase the latency of the evoked potentials. Total intravenous anaesthesia (TIVA) with propofol and opioids is preferred in adults while IONM is being monitored.⁴ Although the advantages might exceed in adult it's not being used in paediatric patients for the fear of propofol infusion syndrome.⁵ We present a case report in which total intravenous anaesthesia was used to facilitate BCR in a 2-year-old child, to monitor the functional integrity of the sacral reflex, which enables bladder and bowel function.

2. Case History

Our case is a 2-year-old female child, weighing 12 kgs and 88 cms of height. The child presented with complaints of bowel and bladder incontinence without any other neurological deficits. MRI showed spinal dysraphism with

* Corresponding author.

E-mail address: drdeepak.r4@gmail.com (D. Rajappa).

defects in posterior elements at the L4 level and herniation of the spinal cord at the same level. Lipomatous tissue was noted in the spinal defect attached to the neural placode. The diagnosis of lipomeningomyelocele with tethered cord syndrome was made. The child was subsequently posted to undergo spinal cord detethering under general anaesthesia with IONM.

The pre-operative assessment revealed an otherwise healthy child with no known comorbidities. Pre-operative physical examination was normal. On arrival to the operating room, monitors, including ECG, pulse oximetry, and non-invasive blood pressure were attached. Baseline oxygen saturation was 99%, non-invasive blood pressure (NIBP) was 95/57 mmHg and heart rate was 112 beats/min. Inhalational induction was achieved by preserving spontaneous ventilation with an incremental concentration of sevoflurane (2–8%) in a mixture of O₂: N₂O (50:50). Once anesthetized, a 22 G cannula was inserted and fentanyl (2 µg/kg), propofol (2 mg/kg) were given. Atracurium (0.5 mg/kg) was used to facilitate intubation. The patient was intubated with 4 size cuffed, wire-reinforced endotracheal tube. Further doses of muscle relaxants were avoided for IONM. The patient was mechanically ventilated in the pressure control mode, and the end-tidal carbon dioxide levels were monitored and maintained at the range of 30–35 mmHg. For IONM the corkscrew electrodes were placed C1-C2 and C3-C4 for tcMEPs; Cz and Fpz for lower limb SSEPs. All myotomes were monitored from L1 to S4. Sacral nerves were monitored with anal sphincter muscles. The myotomes were monitored with both spontaneous MEP and triggered electromyogram (EMG). For BCR the stimulating electrodes were placed near the clitoris and labia major after taking consent from the parents. An oropharyngeal temperature probe was used to monitor the intraoperative temperature. The patient was positioned prone and pressure points were well padded. After positioning, anaesthesia was maintained with sevoflurane was continued maintaining a minimum alveolar concentration (MAC) of 0.9. Analgesia was maintained with fentanyl infusion at 0.5 µg/kg/hr.

The compound myogenic responses were elicited with 450V double train pulses delivered for a brief period (75 µs), with 2 ms interstimulus interval. SSEP was obtained with a 200-µsec square-wave electrical pulse stimulating the posterior tibial and median nerves at a rate of 4 Hz, with a stimulation intensity of 40 mA. For BCR, a single train consisting of four stimulation pulses with duration of 0.4 ms was delivered with an interstimulus interval of 2 ms (500 Hz). Both tcMEPs and SSEPs were obtained with sevoflurane but BCR was not obtained. So, Sevoflurane was discontinued and propofol infusion commenced at 12mg/kg over the first 10 mins and 9mg/kg over the next 10 mins and 6mg/kg thereafter. 20 mins after stopping sevoflurane BCR was attained bilaterally with the same stimulus as shown in Figure 1. Measures were taken to maintain euolemia

and normothermia. The surgery lasted for 160 mins and the intraoperative period was uneventful. Arterial blood gas analysis was done towards the end of surgery and didn't reveal any acidosis or electrolyte abnormality. Propofol and fentanyl were switched off in time and the child was extubated in the supine position and after thorough suctioning. The patient was shifted to the recovery room for observation. Postoperative motor recovery was good and satisfactory.

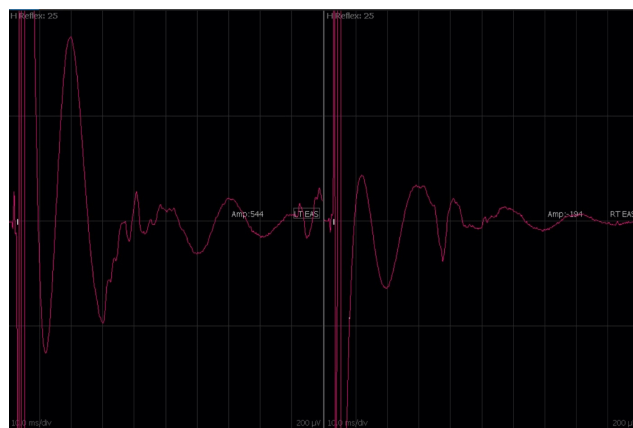


Fig. 1: Bulbocavernosus reflex attained during total intravenous anaesthesia

3. Discussion

Lipomeningocele is a type of spinal dysraphism caused by incomplete fusion or lack of fusion of midline structures during the fourth week of embryogenesis. The incidence of these defects shows a significant geographical variation of 0.5 to 5 per 1,000 births.⁶ Spinal lipomas present with cutaneous and musculoskeletal abnormalities in addition to sensorimotor deficits and urological dysfunction. Cutaneous lesions include subcutaneous lipomas, capillary hemangiomas, complex dimples, and hypertrichosis.⁷ Diagnosis is done by prenatal ultrasonography and magnetic resonance imaging.⁷

Despite the potential advantages of TIVA, it is not a widely used anaesthetic technique in children.⁵ Recently, a few case reports have been published regarding the presence of metabolic acidosis even with a short term infusion of propofol.⁹ This being the concern the popularity among the paediatric anaesthetists is low. TIVA can be administered either using manual dosing, where the anaesthetist determines the bolus dose and infusion rate or using a target-controlled infusion (TCI) pump where the anaesthetist enters the desired 'target' concentration to be achieved in the patient's plasma or brain. Numerous paediatric TCI models have been developed but two models widely used are Paedfusor and Kataria. Paedfusor uses age and weight as covariates; it can be used between 5 and 61 kg,

Table 1: Steur's recommendation for propofol infusion dosing in patients less than 3 years.⁸

Time	Infusion rates (mg/kg/hr)			
	<3 months*	3 – 6 months*	6 – 12 months*	1 – 3 years*
0 – 10 Mins	25	20	15	12
10 – 20 Mins	20	15	10	9
20 – 30 Mins	15	10	5	6
30 – 40 Mins	10	5	5	6
40 – 100 Mins	5	5	5	6
Remaining time	2.5	2.5	2.5	6

and 1–16 yr of age. Kataria is used from 3 to 16 yr of age and works with a minimum weight of 15 kg.¹⁰ In a developing country like India, the availability of paediatric TCI pumps becomes a difficulty. So, we decided to conduct TIVA using manual propofol infusion in patients under 3 years of age, as recommended by Steur et al.⁸ (Table 1)

Propofol dose required to produce loss of consciousness and to obtund movement and hemodynamic responses to noxious stimuli are reduced by co-administration of drugs like opioids, benzodiazepines, ketamine, $\alpha 2$ -adrenoceptor agonists, and magnesium. TIVA when used in children demands a thorough understanding of the pharmacokinetic and pharmacodynamics differences of propofol in children. Anaesthesiologists should ensure that intravenous cannula is functioning with tight connections and infusion sites are visible at all the time so that they may be monitored regularly for leakage, disconnection, or extravasation. Infusion line dead-space should be especially minimized in children.¹⁰ TIVA used in our patient facilitated in attaining BCR which was inhibited by an inhalational agent. Further, the propofol infusion being used for such long hours didn't cause and metabolic acidosis which was feared in paediatric patients.⁹

To conclude, lipomyelomeningocele is a type of spinal dysraphism that may present with neurological deterioration secondary to an inherent tethered spinal cord. Tethered spinal cord surgery with intraoperative neurophysiology monitoring facilitates the identification of neural structures and continuous monitoring of their functional integrity. In this case report, we demonstrated that TIVA is a safe, feasible, and reliable alternative to inhalational anaesthesia in the paediatric population to facilitate the neuromonitoring.

4. Source of Funding

None.

5. Conflict of Interest

The authors declare that there is no conflict of interest.

References

1. Agarwalla PK, Dunn IF, Scott RM, Smith ER. Tethered Cord Syndrome. *Neurosurg Clin North Am.* 2007;18(3):531–47. doi:10.1016/j.nec.2007.04.001.
2. van Leeuwen R, Notermans NC, Vandertop WP. Surgery in adults with tethered cord syndrome: outcome study with independent clinical review. *J Neurosurg.* 2001;94(2):205–9. doi:10.3171/spi.2001.94.2.0205.
3. Shinjo T, Hayashi H, Takatani T, Boku E, Nakase H, Kawaguchi M. Intraoperative feasibility of bulbocavernosus reflex monitoring during untethering surgery in infants and children. *J Clin Monitoring Comput.* 2019;33(1):155–63. doi:10.1007/s10877-018-0127-2.
4. Deiner S. Highlights of Anesthetic Considerations for Intraoperative Neuromonitoring. *Semin Cardiothorac Vasc Anesth.* 2010;14(1):51–3. doi:10.1177/1089253210362792.
5. Hill M, Peat W, Courtman S. A national survey of propofol infusion use by paediatric anaesthetists in Great Britain and Ireland. *Pediatr Anesth.* 2008;18(6):488–93. doi:10.1111/j.1460-9592.2008.02459.x.
6. Holmes LC, Li V. Occult Spinal Dysraphism. *Pediatr Rev.* 2019;40(12):650–2. doi:10.1542/pir.2018-0155.
7. Ausili E, Maresca G, Massimi L, Morgante L, Romagnoli C, Rendeli C. Occult spinal dysraphisms in newborns with skin markers: role of ultrasonography and magnetic resonance imaging. *Child's Nerv Syst.* 2018;34(2):285–91. doi:10.1007/s00381-017-3638-0.
8. Steur RJ, Perez R, Lange JD. Dosage scheme for propofol in children under 3 years of age. *Pediatr Anesth.* 2004;14(6):462–7. doi:10.1111/j.1460-9592.2004.01238.x.
9. Wolf AR, Potter F. Propofol infusion in children: when does an anesthetic tool become an intensive care liability? *Pediatr Anesth.* 2004;14(6):435–8. doi:10.1111/j.1460-9592.2004.01332.x.
10. Anderson BJ, Bagshaw O. Practicalities of Total Intravenous Anesthesia and Target-controlled Infusion in Children. *Anesthesiol.* 2019;131(1):164–85. doi:10.1097/aln.0000000000002657.

Author biography

Kavya Mittimanj, Senior Resident

Deepak Rajappa, Associate Consultant

Dheeraj Masapu, Consultant

Shishir Chandrashekar, Senior Consultant and Head

Cite this article: Mittimanj K, Rajappa D, Masapu D, Chandrashekar S, Rudrappa S. Total intravenous anaesthesia to facilitate bulbocavernosus reflex in a 2-year-old child with tethered cord syndrome: A case report. *Indian J Clin Anaesth* 2021;8(1):122–124.